

# Intra-Aortic Balloon Counterpulsation in The Treatment of Refractory Intra-Operative Cardiogenic Shock

Leland B. Housman, M.D.\* , Carolyn Casey, R.N., Dianne Speros, R.N., Ingrid Hansen, P.A., Betty Stephens, P.A., and Jeri L. Dobbs, P.A.

\*From the Division of Cardiopulmonary Surgery, University of Oregon Medical School  
3181 S. W. Sam Jackson Park Road, Portland, Oregon 97201

## INTRODUCTION

Cardiogenic shock remains one of the most challenging and difficult problems confronting clinicians today. Intra-aortic balloon counterpulsation (IABC) has been used successfully in the treatment of cardiogenic shock in both the experimental and clinical settings, and is currently an established therapeutic modality.<sup>1,2,3</sup> It is generally agreed that IABC should be reserved for use in cases of refractory cardiogenic shock (blood pressure < 80mmHg despite treatment with all available pressors).<sup>4</sup> This report describes our experience with a group of patients in whom refractory intra-operative cardiogenic shock developed and who were unable to be weaned from cardiopulmonary bypass without the use of IABC. Circulatory assist in the form of balloon counterpulsation in this group of patients is quite successful in reversing the shock state and long term survival is achievable in a high percentage of cases.

## MATERIALS AND METHODS

Nine patients undergoing various cardiac surgical procedures developed refractory intra-operative cardiogenic shock (two valve replacements, four coronary artery bypass grafts and three combination valve and vein graft patients). The shock state persisted despite treatment with pressor agents (isoproterenol, epinephrine, norepinephrine, glucagon, dopamine) and cardiopulmonary bypass could not be successfully terminated. Intra-aortic balloon counterpulsation was begun following positioning of the balloon catheter in the descending thoracic aorta, as has been previously described.<sup>5</sup> Following institution of IABC, the shock state was reversed (blood pressure > 100mmHg, increased urine output, decreased left atrial pressure). Recurrent episodes of ventricular tachycardia and ventricular fibrillation encountered in three patients likewise responded to IABC. All patients were able to be weaned from bypass and were returned to the cardiac recovery room with circulatory assistance (IABC).

## RESULTS

IABC successfully reversed the shock state in all patients. Blood pressure rose to over 100mmHg, urine output increased to > 50cc/hour, left atrial pressures fell from over 25mmHg to 10-15mmHg and all nine patients were able to be weaned from cardiopulmonary bypass. IABC was continued for periods of four to nine days before being discontinued in the cardiac recovery room. The balloon catheters were removed with the use of local anesthesia in the conscious patients. All patients were able to be weaned from IABC and eight of nine patients left the hospital.

## DISCUSSION

Cardiogenic shock is a self perpetuating vicious cycle initiated by an insult, usually ischemic, to the heart itself. The profound pump failure that follows leads to a decrease in blood pressure, which in turn leads to a decrease in coronary artery blood flow. This decrease in coronary blood flow results in further myocardial damage and hence, more profound pump failure, thus setting up a continuous cycle. Utilizing the principles of diastolic augmentation, IABC interrupts this cycle and reverses the shock state.

The intra-aortic balloon pump inflates during diastole and deflates during systole. Since coronary blood flow occurs during diastole, there is a rise in coronary artery blood flow during IABC. Not only is the diastolic blood pressure elevated, but systolic blood pressure reduces the after load that the left ventricle has to contract against. This results in the heart having to perform less work and hence, myocardial oxygen demand and utilization is decreased.<sup>6</sup> Therefore, more oxygen is being delivered to the heart at a time when it is having to work less. This set of circumstances allows the heart to "rest"

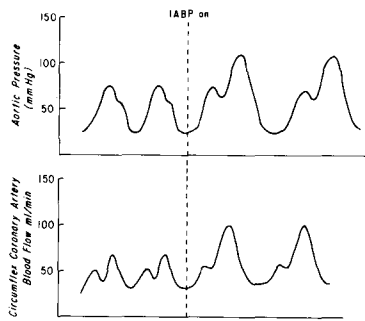


Fig. 1. Top Panel: Lowering of systolic and elevation of diastolic blood pressures during IABC resulting in decreased afterload on the left ventricle and increased coronary artery perfusion.

Lower Panel: Increase in coronary artery blood flow after the institution of IABC.

and recover from the ischemic insult it has sustained.

While the overall survival of patients with refractory cardiogenic shock following myocardial infarction remains quite low despite the use of IABC, the subgroup of patients that develop this condition intra-operatively have excellent long term survival.<sup>3,5</sup> The reason for the difference in survival figures in these two groups (9% and 88% respectively) may be a reflection of the fact that the latter group of patients sustain a temporary ischemic episode that is reversible if the heart is allowed to recover at a reduced work-load. The patient who is seen in the coronary care unit with refractory cardiogenic shock has usually sustained a massive myocardial infarction and the heart is unable to overcome this extensive injury despite all forms of therapy, including IABC. On the other hand, the patient undergoing open heart surgery has usually sustained an episode of temporary ischemia (i.e., inadequate coronary perfusion during aortic cross clamping). This insult is often reversible and usually does not result in massive infarction. Additionally, however, if there has been myocardial infarction, IABC can both reduce the size and prevent the extension of such an infarction.<sup>9</sup>

The ability of IABC to dramatically reverse the shock state in this group of patients, coupled with the high percentage of long term survivors, makes the use of IABC a useful therapeutic instrument for the treatment of refractory intra-operative cardiogenic shock.

#### SUMMARY

IABC decreases afterload and increases coronary artery perfusion utilizing the principles of diastolic augmentation. This allows the heart to recover from ischemic insults in a setting of decreased cardiac work-load and increased myocardial oxygen delivery. Nine patients in whom refractory cardiogenic shock developed intra-operatively are presented. After the institution of IABC, all were able to be weaned from cardiopulmonary bypass successfully. None became balloon dependent and eight of nine left the hospital. IABC represents a useful therapeutic modality for the treatment of refractory intra-operative cardiogenic shock.

#### BIBLIOGRAPHY

1. Soroff, H. S., et al.: Experimental and Clinical Studies in Assisted Circulation. *Transplantation Proceedings* 3:1483, 1971.
2. Buckley, M. J., et al.: Hemodynamic Evaluation of Intra-Aortic Balloon Pumping in Man. *Circ.* 41 (Suppl. 11):11, 1970.
3. Housman, L. B., et al.: Successful Use of Intra-Aortic Balloon Counterpulsation in the Treatment of Refractory Intra-Operative Cardiogenic Shock. *American Surgeon* (in press) 1974.
4. Scheidt, S., et al.: Intra-Aortic Balloon Counterpulsation in Cardiogenic Shock. *New Eng. J. Med.* 288:979, 1973.
5. Housman, L. B., et al.: Counterpulsation for Intra-Operative Cardiogenic Shock. Successful Use of Intra-Aortic Balloon. *J.A.M.A.* 224:1131, 1973.
6. Moroko, P. R., et al.: Effects of Intra-Aortic Balloon Counterpulsation on The Severity of Myocardial Ischemic Injury Following Acute Coronary Occlusion: Counterpulsation and Myocardial Injury. *Circ.* 45:1150, 1972.