

Extracorporeal Membrane Oxygenation (ECMO) Cardiopulmonary Support in Infancy

Robert H. Bartlett, Alan B. Gazzaniga, M. Robin Jefferies, Robert F. Huxtable,
Nick J. Haiduc, and Susie W. Fong

From the Departments of Surgery and Pediatrics
University of California—Irvine
Irvine, California 92717

Prolonged extracorporeal venoarterial bypass with a membrane oxygenator (ECMO) will sustain life for days or weeks in patients with acute cardiac or pulmonary failure. The technique has been studied primarily in adults with acute pulmonary insufficiency. In that group of moribund patients the survival rate is 10–15%. Several conditions of the newborn and infant might benefit from temporary cardiopulmonary support, but the problems of cannulation, coagulation, and scaling down equipment have led most investigators to focus on adults. Although the authors¹ and Soeter² have reported successful ECMO support in infants, newborn perfusion survival has not been reported. The authors have been studying ECMO in the laboratory for several years, and applied this technique to 27 patients. Thirteen of these cases were critically ill infants, four of which survived. This report describes that experience.

PATIENTS AND METHODS

The patients included four infants from six months to two years of age. Two were treated for postoperative cardiac failure, one for staphylococcal pneumonitis, and one for drowning. Nine were treated for severe respiratory insufficiency in the newborn period due to meconium aspiration,⁴ idiopathic respiratory distress syndrome (IRDS),⁴ and persistent fetal circulation.¹ These cases represent the authors' total experience with ECMO in infancy during a four year period from 1972 through March, 1976.

Since ECMO has major potential inherent risks, these clinical trials were conducted only in moribund patients who appeared to have no chance of survival with continued maximal conventional therapy. In fact, ECMO was instituted in two children during cardiopulmonary resuscitation. The clinical conditions which defined moribund status in this series were: (1) Postoperative low cardiac output syndrome with sustained hypotension, metabolic acidosis, and renal failure, after maximal volume replacement and pharmacologic support. (2) Pulmonary insufficiency with sustained hypoxemia despite maximal mechanical ventilation, positive end expiratory pressure, and FiO_2 1.0. The pulmonary insufficiency index (PII) developed for mortality prediction in adult pulmonary insufficiency seems to be applicable to infants as well. PII in these two infants was 10 and 9.5. (3) Massive meconium aspiration requiring intubation, mechanical ventilation, FiO_2 1.0 complicated by bradycardic episodes and pneumothorax and persistent acidosis, despite early lavage and maximum management. (4) IRDS requiring

Supported by grants from the California Lung Association, Orange County Heart Association, David E. Baxter Foundation, and The National Heart and Lung Institute.

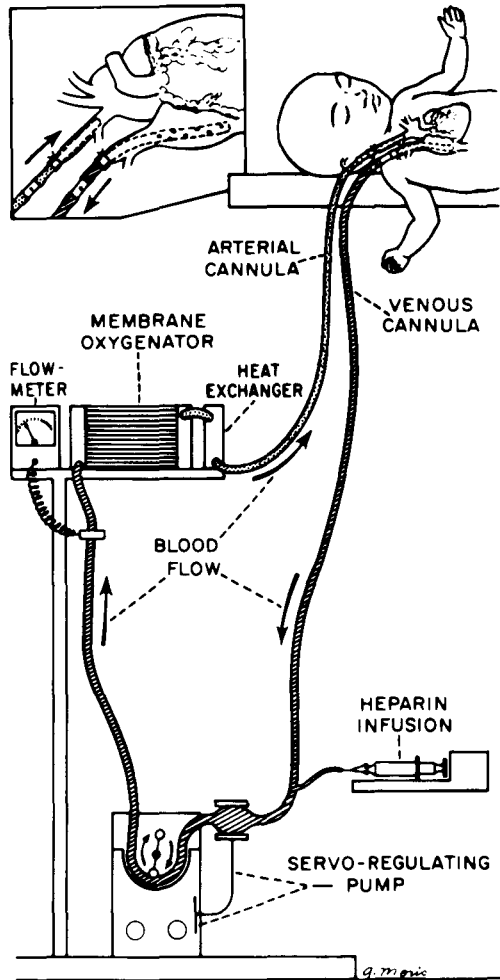


Figure 1. Diagram of ECMO circuit used for infants

intubation, mechanical ventilation, positive end expiratory pressure and FiO_2 1.0 (after failure to continuous positive airway pressure breathing and intermittent mandatory ventilation), with persistent acidosis, high ventilator pressures, interstitial emphysema, pneumothorax, major airleaks precluding adequate ventilation, and bradycardia and/or cardiac arrest. (5) Persistent fetal circulation syndrome with hypoxemia and respiratory acidosis despite intubation, mechanical ventilation, and FiO_2 1.0, with right-to-left shunting despite maximal ventilator and pharmacologic therapy.

ECMO was considered in moribund infants who did not have other major congenital anomalies, evidence of neurologic damage, or abnormal bleeding. If the child met these criteria the possibility of ECMO was discussed in detail with the family and considered only after informed parental consent. This protocol was approved by the human subjects research committee of UCI.

CANNULATION, CIRCUIT, AND ECMO MANAGEMENT

The techniques of ECMO management in the infant were developed in the laboratory using the lamb as an experimental model. Those experiments are described in detail elsewhere.^{3,4} Venoarterial bypass was used in all cases. A single right atrial catheter via the right internal jugular vein was used with arterial return to the right axillary artery in two cases and the right carotid artery in eleven. Blood flow is limited by the size of the venous catheter and the syphon drainage from the patient to the floor. The circuit was designed to deliver a flow rate of at least 80% of the cardiac output with the capability of going to total bypass (120 cc/kg/min). Venous blood was drained through a small sensing bladder to a servo-regulated roller pump. Blood was perfused through a Landé-Edwards membrane oxygenator on the arterial side of the circuit, through a disposable Travenol heat exchanger which also served as a bubble trap, and to the arterial catheter. Arterial line pressure is limited by the diameter and length of the arterial cannula. The largest possible catheter was inserted into the artery, usually resulting in a line pressure of 250–300 mmHg. Gas exchange capability is determined by the membrane oxygenator. The circuit was designed to be capable of total gas exchange support (6 cc O₂ and CO₂/kg/min). The Landé-Edwards membrane oxygenator has an O₂ transfer capability of approximately 33 cc/M²/min. The one M² unit was used for newborn patients and the three M² unit for older infants. CO₂ elimination exceeds oxygen transport in this device, so that carbogen (95% O₂, 5% CO₂) was usually required to maintain arterial pCO₂ around 40 mmHg. The oxygenator was ventilated with carbogen at high gas flow rates (10–15 L/min) and intermittently “sighed” with higher gas flows. This prevents water accumulation in the gas phase and deterioration of oxygenator function. Polyvinyl chloride (Tygon™) tubing and polycarbonate connectors completed the circuit. Three-sixteenths or one-quarter inch internal diameter tubing was used for newborn infants, three-eighths inch tubing for older infants.

Priming the circuit is an important step in infant ECMO, as the extracorporeal blood volume may be two to four times the blood volume of the infant. The entire circuit was primed and rinsed with crystalloid solution (necessary because of manufacturing techniques in the Landé-Edwards membrane oxygenator). Twenty-five grams of human serum albumin was added to the last rinse to coat the surface and minimize subsequent fibrinogen and platelet adherence.⁵ The circuit was then primed with the freshest blood available which was recirculated while ventilating the oxygenator with carbogen. The hematocrit, acid base balance, and electrolyte composition of the prime was measured and adjusted until it was as normal as possible. Blood sugar and citrate concentration were very high when ACD blood was used. Heparin and calcium were added to the prime before ECMO was begun. The use of freshly drawn heparinized blood for priming would be desirable for infant ECMO. The prime blood and all subsequent transfused blood was filtered through 40 micron filters to remove aggregates. The perfusion line itself was not filtered.

All patients were monitored with a systemic catheter in the left radial, umbilical, or femoral artery. Pulmonary artery catheters could be placed in only two patients, one of these midway through the course of ECMO.

Venoarterial bypass was maintained at 80–100 cc/kg/min which is adequate for total gas exchange. Mean arterial blood pressure was maintained normal by the infusion of blood or colloid solution. The arterial pulse contour remained pulsatile with a 10–20 mmHg pulse pressure at this flow rate which represents approximately 80% of the cardiac

output. Pulmonary artery pressure was usually not pulsatile at this flow rate. In newborn infants the ECMO flow was regulated to maintain the arterial pO₂ between 50 and 70 mmHg. High arterial pO₂, even for short intervals, may lead to retrolental fibroplasia in the preterm infant. The progress of the primary cardiac or pulmonary disease was evaluated by clamping the venous and arterial lines, and coming off bypass for several minutes daily. Blood gas and pressure measurements were made during this test period which are recorded as "off ECMO" testing.

Heparin, 100 μ/kg, was given before cannulation and heparin was continuously infused to maintain the activated whole blood clotting time⁶ between two and three times baseline.⁷ In general this required 20–40 μ of heparin/kg/hr. Coagulation and platelet status were measured at frequent intervals. Platelet transfusion was given for excessive bleeding, prior to surgical procedures, or for platelet count less than 20,000. Fibrinogen and coagulation factors usually remained normal during ECMO, but fresh frozen plasma was often required in the neonate to maintain normal coagulation screening tests and coagulation factors.

Dextrose and water was infused to supply the normal daily water requirement plus replace the water loss through the membrane oxygenator (7 cc/M²/hr). The latter is a particularly important consideration in small patients. Severe desiccation dehydration can occur if oxygenator water loss is not replaced. Urine output was monitored hourly. Lasix was given if oliguria occurred. Renal failure occurred before or during ECMO in four patients. This was treated with peritoneal dialysis in Case 1 (postoperative mustard) and hemodialysis in Cases 2 (postoperative mustard) and 7 (meconium aspiration).

Attempts at gastric feeding were usually complicated by moderate ileus. Nutrition was maintained with infusion of hypertonic glucose and amino acid solutions given into the ECMO circuit. Positive caloric balance was maintained. Weight was measured daily but this was difficult to interpret because of the variables due to tubes, drains, dressings, etc.

Because of the invasive nature of ECMO, septicemia is a major potential problem. Potent broad spectrum antibiotics were given. The cannulation sites were cleaned and dressed with Betadine daily. All stopcocks and other vascular access sites were thoroughly cleaned with alcohol after each use. Neurologic functions was monitored by direct observation with minimal sedation. Electroencephalograms were done if there were signs of neurological abnormality.

In all cases the patient was cared for by neonatal and pediatric intensive care nurses and the ECMO circuit was continuously monitored and managed by technical specialists trained specifically for prolonged membrane oxygenator perfusion.

REPRESENTATIVE CASES

Four survivors are reported in detail elsewhere.^{1,8} They will be described briefly here and emphasis will be placed on unsuccessful cases which serve to illustrate important points.

Case 1. This two-year-old boy underwent a Mustard procedure for transposition of the great vessels complicated by low cardiac output, renal failure, and disseminated intravascular coagulation. Despite maximal drug and fluid therapy this condition persisted

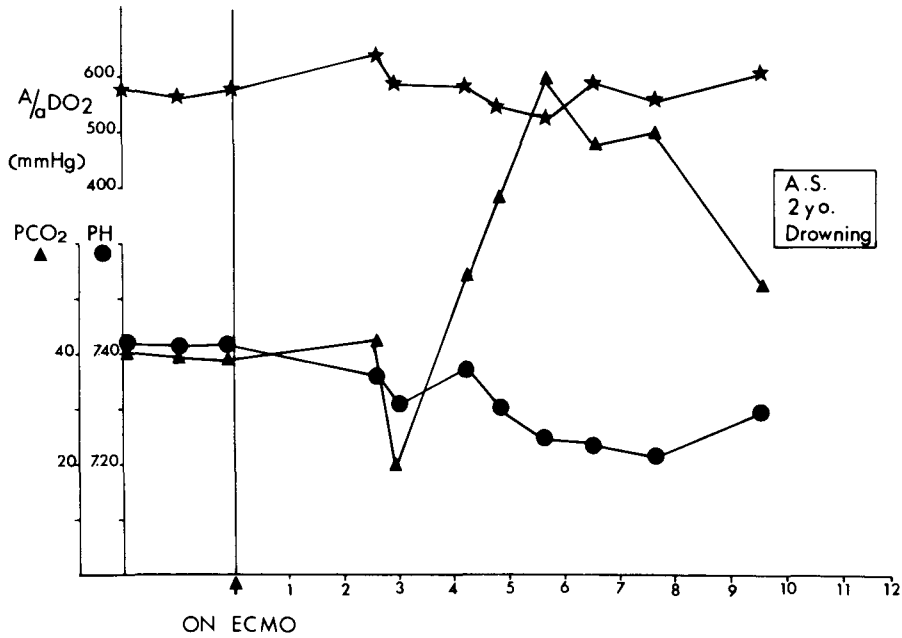


Figure 2. Lung function (during off ECMO testing) and ECMO management in Case 3.

24 hours after operation. Venoarterial bypass was instituted using jugular and axillary access. Blood pressure rose and metabolic acidosis cleared rapidly. ECMO flow was gradually weaned down as cardiac function improved. Total ECMO time was 36 hours. Pulmonary function remained adequate throughout. Renal function returned after two weeks of peritoneal dialysis. There were no further complications and the child is doing well with no cardiac, neurologic, or renal problems three years later. This case demonstrates the use of ECMO as a cardiac support system, particularly in the infant where bi-ventricular failure occurs and counter-pulsation methods are not applicable.

Case 3. This two-year-old boy sustained a near-drowning injury in an irrigation ditch. Despite a prolonged cardiac arrest and resuscitation, brain function returned to normal within a few days and the patient was left with isolated severe lung damage. This progressed slowly to the point where 100% oxygen and high ventilator pressures were required 20 days after the accident. At that time, PII was 10.0. ECMO was instituted through jugular and axillary access and total support easily maintained. Daily testing off ECMO showed no change in Aa gradient, a rapid rising pCO₂, and falling pH. Finally no testing off ECMO could be done at all without cardiac arrest. There were no complications and no positive blood cultures during 12 days of ECMO support. ECMO was terminated when there was no evidence of lung function. At autopsy the only significant finding was total pulmonary fibrosis with no normal lung tissue. This case demonstrates that ECMO can be sustained for long periods without complications, and emphasizes the need for determining the reversibility of lung function prior to ECMO whenever possible.

Case 4. This six-month-old girl was admitted with lobar staphylococcal pneumonia which progressed to involve both lungs over a period of one week. Although results with bacterial pneumonitis have been very poor in adults, the procedure has not been tested

in infants. We instituted ECMO support when PII reached 9.5. An additional blood return line to the inferior vena cava via the right saphenous vein was added during the first 24 hours of conventional arterial bypass. This was done to provide some pre-pulmonary oxygenation and allow higher pulmonary blood flow. This worked well technically but appeared to offer no advantage. Conventional VA bypass was used for the last three days of perfusion. Lung function improved, but never to the point where the patient could be taken off ECMO for more than a few hours. The limiting factors appeared to be pulmonary vascular resistance and right ventricular failure, since bradycardia, hypotension, and arrhythmia occurred despite adequate gas exchange. Nasopharyngeal and upper GI bleeding was only partially controlled by platelet transfusion. ECMO was finally discontinued because of bleeding followed by cardiac arrest several hours later. This is the only infant case in which major bleeding occurred. It is also the only infant case with major systemic sepsis, which may contribute to the thrombocytopenia and bleeding diathesis.

Case 9. This full-term newborn girl was cyanotic from birth despite intubation, mechanical ventilation, and 100% oxygen. ECMO was instituted at 18 hours of life with a presumption diagnosis of meconium aspiration. Later, however, cardiac catheterization and angiography on ECMO demonstrated persistent fetal circulation syndrome, a rare but reversible condition caused by very high pulmonary vascular resistance. A full thoracotomy and ductus arteriosus ligation was done during ECMO. Intraoperative bleeding was moderate and easily controlled. Lung function gradually improved and the child was weaned off ECMO at seven days of life, and off mechanical ventilation at nine days. Brain damage evidenced by spasticity and uncoordinated swallowing may have been due to the initial hypoxia or the ECMO procedure. Neurologic function gradually returned to normal over the next several months of life. This was the first successful application of ECMO in the newborn patient and demonstrated that the cannulation and ECMO management techniques were feasible. Cardiac catheterization, angiography, and thoracotomy were carried out during ECMO without complications.

Case 6. This full-term newborn male sustained massive meconium aspiration at birth. He required intubation, mechanical ventilation, and high FiO_2 but remained hypoxemic and acidotic. This combination carries an extremely high mortality and ECMO support was instituted using jugular and carotid access. The lungs were lavaged during venoarterial support. Lung function improved gradually over a three day period and ECMO was discontinued. The patient was extubated shortly thereafter and survived with no sequelae. This is the first successful use of ECMO in treating massive meconium aspiration syndrome, a highly lethal lesion which is ideally managed by ECMO support.

Case 7. This post-term newborn male sustained massive meconium aspiration at birth. He was managed for 24 hours at another hospital and transferred for ECMO support after several episodes of severe acidosis and hypotension requiring vaso-pressors. ECMO was carried out without difficulty with gradual improvement of lung function as in Case 6 (meconium aspiration). A patent ductus arteriosus had been demonstrated prior to transfer but repeat angiograms on ECMO demonstrated that the ductus was closed. Hemoglobinuria was present on transfer to the authors' hospital and renal failure followed shortly thereafter. Hemodialysis was carried out twice without difficulty. In spite of improved lung function, the patient's neurologic status deteriorated ultimately becoming flaccid and unresponsive. ECMO was terminated after electroencephalogram

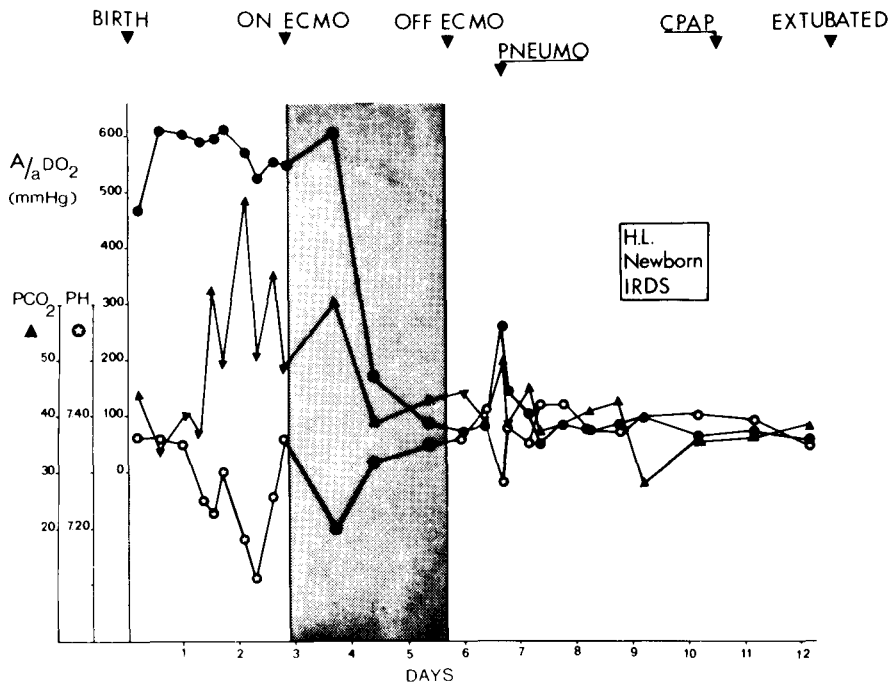


Figure 3. Lung function (during off ECMO testing) and ECMO management in Case 11.

showed no cortical activity. Extensive intracranial bleeding was found at autopsy. This case demonstrates the common problem of intracranial bleeding in newborn respiratory failure. Fatal outcome could have been predicted early in the course of management of this patient (and in Case 8- meconium aspiration) and ECMO could have been instituted prior to sustained acidosis. The cause of intracranial bleeding is unknown but seems to be related to the degree and duration of acidosis.

Case 11. This preterm male infant had typical findings of IRDS shortly after birth and was transferred to the authors' hospital. Mechanical ventilation with high pressure was required, complicated by bilateral pneumothorax and interstitial emphysema. By 24 hours of life four chest tubes had been placed to vent the massive air leak. After ECMO was instituted ventilator pressures could be turned down and the air leak decreased. Lung function improved rapidly and ECMO was discontinued after three days followed in six days by extubation. Normal growth and development followed and there is no sign of bronchopulmonary dysplasia three months after discharge. This is the first successful application of ECMO to newborn IRDS. Cardiopulmonary support permitted decreasing FiO_2 and ventilator pressure with ultimate lung recovery.

Case 13. This newborn infant weighed 1.1 kg, the smallest in our series. Severe IRDS complicated by hypoxemia, acidosis, interstitial emphysema, and pneumothorax constituted the indications for ECMO. Although perfusion went well, the lung did not improve. In fact, the left lung appeared to become worse during ECMO suggesting a patent ductus arteriosus. This diagnosis was confirmed by arteriography, injecting dye into the carotid perfusion line. A thorotomy was done and a large patent ductus ligated.

TABLE 1
Patient series.

NO.	AGE/SEX	Dx/WEIGHT	TIME ON ECMO	COMPLICATIONS	OUTCOME	COMMENTS, POSTMORTEM FINDINGS
1	E.A./2 yrs. Male	Postop Cardiac (Mustard)/9 kg.	36 hours	↓ Platelets Renal Failure	Survived	Peritoneal Dialysis
2	F./1 yr. Male	Postop Cardiac (Mustard)/7.2 kg.	9 hours	Ventric. Fibrill Renal Failure	Died	Hemodialysis
3	A.S./2 yrs. Male	Drowning/11 kg.	12 days	-	Died	Pulmonary Fibrosis No sepsis
4	M.C./6 mo. Female	Bacterial pneumonitis/6.58 kg.	5 days	Bleeding GI, naso- pharyngeal, renal failure	Died	VVA trial Seizures
5	G./newborn Male	meconium aspiration/4.27 kg.	1 hour	Seizures Temp. 42°	Died	Intracranial Bleed
6	G.M./newborn Male	meconium aspiration/2.57 kg.	3 days	-	Survived	Lung lavage on ECMO
7	Y./newborn Male	meconium aspiration/5.13 kg.	3 days	Seizures Renal Failure	Improved Died	Hemodialysis Cath & Angio on ECMO Intracranial Bleed
8	M./newborn Female	meconium aspiration/3.4 kg.	22 hours	Seizures	Improved Died	Intracranial Bleed
9	H.P./newborn Female	Persist. Fetal Circ./3.37 kg.	7 days	-	Survived	Thoracotomy - PDA Ligation Cath & Angio on ECMO
10	T./newborn Male	IRDS, cardiac arrest/3.35 kg.	6 hours	Severe acidosis Open chest resus.	Died	Cath & Angio on ECMO, Intracranial Bleed, Bowel Perforation
11	H.L./newborn Male	IRDS/1.8 kg.	3 days	Bilat. pneumothorax pre-ECMO	Survived	Cath & Angio on ECMO
12	C./newborn Female	IRDS/1.6 kg.	8 hours	Innom. Dissection Tracheal Hem.	Died	Early ruptured membranes, Strep. pneumonitis, Intracranial Bleed
13	N./newborn Male	IRDS/1.1 kg.	3 days	Memb. oxy. change Seizures	Improved Died	Thoracotomy-PDA Ligation Cath & Angio on ECMO Cerebral Edema

Lung function improved following this operation but the anterior fontanelle became tense and neurologic function ceased. Electroencephalogram showed no brain activity and ECMO was discontinued. Lung function was adequate to sustain life and mechanical ventilation was later discontinued. Autopsy showed cerebral edema but no intracranial hemorrhage. This case again demonstrated the feasibility of thoracotomy on ECMO and emphasizes the importance of a patent ductus arteriosus in newborn respiratory failure. Although there is controversy regarding early ligation of patent ductus in IRDS patients, this patient might have fared better had the ductus been ligated earlier in the course.

RESULTS

Successful cardiopulmonary support was achieved in all cases. One of two infants treated for postoperative cardiac failure recovered and survived. Pulmonary function improved in six of eleven infants treated for pulmonary failure. Three, all newborns ultimately survived. Time on ECMO ranged from one hour to 12 days (average, three days). By maintaining bypass flows between 80 and 100 cc/kg/min, adequate perfusion and gas exchange could be achieved despite minimal lung function. This permitted a decrease in the ventilator pressure and FiO_2 . Venous bypass as described was adequate to achieve these flow rates in all cases. Brain collateral circulation was tested prior to cannulation by temporary carotid occlusion. No neurologic deficit occurred, and the carotid was ligated distally and perfused proximally in all eleven cases where this was attempted. Combined veno-veno arterial bypass was used for 24 hours in Case 4. VVA bypass offered no significant improvement over VA bypass in this patient.

PULMONARY SUPPORT AND MANAGEMENT

Lung function (as measured by off-ECMO testing) usually did not improve during the first 24 hours of ECMO. Some improvement was usually apparent by 48 hours, although in Case 9 (PFC) lung function did not improve for four days. During high flow bypass, extensive lung lavage can be carried out for pneumonia or meconium aspiration, ventilator pressure can be decreased or discontinued altogether to permit sealing of large air leaks, endotracheal tubes can be changed or removed at leisure. In adults we usually maintain a continuous positive airway pressure of 10–15 cm H_2O with a slow ventilatory rate and small tidal volume to achieve a peak pressure under 40 cm H_2O to maintain alveolar inflation. In the neonate, however, the risk of intracranial bleeding may be made worse by continuous positive airway pressure, so that a ventilator pressure of 15/0 is used in those infants. FiO_2 is maintained below 0.4. Decreasing pressure and FiO_2 was possible in almost all cases. Pressure was maintained high in Case 4 (the infant with bacterial pneumonitis) with the hope of maintaining alveolar inflation. Both pressure and FiO_2 were increased late in the course of this patient when ECMO was discontinued because of bleeding. The pressure and FiO_2 were intermittently increased in Case 9 (PFC). This was quite early in our experience and these settings were increased during the time of cardiac catheterization and operation. Subsequent cases have shown that this is generally not necessary.

Since the arterial perfusate from the oxygenator has a high pO_2 , the patient's arterial pO_2 is regulated by adjusting the extracorporeal flow. Usually the highest obtainable

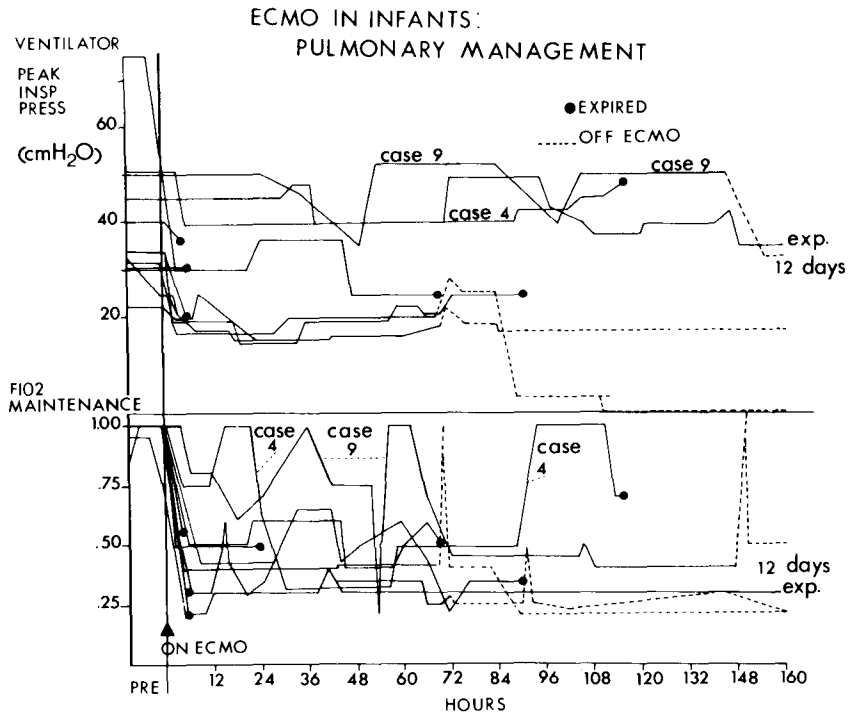


Figure 4. Ventilator management in eleven pulmonary support cases. See text for details

PaO₂ (at 80% bypass) is accepted but in preterm infants the arterial pO₂ is maintained between 50 and 70 mmHg. by adjusting the bypass flow. pCO₂ is regulated by adding CO₂ to the oxygenator ventilating gas as necessary. Decreasing pulmonary blood flow and hydrostatic pressure appears to decrease lung water. This decrease in extravascular water and central blood volume produced X-ray changes which appear to represent major improvement (clearing of infiltrates, general increased radiolucency). This paradoxical improvement in chest X-ray becomes even more noticeable if extensive pulmonary fibrosis follows the interstitial edema. The worst prognostic sign is an improving X-ray without improving physiologic function. Conversely, improvement in lung function is usually associated with a normal distribution of pulmonary blood flow as bypass flows are decreased, so that improving physiology combined with apparently deteriorating chest X-ray findings is the best prognostic sign.

CARDIAC SUPPORT AND MANAGEMENT

Ventricular fibrillation occurred in three infants before and/or during ECMO. This leads to over distention of the ventricle and irreversible cardiac damage unless the heart is compressed manually. If profound hypotension and metabolic acidosis precedes ECMO, the shock syndrome is usually irreversible despite adequate ECMO flow and gas exchange. However, ECMO does provide excellent cardiac support if there is any myocardial function. All patients are given digitalis preparations. This is particularly im-

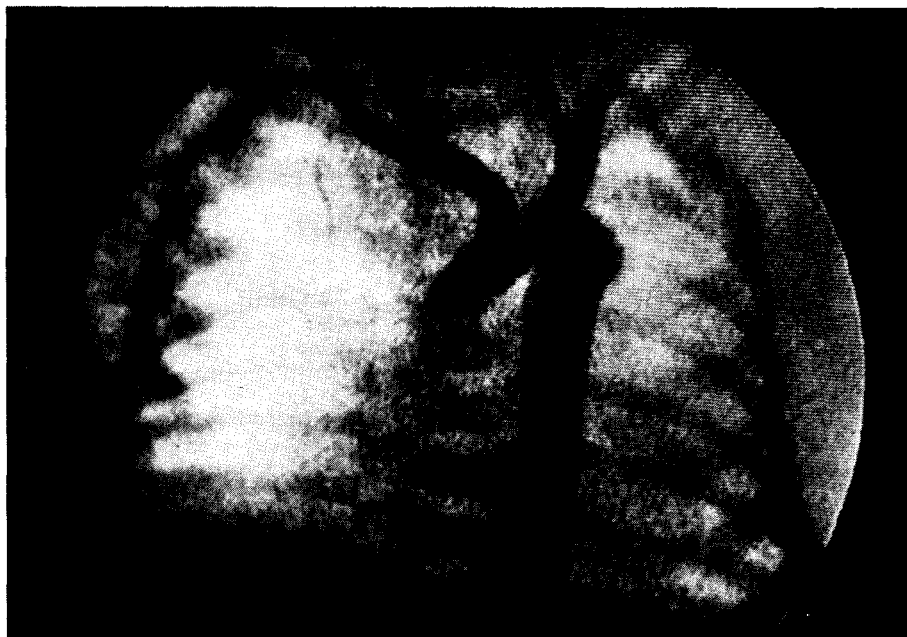

Figure 5. Arch-aortogram demonstrating root perfusion in a newborn with right carotid cannulation. Injection was made into the arterial perfusion line in the right innominate artery. The patent ductus arteriosus is not visualized because the flow is occurring right-to-left. The hyperlucent lung fields are typical of persistent fetal circulation.

portant in the pulmonary failure patients, as right ventricular function is the major determinant of successful weaning from ECMO as lung improvement occurs. Good coronary perfusion in diastole, even at low ECMO flow rate, is one of the factors accounting for sustained excellent myocardial function. This was documented in three cases in this series by arch arteriography carried out by injection of dye into the aortic perfusion catheter. These studies were done to rule out congenital heart disease or patent ductus arteriosus but also served to demonstrate good root perfusion with carotid cannulation. Systemic blood pressure and flow remains normal on ECMO. The pulse contour is kept pulsatile but pulse pressure is diminished (10–15 mm Hg in most cases). If hypotension occurs, or if the desired venous return cannot be achieved with cannulas in proper position, blood volume is increased (with packed red cells or fresh frozen plasma or both) until flow and pressure are adequate. There is some compliance in the Landé-Edwards oxygenator, particularly when used on the arterial side of the circuit, so that the blood volume has to be increased as perfusion pressure increases.

COAGULATION AND ANTICOAGULATION

Many patients had some degree of consumption coagulopathy before ECMO. Thrombocytopenia occurred in all cases. Fibrinogen and other protein coagulation factors remained normal during ECMO except in neonates who lack the full capability of clotting factor generation. The level of coagulation factors is followed by daily measurement of fibrinogen, partial thromboplastin time, thrombin time, and prothrombin time. (When

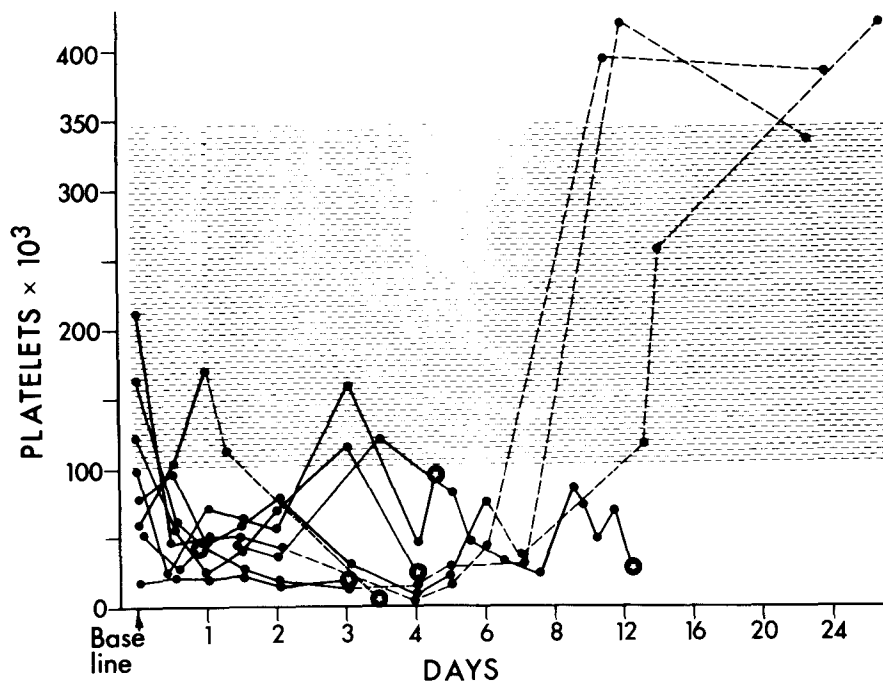


Figure 6. Changes in platelet count during ECMO in infancy.

heparin is present, it must be neutralized with polybrene prior to making these, or any other measurements which require formation of a fibrin clot as the end point.) If these studies demonstrated a deficiency of coagulation factors, fresh frozen plasma was infused until the levels were returned to normal. Although it may seem paradoxical to infuse fresh frozen plasma and heparin simultaneously, this combination seems to offer the best prevention of bleeding and stabilization of heparin dose.

Moderate thrombocytopenia is well tolerated. Platelet transfusions were given to most patients at some time during ECMO. Rebound of platelet count and fibrinogen to levels as high as twice normal was noted in survivors, as had been noted in the sheep. Evidence of intravascular clotting was noted on several occasions when the heparin dose was decreased and clotting time fell to near normal levels. This was associated with an abrupt drop in platelet count and clotting factors and an increase in fibrin degradation products (FDP). Usually this occurred as a single event. In one case (IRDS) in which platelets and calcium were added to the priming solution before the prime was adequately heparinized, significant levels of FDP were measureable throughout three days of ECMO and gross clots were found in sections of the bypass circuit. Systemic arterial emboli were not found in any patients, including the latter.

COMPLICATIONS

Artificial organ or technical complications occurred in five patients. The only complication related to cannulation, a subintimal dissection of the innominate artery

occurred in Case 12 (IRDS, 1.6 kg) resulting in inadequate perfusion to the right arm. Severe hypoxemia and cardiac arrest occurred while attempting to replace this cannula. In Case 5 (meconium aspiration) hyperthermia of 42°C occurred when the heat exchanger control malfunctioned. The membrane oxygenator had to be replaced during ECMO in three patients. In Case 4 (bacterial pneumonitis) and 13 (IRDS) clots formed in the oxygenator. In both cases this was associated with low flows off bypass and recent platelet infusion. No systemic embolism resulted from this clotting but poor gas transfer was observed. In Case 3 (fresh water drowning) loss of CO₂ transfer was noted when the gas phase became filled with condensed water. This will invariably occur if low gas flows are used. In this case low gas flow was used during a 1,000 mile transport on ECMO by aircraft. The oxygenator was changed without difficulty. Examination of the entire bypass circuit at the end of each case showed negligible thrombus in the oxygenator or other parts of the system except for the cases mentioned above. Small areas of "white" thrombus composed of fibrin and platelets could be found firmly adherent at most connections in the circuit.

Endogenous organ complications were primarily related to brain or renal function. Renal failure could usually be traced to hypotension or hemoglobinuria occurring before ECMO. Management of renal failure with dialysis on ECMO is not difficult. One of the patients with renal failure continued on peritoneal dialysis for two weeks and ultimately survived with normal renal function. Twitching, grimacing, and some involuntary movement occurred in all children. If the child was easily roused, responded normally to tactile and verbal stimuli, and retained normal sucking, Moro, or deep tendon reflexes, no evidence of permanent brain damage was found on follow-up or autopsy (7 cases). Coma, flaccidity, loss of ocular reflexes (and bulging fontanelle in the neonate) was associated with intracranial bleeding or severe cerebral edema at autopsy (6 cases). Aside from intracranial hemorrhage, bleeding complications were rare. ECMO was instituted during thoracotomy in Cases 2 (postoperative mustard) and 10 (IRDS), and full thoracotomy and ductus ligation was carried out during ECMO in Cases 9 (PFC) and 13 (IRDS). Moderate bleeding during these procedures was minimized by infusion of platelets. Major bleeding complications occurred in only one patient, Case 4 (bacterial pneumonitis), the infant with staphylococcal pneumonitis. ECMO had to be discontinued because of upper-gastrointestinal and nasopharyngeal bleeding on the fourth day.

Autopsy results showed the expected cardiac or pulmonary diagnosis in most cases. Total pulmonary fibrosis with minimal infection was found in the infant supported for 12 days for a near-drowning accident. The typical findings of IRDS or meconium aspiration were found in the neonates with one exception. Case 12 (IRDS)—a preterm infant with a clinical diagnosis of IRDS—had very hemorrhagic lungs due to newborn streptococcal infection, a condition which presents a clinical picture very similar to IRDS.⁹ Case 10 (IRDS) had evidence of a prenatal intestinal perforation in addition to IRDS which undoubtedly contributed to the early rapid downhill course in this case. The other striking findings were intracranial bleeding (5 cases) or extensive cerebral edema (1 case) which occurred in all neonatal deaths. Intracranial bleeding is usually found at autopsy in newborn infants who die of respiratory failure (80% of such autopsies in this hospital) but the extent of this bleeding may be exacerbated by heparinization and ECMO.

Growth and development, psychomotor function, pulmonary function, and chest X-ray are all normal for the four survivors at three years, eleven months, four months, and three months after ECMO. One child (Case 9-PFC), had a spastic right arm and

uncoordinated swallowing for the first few months after ECMO but these findings have gradually resolved.

DISCUSSION

Rashkind, et al.¹⁰ first explored extracorporeal oxygenation in infants, using arteriovenous flow through a bubble oxygenator. The techniques of ECMO in infancy were originally studied by Dorson, et al.¹¹ under a protocol designed to evaluate the feasibility in three moribund infants with IRDS. None of these infants survived but the feasibility of extracorporeal circulation in infants was documented. The flow and gas exchange limitations posed by cannulation sites was brought out in this study. White and associates¹² instituted ECMO support in three newborn infants for IRDS who did not respond to maximal conventional management. Support was maintained for two, three, and ten days. Vascular access was through the right internal jugular and umbilical vessels using veno-venous bypass. Pyle and associates¹³ have recently reported a trial of ECMO in two neonates with meconium aspiration and IRDS. Although all the infants in these early trials died, important observations regarding vascular access, heparinization techniques, and clinical course were made. Intracranial bleeding and renal failure were the major problems in these series.

Hicks and Edmunds¹⁴ have used ECMO support in two children. One three-year-old with severe varicella pneumonia was supported for three days and survived. Vascular access was obtained via the right internal jugular and axillary artery (after femoral perfusion proved unsuccessful). Soeter and McNamara² successfully used ECMO for combined cardiac and pulmonary support in a four-year-old child following operation for tetralogy of Fallot. Kolobow, et al.¹⁵ used venous-venous ECMO support in a nine year old child for pneumocystis carinii pneumonia. This patient was on bypass for ten days and survived, the longest successful ECMO support case to date. Awad¹⁶ reported successful 48 hour ECMO support in a four-year-old child for cystic fibrosis complicated by pneumonia. Other trials of ECMO in infancy which are listed in the registry compiled by Dr. J. P. Gille of France¹⁷ include cases from groups headed by Zapol, Hill, Bernhard, Rocmans, Gajdos, Kalmar, and Stanford.

INDICATIONS

Any cause of acute reversible pulmonary failure in *infancy* may be an indication for ECMO, including bacterial, viral, or chemical pneumonitis, near-drowning, smoke inhalation, and other forms of aspiration, capillary leak and immunologic syndromes and direct lung trauma.

The pulmonary insufficiency index¹⁸ developed for predicting mortality risk in adults seems to apply to infants outside of the neonatal period as well. Infants with acute but reversible pulmonary failure who reach an index of 3.0 have a high mortality risk. In the absence of contraindications, ECMO may be considered when PII reaches 4–6. If the PII is over 10 the lung is probably irreversibly damaged. There is, as yet, no similar index to define indications for extracorporeal support of cardiac failure in the infant, however, inability to wean off cardiopulmonary bypass in the operating room (as in Case 2—post-operative mustard), or persistent hypotension, oliguria, and metabolic acidosis despite maximal therapy (as in Case 1—postoperative mustard) are valid indications.

Pulmonary failure requiring mechanical ventilation in the *newborn* is almost always due to IRDS, meconium aspiration, or persistent fetal circulation. In the latter two conditions, mortality risk is greater than 90% for infants who require mechanical ventilation with high pressures and FiO_2 greater than 0.8 for more than 12 hours after birth. ECMO should be considered for those patients. Quantitating IRDS is a more difficult problem. Several authors have developed scoring systems to predict mortality risk in IRDS.¹⁹⁻²¹ It is important to identify the high risk IRDS infant early, as the incidence of intracranial bleeding or bronchopulmonary dysplasia increase with time. If ECMO is to be used in IRDS it should be instituted in high mortality risk infants before intracranial bleeding or irreversible lung damage takes place.

TECHNICAL CONSIDERATIONS

In addition to the vascular access sites, circuit design, maintenance flow rates, and cardiopulmonary management methods outlined above, we consider the following points important for other groups attempting ECMO in infancy. The extracorporeal circuit and cannulation should be capable of total cardiopulmonary support if and when necessary. Good perfusion of the aortic root should be assured, even at low bypass flows. The components of the priming blood should be as nearly normal as possible, particularly in neonates. The use of fresh heparinized blood from the mother or another matched donor is suggested for priming (rather than ACD or CPD anticoagulated bank blood).

- Continuous heparin infusion should be used. If heparin dose falls too low clotting will occur in the extracorporeal system with liberation of fibrin degradation products. Heparin effect should be measured at least hourly using a whole blood activated clotting time technique. The effect of any heparin dose is inversely proportional to the number of platelets, so that anticoagulant monitoring based on plasma measurements will be misleading. The Hemochron™ device for automatic measurement of whole blood activated clotting time has been widely used for heparin control during ECMO.²² This device requires 2 cc of blood for each measurement, and has produced some unreliable results in our experience, so that we continue to rely on the manual "Bason" ACT measurement for infant ECMO. Because the platelet counts are usually low, electronic counting devices may be unreliable and direct counting by phase microscopy must be done. We consider the coagulation laboratory—available 24 hours a day and accustomed to dealing with measurements in heparinized and thrombocytopenic blood—essential to the success of the infant ECMO program.

Finally, the importance of developing the technique and training a large technical team in the laboratory can not be over emphasized. It is advisable to begin clinical trials only after successful 48 hour perfusion of small animals can be done regularly in the laboratory.

SUMMARY

The authors have used prolonged extracorporeal membrane oxygenation (ECMO) in the treatment of thirteen moribund infants (including nine neonates), with four survivors (three neonates). Successfully treated cases include postoperative cardiac failure, infant respiratory distress syndrome, massive meconium aspiration, and persistent fetal

circulation. All cases have been managed with venoarterial bypass at flow rates of 80–100 cc/kg/min. Carotid cannulation for arterial access and careful control of heparin anticoagulation based on whole blood activated clotting time are among the techniques which have contributed to this success. Progressive pulmonary or cardiac failure has been the major problem in older infants, intracranial bleeding is the major problem in neonates. Both of these problems could be minimized by instituting ECMO earlier in the clinical course, but this awaits development of reliable early predictors of mortality.

REFERENCES

1. Bartlett, R. H., Gazzaniga, A. B., et al., Prolonged extracorporeal cardiopulmonary support in man. *J. Thorac. Cardiovasc. Surg.* 68(6): 918–932, 1974.
2. Soeter, J. R., Mamiya, R. T., Sprague, A. Y., McNamara, J. J., Prolonged extracorporeal oxygenation for cardiorespiratory failure after tetralogy correction. *J. Thorac. Cardiovasc. Surg.* 66: 214, 1973.
3. Bartlett, R. H., Fong, S. W., Burns, N. E., Gazzaniga, A. B., Prolonged partial venoarterial bypass: Physiologic biochemical and hematologic responses. *Ann. Surg.* 180: 850, 1974.
4. Bartlett, R. H., Burns, N. E., Fong, S. W., Gazzaniga, A. B., Achauer, B. M., Fraile, J., Prolonged partial venoarterial bypass: Physiologic biochemical and hematologic responses. *Surg. Forum* 23: 178, 1972.
5. Roohk, H. V., Pick, J., Hill, R., Hung, E. K., Bartlett, R. H., Kinetics of fibrinogen and platelet adherence to biomaterials. *T.A.S.A.I.O.* 22:1, 1976.
6. Baden, J. P., Sonnefield, M., Ferlic, R. M., Sellers, R. D., The Bason test: A rapid bedside test for control of heparin therapy. *Surg. Forum* 32: 172, 1971.
7. Bartlett, R. H., Isherwood, J., Moss, R. A., Olszewski, W. L., Polet, H., Drinker, P. A., A toroidal flow membrane oxygenator: Four day partial bypass in dogs. *Surg. Forum* 20: 152, 1969.
8. Bartlett, R. H., Gazzaniga, A. B., Fong, S. W., Jefferies, M. R., Haiduc, N., Extracorporeal membrane oxygenator support for cardiopulmonary failure: Experience in 28 cases. *J. Thorac. Cardiovasc. Surg.* 73: 3375–3386, 1977.
9. Ablow, R. C., Driscoll, S. G., Effmann, E. L., Gross, J., Jolles, C. J., Uauy, R., Warshaw, J. B., A comparison of early-onset group B streptococcal neonatal infection and the respiratory distress syndrome of the newborn. *New Eng. J. Med.* 294(2): 65–70, 1976.
10. Rashkind, W. J., Freeman, A., Klein, D., Toft, R. W., Evaluation of a disposable plastic low volume, pumpless oxygenator as a lung substitute. *J. Ped.* 66: 94–102, 1965.
11. Dorson, W. J., Baker, E., Cohen, M. L., Meyer, B., Molthan, M., Trump, D., Elgas, R., A perfusion system for infants. *T.A.S.A.I.O.* 15: 155, 1969.
12. White, J. J., Andrews, H. G., Risemberg, H., Mazur, D., Haller, J. A., Prolonged respiratory support in newborn infants with a membrane oxygenator. *Surgery* 70(2): 288–296, 1971.
13. Pyle, R. B., Helton, W. C., Johnson, F. W., Hornung, J. R., Hunt, C. E., Trumball, H. R., Lindsay, W. G., Nicoloff, D. M., Clinical use of the membrane oxygenator. *Ann. Surg.* 110: 966–970, 1975.
14. Hicks, R. E. and Edmunds, L. H., personal communication.
15. Kolobow, T., Stool, E., Sacks, K., Veruk, G., Acute respiratory failure—Survival following ten days support with membrane lung. *J. Thorac. and Cardiovasc. Surg.* 69(6): 947–953, 1975.
16. Awad, J. A., Matte, J., Brassard, A., Prolonged extracorporeal respiration with a membrane gas exchanger. *J. Thorac. Cardiovasc. Surg.* 66(1): 40–51, 1973.
17. Gille, J. P. World census of long term perfusion for respiratory support. *Proc. Int. Conf. Lung Technology*, 1975, in press.
18. Bartlett, R. H., Gazzaniga, A. B., Wilson, A. F., Medley, T., Wetmore, N., Mortality prediction in adult respiratory insufficiency. *Chest* 67: 680–84, 1975.
19. Stahlman, M. T., Battersby, E. J., Shepard, F. M., Blankenship, W. J., Prognosis in hyaline membrane disease—use of a linear discriminant. *New Eng. J. of Med.* 276(6): 303–309, 1967.
20. Downes, J. J., Dharmapuri, V., Morrow, G. M., Boggs, T. R., Respiratory distress syndrome of newborn infants—I. New clinical scoring system (RDS Score) with acid-base and blood gas correlation. *Clin. Peds.* 9(6): 325–331, 1970.
21. Murdock, A. I., Corey, P., Swyer, P. R., An objective multifactorial linear discriminant scoring system for neonates with respiratory distress syndrome. *Biol. Neonate* 18: 263–278, 1971.
22. Hill, J. D., Dontigny, L., deLeval, M., Mielke, C. H., A simple method of heparin management during prolonged extracorporeal circulation. *Ann. Thor. Surg.* 17: 129, 1974.