
Simplified Cardioplegia Administration and Left Heart Venting

Jim Kersting, C.C.P.

Perfusion Services, Inc.*
10700 Arbour Court
Brighton, Michigan 48116

Abstract

A new method is described which makes it easier to implement the technique of single-catheter cardioplegia administration and left heart decompression and venting. The method is potentially both simpler and safer than others commonly used in coronary artery surgery.

Introduction

In the interests of simplicity, safety, and expediency during cardiac surgery it is desirable to eliminate as many intrathoracic devices as possible. One such bulky example has been the left heart venting apparatus. Most methods and devices have involved insertion of a catheter into the left heart through 1) the left atrium, 2) the left superior pulmonary vein via Sonnengaard's groove, or 3) direct apical left ventricular puncture.¹⁻⁶

Disadvantages to the above methods are many and well documented. They place additional cumbersome and time-consuming apparatus in the operative field and within the heart.^{2,3,7,8} They are a potential source of intracardiac air, particularly with the use of the "sump type" of disposable left ventricular vent catheter*.^{1-3,7,8} Bleeding of left ventricular and left atrial insertion sites is not uncommon, nor are lacerations of the left atrial wall.^{4,7} Left ventricular puncture has been implicated in the presence of new, postoperative

pathologic Q waves which are indicative of local myocardial injury.^{3,8,11,12}

Methods

As an alternative to additional devices and access sites, a workable method is presented for making the existing cardioplegia administration aortic puncture serve dual duty in providing for left heart decompression as well. The single aortic catheter is used to first administer pressurized cardioplegia solution into the proximal aortic root following aortic cross-clamping. Subsequently, the pump suction tubing for left heart decompression vents from the same site, achieving drainage antegrade through the open left ventricular outflow tract (See Figure 1).

Heretofore the problem has been the devising of a simple, competent method for selecting between "cardioplegia in" and "vent out" modes. A disposable three-way stopcock** formerly used held two disadvantages. The small internal bore prohibited rapid infusion of cardioplegic solution, and caused poor, slow drainage of the left heart. Secondly, suction from the vent pump very effectively cavitated bubbles into the system as blood gases came out of solution from the sudden pressure drop where the stopcock connected to the much larger bore pump tubing. Such air had the potential to re-enter the aorta following any sudden release of the suction. This was unacceptable performance, particularly as a major objective was to achieve a *safer* method of decompression.

* Proofs and reprint requests to the above address

* #8888-590232, 22 French, Sherwood Medical Industries, St. Louis, Missouri

** # K69, Pharmaseal, Inc., Tao Alta, Puerto Rico

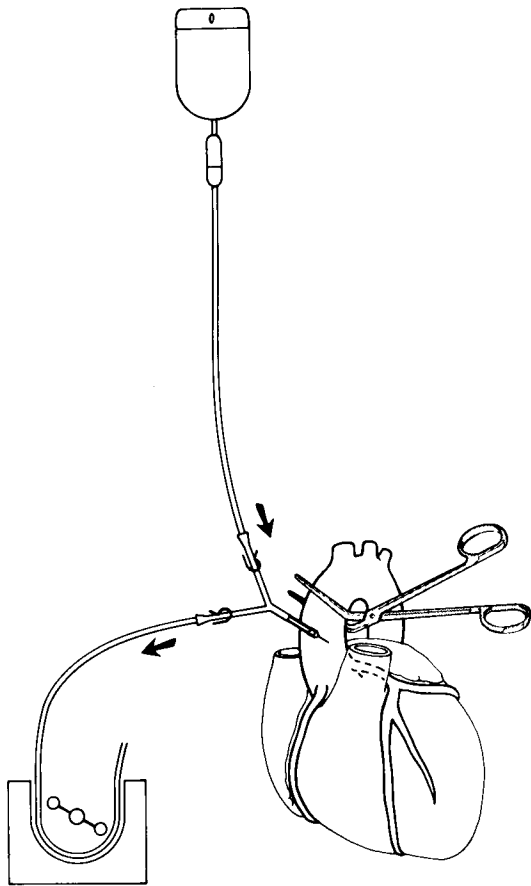


FIGURE 1.

The new Y-adapter device***, shown in Figure 2, has solved all of these problems and has provided for both a simpler technique and a neater surgical field. It features a female luer inlet tip which accepts a male luer from a typical cardioplegia administration set, and a tubing connector on the outflow arm to accommodate the vent pump's 1/4 inch internal diameter tubing. The distal end terminates in a 3 millimeter internal diameter male luer-lock fitting. Flow-directionally marked thumb-actuated clamps select and shut off the "cardioplegia in" and "vent out" modes.

For maximum effectiveness of this technique, an aortic catheter with minimal impediment to flow should be selected. Suitable performance has been obtained with standard large bore angiocaths**** (usually with side holes cut in them), the pharyngeal oxygen therapy catheter***** described elsewhere,^{9,10} and an aortic

*** #10005, DLP, Inc., Walker, Michigan

**** #2812, 14 guage, The Deseret Company, Sandy, Utah

***** 10 French, Pharmaseal Inc., Tao Alta, Puerto Rico

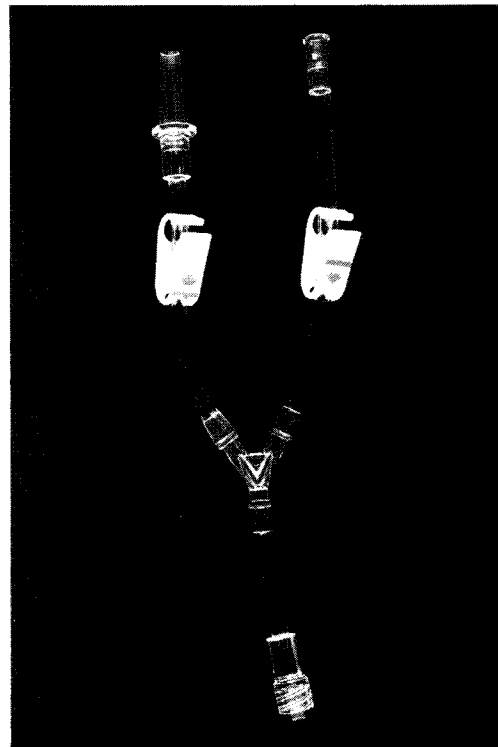

FIGURE 2.

root cannula suitable for purse-string retention*****.

Results and Discussion

The system is easily primed by selectively clamping and successively flushing each arm of the Y-adapter. This is then connected at its distal male tip to the back-bleeding aortic catheter which has already been placed. No air has been observed in the system or in the left heart during use, so that the possibility of air passing from the vent arm back into the aorta with intermittent cardioplegia administration has not been experienced. Any air which would occur in the aorta will float to the top (at the puncture site); this air can then be conveniently purged at the end of the procedure when the aortic catheter is withdrawn.^{9,10,13}

The coronary arteries have remained conveniently free of blood during decompression with this technique, and the aorta remains evacuated. No left ventricular vent in the traditional sense has been necessary during these procedures.

***** #10012, 12 guage, DLP, Inc., Walker, Michigan

The technique is adaptable to a variety of protocols as well. It is suitable for either "clear" or blood cardioplegia, either pump or gravity infused. The heart can alternately be decompressed by gravity drainage in lieu of pump suction.

Conclusion

The new Y-adaptor increases the effectiveness of a method for intraoperative cardioplegic arrest and left-heart venting. It is inexpensive, convenient, and safe; and it offers a neater operative field to the surgical staff.

References

1. Olinger, G. M. and Bonchek, L. I.: Ventricular Venting During Coronary Revascularization: Assessment of Benefit by Intraoperative Ventricular Function Curves. *Ann Thor Surg.* 26:525-534, 1978.
2. Buckberg, G. D.: The Importance of Venting the Left Ventricle, Editorial. *Ann Thor Surg.* 20:488-490, 1975.
3. Atrom, K. V., Vinas, J. F., Fewel, J. E., Bishop, V. S., Grover, F. L., and Trinkle, J. K.: Is a Left Ventricular Vent Necessary During Cardiopulmonary Bypass? *Ann Thor Surg.* 24:566-573, 1977.
4. Harlan, B. J., Kyger, E. R., Reul, G. J., and Cooley, D. A.: Needle Suction of the Aorta for Left Heart Decompression During Aortic Cross Clamping. *Ann Thor Surg.* 23:259-260, 1977.
5. Siderys, H.: The Superior Approach for Operative Decompression of the Left Side of the Heart. *Ann Thor Surg.* 17:277-279, 1974.
6. Sproul, G., Pinto, J., Trummer, M. J., and Devin, J.: Simplified Left Ventricular Venting. *J Thor Card Surg.* 65:433-434, 1973.
7. Ulliyot, D. J.: Current Controversies in the Conduct of the Coronary Bypass Operation. *Ann Thor Surg.* 30:192-203, 1980.
8. Salerno, T. A. and Charette, E. J. P.: Elimination of Venting in Coronary Artery Surgery. *Ann Thor Surg.* 27:340-343, 1979.
9. Engleman, R. M. and Rousou, J. H.: Left Ventricular Venting During Cardioplegic Arrest. *Ann Thor Surg.* 28:603-604, 1979.
10. Vertrees, R. A., Auvil, J., Rousou, J. H., and Engleman, R.: A Technique of Myocardial Preservation Perfusion. *Ann Thor Surg.* 28:601-602, 1979.
11. Aintablian, A., Hamby, R. I., Hoffman, I., Hartstein, M. L., and Wisoff, B. G.: New Q Waves After Bypass Grafting: Correlations Between Graft Patency, Ventriculogram, and Surgical Venting Technique. *J. Electrocardiology.* 9:321-327, 1976.
12. Aintablian, A., Hamby, R. I., Hoffman, I., Weisz, D., Voleti, C., and Wisoff, B. G.: Significance of New Q Waves After Bypass Grafting: Correlations Between Graft Patency, Ventriculogram, and Surgical Venting Technique. *Am Heart Jour.* 95:429-440, 1978.
13. Philips, P. A. and Adams, H. D.: Myocardial Protection: A Safe Cardioplegic Catheter. *Ann Thor Surg.* 30:97-98, 1980.