
Effective Venous Cannulation for Total Cardiopulmonary Bypass and Cardioplegic Arrest

Victor Aldrete M.D., F.R.C.S. (C)

Division of Cardiac Surgery
The General Hospital
St. John's, Newfoundland, Canada
A1B 3V6

Jim Kersting, CCP

Project Four Perfusion Services, Inc.
2033 Gloucester Street
Boise, Idaho
83706

Abstract

A technique is described which permits complete and reliable drainage of the heart and lungs during total cardiopulmonary bypass for coronary artery bypass grafting. The technique minimizes the influx of warm blood into the arrested heart, and utilizes existing disposable devices.

Introduction

Total cardiopulmonary bypass as achieved by individual, snared caval venous return cannulae has been an accepted technique in open cardiac surgery for many years. Following the advent of "non-intracardiac" coronary artery bypass surgery, it no longer became necessary to ensure a bloodless field by diverting all vena caval blood to the pump oxygenator. The use of unsnared caval cannulae or a single right atrial venous return cannula*,** (often in conjunction with a left heart vent) has come into popularity as a result, saving the surgeon time in the cannulating process and decreasing the amount and complexity of apparatus within the operative field.^{1,2}

Use of the single right atrial cannula, however, creates the potential for two problems. Under mechanical retraction and manipulation of the heart during bypass, venous return to the pump oxygenator can often be significantly compromised.^{1,3} Not infrequently, distension ensues from the resulting intracardiac volume which may accumulate and overload the left heart decompression apparatus.^{3,4} Secondly, as use of the right atrial cannula technically constitutes *partial* bypass, some amount of warm systemic blood continually enters the heart. During periods of cold cardioplegic arrest, this systemic influx prematurely warms the heart, compromising hypothermic protection of the ischemic myocardium.^{1,6} Animal laboratory studies have been designed which substantiate this phenomenon.^{5,7}

A method of venous cannulation for *total* cardiopulmonary bypass during coronary artery grafting was implemented which would in a simple way eliminate these undesired effects.

Method

Following sternotomy, hemostasis, preparation of the pericardium and systemic heparinization, a "two-stage" venous return cannula* is inserted through a

Reprint requests to Jim Kersting CCP at above address

Article submitted 8/81, revised 9/17/81, accepted 10/28/81.

* # 10150, 51 french, Sarns, Inc., Ann Arbor, Michigan.

** #008051, 46 french, William Harvey, Inc., Santa Ana, California.

* # 12340, Sarns, Inc., Ann Arbor, Michigan.

purse string suture in the right atrial appendage. It is advanced sufficiently far so that the larger basket occupies the atrium, and the small basket drains the inferior vena cava. The purse string suture is drawn up through a ligature tube, secured with a clamp, and a snare placed around the inferior vena cava at the distal portion of the cannula. Similarly, a conventional caval venous return cannula** is inserted into the right atrium through a purse string suture and advanced into the superior vena cava. This purse string is then secured through a ligature tube, and a snare placed around the superior vena cava. The caval snares are secured upon initiation of bypass.

Total cardiopulmonary bypass can then be assured, with no systemic venous blood escaping the snared vena caval cannulae. Any incidental intracardiac blood will then also drain via the right atrial basket (Figure 1).

Discussion

Use of this venous cannulation technique has allowed manipulation of the heart at liberty without any disruption of steady venous return to the pump oxygenator. This has proven especially valuable when the heart must be retracted upwards in order to graft posterior vessels, a common situation which can greatly impede venous drainage with the use of a single right atrial cannula. Concomitant difficulties with elevated filling pressures are also typically reduced.

With little or no warm systemic venous blood re-entering the heart through the right atrium, less frequent administration of cardioplegia solution may be required. The myocardial temperature should not rise as fast when isolated in this manner, and is presumably maintained at a more stable mean temperature throughout the period of cold arrest.

During cardiopulmonary bypass there is usually other incidental (and sometimes warm) blood return to the heart via the bronchial and coronary sinus return, and through the intramural, pericardial, and mediastinal vasculature.^{3,8,9,10} Drainage of this volume is provided for by the large basket cannula opening which occupies the right atrium. This drainage capability, in combination with the tightly snared vena cavae, can be so effective as to eliminate the need for left heart decompression and its attendant bulky and potentially morbid apparatus.^{1,3,4,8,9,11,12}

** # 11490, 36 french, Sarns, Inc., Ann Arbor, Michigan.

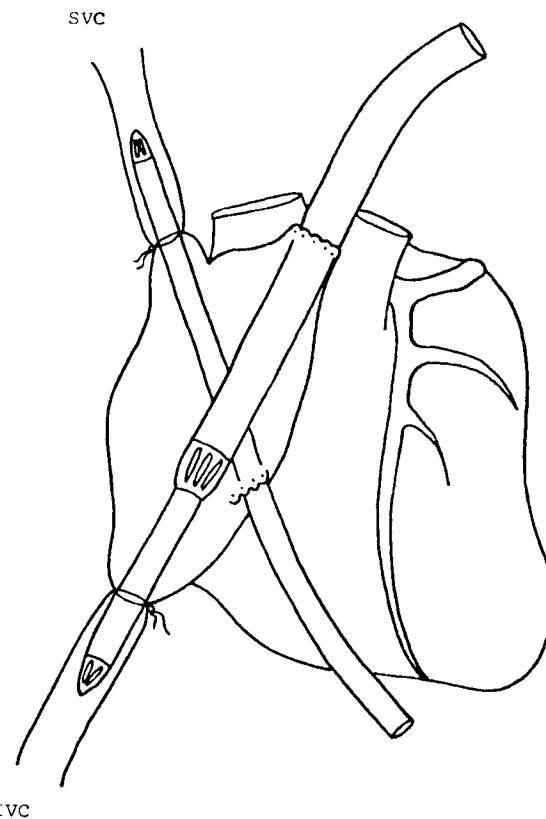


FIGURE 1.

Conclusion

A technique of venous cannulation for total cardiopulmonary bypass during coronary artery revascularization is available which minimizes or eliminates three distinct situations requiring sometimes considerable attention of the surgeon or perfusionist. This technique 1) provides maximal trouble-free venous drainage to the pump oxygenator, 2) helps to maintain the myocardium at a stable hypothermic arrested state, and 3) reduces or potentially eliminates the need for intracardiac decompression. The technique is safe, simple, and easily implemented with readily available disposable devices.

References

1. Ulliyot, D. J.: Current Controversies in the Conduct of the Coronary Bypass Operation, *Ann Thor Surg*, 30:192-203, 1980.
2. Miller, D. W. Jr., Hessel, E. A. II, Winterscheid, L. C., Merendino, K. A., and Dillard, D. H.: Current Practice of Coronary Artery Bypass Surgery, *J Thor Card Surg*, 73:75-83, 1977.
3. Salerno, T. A., and Charette, E. J. P.: Elimination of Venting in Coronary Artery Surgery, *Ann Thor Surg*, 27:340-343, 1979.
4. Zwart, H. H. J., Brainard, J. Z., and DeWall, R. A.: Ventricular Fibrillation Without Left Ventricular Venting, *Ann Thor Surg*, 20:418-423, 1975.

5. Rosenfeldt, F. L., and Watson, D. A.: Interference with Local Myocardial Cooling by Heat Gain During Aortic Cross Clamping, *Ann Thor Surg*, 27:13-16, 1979.
6. Clark, S., Prioleau, W. H. Jr., Weinrich, M., Voegele, D., and Hairston, P.: Influence of Total vs. Partial Cardiopulmonary Bypass on Myocardial Preservation: A Clinical Study, *J Extracorporeal Technology*, 11:195-199, 1979.
7. Hood, A. G. et al.: Effects of Cannulation Technique and Topical Hypothermia on Cardiac Temperature During Cold Cardioplegia, *J Extracorporeal Technology*, Proceedings, VI, 1978.
8. Atrom, K. V., Vinas, J. F., Fewel, J. E., Bishop, V. S., Grover, F. L., and Trinkle, J. K.: Is a Left Ventricular Vent Necessary During Cardiopulmonary Bypass?, *Ann Thor Surg*, 24:566-573, 1977.
9. Salerno, T. E., and Charette, E. J. P.: Prospective Analysis of Valvular Replacement Without Venting the Left Ventricle, *J Thor Card Surg*, 78:131-135, 1979.
10. Nelson, R. L., Goldstein, S. M., McConnel, D. H., Maloney, J. V. Jr., and Buckberg, G. D.: Studies of the Effects of Hypothermia on Regional Myocardial Blood Flow and Metabolism During Cardiopulmonary Bypass, *J. Thor Card Surg*, 73:201-207, 1977.
11. Salomon, N. W., and Copeland, J. G.: Single Catheter Technique for Cardioplegia and Venting During Coronary Artery Bypass Grafting, *Ann Thor Surg*, 30:88-89, 1980.
12. Stoney, W. S., Alford, W. C. Jr., Burrus, G. R., Glassford, D. M. Jr., and Thomas, C. S. Jr.: Air Embolism and Other Accidents Using Pump Oxygenators, *Ann Thor Surg*, 29:336-340, 1980.