
Case Reports: Use of Intraoperative Dye Dilution Cardiac Output in the Diagnosis of Hypoxia Due to Persistent Shunting After Intracardiac Repair with Cardiopulmonary Bypass

Gerald S. Lefever, Larry W. Stephenson, Priscilla Hillyer, Ann M. Showan

Department of Anesthesia and Division of Cardiothoracic Surgery, The Children's Hospital of Philadelphia, and University of Pennsylvania School of Medicine

Abstract

The rapid diagnosis of hypoxemia following repair of intracardiac defects is crucial. Although the technique of thermodilution cardiac output is popular in operating rooms and in intensive care units, it yields little information regarding intracardiac shunting. In this report of two pediatric cases, the examination of dye dilution cardiac output curves obtained intraoperatively post intracardiac repair and cardiopulmonary bypass allowed the prompt diagnosis of persistent right-to-left shunting through unrecognized cardiac defects. The dye dilution technique should be considered intraoperatively after cardiopulmonary bypass when hypoxemia may be due to residual intracardiac shunting.

Introduction

The differential diagnosis of hypoxemia following cardiopulmonary bypass may present a difficult challenge to the surgeon, anesthesiologist, and cardiologist. Potential causes include unrecognized error in oxygen administration, a misplaced or partially occluded endotracheal tube, pulmonary edema, venous admixture,

ventilation perfusion mismatch, and intracardiac shunting. Rapid diagnosis and treatment of hypoxemia is imperative in these critical patients.

In two recent pediatric cases when significant unexpected hypoxemia was noted shortly after bypass had been discontinued, dye dilution curves in the operating room provided an accurate diagnosis. The technique of thermodilution cardiac output has replaced the dye dilution method in most operating rooms and intensive care units today. However, the thermodilution technique would not have correctly diagnosed the cause of hypoxemia in the following two patients.

Case Reports

Case 1: An 18 month-old 4-kg female had severe pulmonary valvular and infundibular stenosis. The preoperative cardiac catheterization data showed left ventricular pressure 107/6 mmHg, right ventricular pressure 226/9 mmHg, and a slight increase in oxygen saturation at the right atrial level. The hemoglobin concentration was 16.4 gm/dl. The halothane-nitrous oxide-oxygen anesthetic was uncomplicated and the PaO₂ was 88 torr (FIO₂ = 0.3). During cardiopulmonary bypass the right atrium was opened and no atrial septal defect was identified. Pulmonary valvulotomy and infundibular resection were then performed. Post bypass the initial PaO₂ was 47 torr (FIO₂ = 1.0) and fell to 37 torr. After repeated maneuvers to verify the patency and position of the endotracheal tube, a dye

Mailing Address—Proofs & Reprint Requests: Gerald S. Lefever, M.D., Ph.D. Assistant Professor of Anesthesia & Pharmacology, Children's Hospital of Philadelphia, 34th Street & Civic Center Boulevard, Philadelphia, Pennsylvania 19104

Presented at the Annual Meeting of the Society of Cardiovascular Anesthesiologists, Kiawah Island, South Carolina, August, 1980.

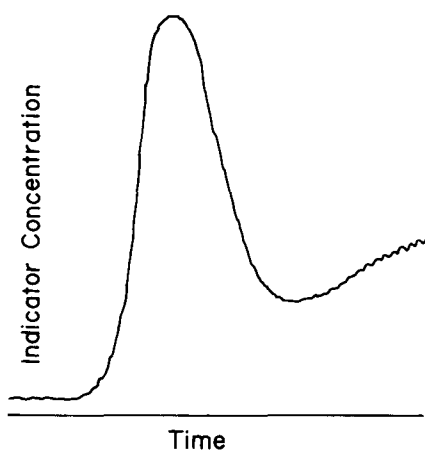
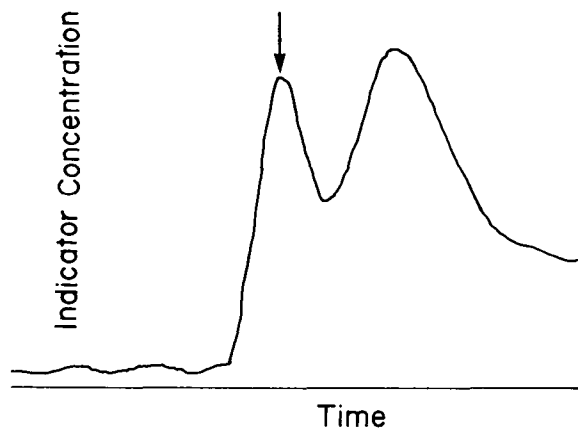


FIGURE 1. Dye dilution cardiac output curves obtained intraoperatively before (1a, top) and after (1b, bottom) correction of a previously undiagnosed patent foramen ovale. The arrow in Figure (1a) demonstrates the early appearance of dye which has passed through the right-to-left intracardiac shunt.

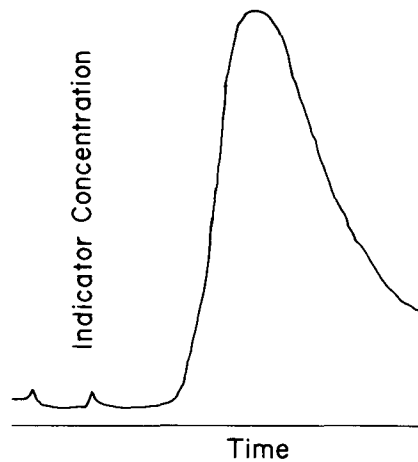
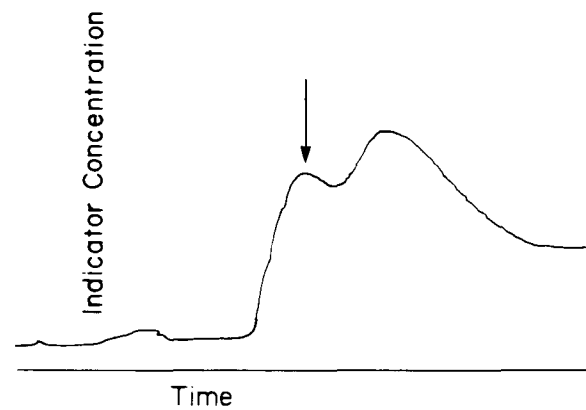


FIGURE 2. Dye dilution cardiac output curves obtained intraoperatively before (2a, top) and after (2b, bottom) correction of previously undiagnosed multiple atrial septal defects. The arrow in Figure (2a) demonstrates the early appearance of dye which has passed through the right-to-left intracardiac shunt.

dilution curve was obtained by injecting indocyanine green (1.25 mg) into the central venous catheter (right external jugular vein), and sampling blood from the radial arterial line. The dye curve demonstrated an intracardiac right-to-left shunt (Figure 1a). Bypass was reinstated and a patent foramen ovale was identified and closed. Post bypass the PaO₂ was 397 torr (FIO₂ = 1.0), and the dye dilution curve was normal (Figure 1b).

Case II: A 7 year-old 14-kg female had an atrial septal defect, ventricular septal defect, and pulmonary artery band. The preoperative left ventricular pressure was 90/10 mmHg, right ventricular pressure 100/10 mmHg, and pressure distal to the pulmonary artery band was 22/10 mmHg. The hemoglobin concentration was 15.1 gm/dl. The patient was anesthetized with halothane-nitrous oxide-oxygen and the PaO₂ was 92

torr with an (FIO₂ = 0.3). Closure of the atrial and ventricular septal defects plus pulmonary artery de-banding was uncomplicated. After bypass the initial PaO₂ was 67 torr (FIO₂ = 1.0), and decreased to 43 torr. Again, the lungs were clear and the endotracheal tube was positioned properly. A dye dilution curve which then was generated revealed an intracardiac right-to-left shunt (Figure 2a). When bypass was reinstated several 1-2 mm atrial septal defects were identified (at the junction of the right atrium and the inferior vena cava) and closed. The PaO₂ was 268 torr (FIO₂ = 1.0) when the post-repair dye dilution curve was generated (Figure 2b).

Clinicians have routinely used dye dilution for more than thirty years to identify intracardiac communications and to measure cardiac output in the cardiac catheterization laboratory.¹ In fact, some authors have

recommended its use on a routine basis after intracardiac repair.^{2,3} The method is based on the Fick principle, i.e. if a known amount of indicator is injected into the blood stream, and the concentration of indicator is determined distal to a mixing chamber, the amount of volume per unit time can be determined.

In practice, indocyanine green is injected into the central circulation, blood containing diluted dye is withdrawn from a peripheral artery and the dye curve is generated via a photodensitometer. Visual inspection of the dye curve can provide information concerning the presence of a right-to-left shunt (abnormal early peak, because some dye bypasses the pulmonary circulation, arriving early at the peripheral artery) and left-to-right shunt (lower peak and prolonged disappearance because some dye recirculates in the pulmonary vasculature).

Although the technique of thermodilution also accurately determines cardiac output in children,⁴ a thermodilution curve from a patient with a right-to-left shunt would have a normal configuration. The loss of some of the indicator (cold) as it bypasses the pulmonary circulation would not be recognized except that the calculation of cardiac output would yield an abnormally elevated value. In most instances, however, such an error might go undetected, and a large intracardiac shunt could be overlooked.

There have been recent reports describing the diagnosis of an intracardiac shunt postoperatively in the intensive care unit using dye dilution curves. The lesions have included patent foramen ovale associated with recent infarct, respiratory failure, pulmonary embolus, and following coronary artery bypass.^{5,6,7,8} Using this technique ventricular septal defect has been detected following repair for membranous subaortic stenosis.⁶ In each of these patients the dye dilution technique rapidly made the diagnosis of a right-to-left intracardiac shunt.

Many of these patients initially had been treated for presumed respiratory failure, receiving high concentrations of oxygen and positive and expiratory pressure.

However, oxygenation in patients with a right-to-left shunt does not improve with an increase in (FIO₂) and often becomes worse with application of positive end expiratory pressure. Thus, potentially harmful therapy could be avoided if dye dilution were used in the operating room to evaluate unexplained hypoxemia.

The two patients in this report emphasize the importance of early use of dye dilution in the recognition of residual congenital intracardiac defects. The thermodilution cardiac output technique using a pulmonary artery catheter is in wide use today, but it would not have been of diagnostic value in these cases. In Case I, a patent foramen ovale caused a right-to-left shunt when right atrial pressure exceeded left atrial pressure because of transient right ventricular failure following infundibular resection. Transient right ventricular failure again occurred in Case II, causing a right-to-left shunt through multiple unrecognized atrial septal defects. In both of these patients dye dilution allowed prompt intraoperative recognition, institution of cardiopulmonary bypass, and closure of residual defects.

References

1. Wood, E. H.: Diagnostic Applications Of Indicator Dilution Technics In Congenital Heart Disease. *Circulation Research*. **10**:531-568, 1962.
2. Hoffman, L. E., Krovetz, L. J., Van Mierop, L. H. S., Gessner, I. H., Wheat, M. W., Bartley, T. D., Schiebler, G. L.: Secundum Atrial Septal Defects In Children. *Annals of Thoracic Surgery*. **7**:104-109, 1969.
3. Morris, A. L., Donen, N.: Hypoxia And Intracardiac Right-To-Left Shunt. *Arch Internal Medicine*. **138**:1405-1406, 1978.
4. Morrow, A. G., Oldham, H. N., Callard, G. M., Braunwald, E.: The Assessment Of Operative Results In Congenital Heart Disease By Intraoperative Indicator Dilution Curves. *Circulation*. **33**:263-269, 1966.
5. Moorthy, S. S., Losasso, A. M., Gibbs, P. S.: Acquired Right-To-Left Intracardiac Shunts And Severe Hypoxemia. *Critical Care Medicine*. **6**:28-31, 1978.
6. Byrick, R. J., Kolton, M., Hart, J. T., Forbath, P. G.: Hypoxemia Following Cardio-Pulmonary Bypass. *Anesthesiology*. **53**:172-174, 1980.
7. Moorthy, S. S., Losasso, A. M.: Potency Of The Foramen Ovale In The Critically Ill Patient. *Anesthesiology*. **41**:405-407, 1974.
8. Alfieri, O., Subramanian, S.: Cardiac Output Determination In Infants And Small Children After Open Intracardiac Operations. *Annals of Thoracic Surgery*. **19**:322-326, 1975.