

Original Article

Extracorporeal Support with a Cadaver Liver as a Bridge to Transplantation

Lance W. Fristoe, BS, CCP, Jonathan H. Merrill, BSN, CCP, Jeff A. Kangas, BS, CCP, James E. Vogel, BS, CCT, Alfred H. Stammers, BS, CCP, Alan N. Langnas, DO, Ira J. Fox, MD, Byers W. Shaw Jr., MD

University of Nebraska Medical Center Division of Perfusion Sciences, Omaha, Nebraska and Betch, Inc.

Presented at the American Society of Extra-Corporeal Technology's 31st International Conference, February 26 - March 1, 1993, Dallas Texas

Keywords: centrifugal pump, hepatic encephalopathy, extracorporeal liver perfusion, liver transplantation

ABSTRACT

Extracorporeal liver perfusion (ECLP) has been used for detoxifying blood in patients in class IV hepatic encephalopathy. Palliation of the moribund patient utilizing extracorporeal devices with cross-circulation of a cadaver liver has been documented for over three decades. Common problems associated with this procedure which appear in the literature include cadaver liver distention, increased resistance to blood flow, and limited time of extracorporeal support due to cadaver liver failure. This report summarizes the experiences of the perfusion team in utilizing an extracorporeal circuit with an otherwise non-transplantable cadaveric liver, to support the decompensating hepatic patient as a bridge to transplantation.

Between January and July 1992, three patients were supported for hepatic failure with ECLP. Two patients were placed on ECLP with a modified circuit containing two positive displacement pumps and one centrifugal pump. The third patient was placed on ECLP with a circuit that contained two centrifugal pumps and one positive displacement pump. Patient age ranged from 6 to 38 years and length of support ranged from 24 to 72 hours. In all three patients, a centrifugal pump was placed in the suprahepatic inferior vena cava line to facilitate cadaver liver drainage and decompression. Intensive monitoring of both patient and cadaver liver hemodynamics, hepatic function, and hematological status was performed. All three patients were successfully weaned from ECLP. Two patients received successful orthotopic liver transplantation. The third died of complications unrelated to ECLP after support was discontinued. At present, the technique of ECLP has been shown to be an effective treatment for supporting the comatose patient with fulminant hepatic failure prior to transplantation.

Address correspondence to:

Lance W. Fristoe, BS, CCP

Division of Perfusion Sciences, University of Nebraska Medical Center

600 South 42nd Street

Omaha, NE 68198-5150

INTRODUCTION

Over the past three decades extracorporeal liver perfusion (ECLP) has been used as a therapeutic modality for the treatment of patients who have lapsed into coma while awaiting liver transplantation. (1-3) This technique of cross-circulating the patient with a cadaver liver has been performed, using various species of livers, as well as numerous designs in extracorporeal circuitry. (4-7) Pioneers of ECLP, in general, have had discouraging results, and the number of long term survivors is less than 20 percent. (1,8,9) In most cases, moribund patients have been selected for this treatment because of its potential for poor outcome. (10) Multiple cadaver liver complications have been documented following initiation of ECLP, increasing the inherent complexity and risk of the procedure. (11,12)

Frequent problems found in the past include cadaver liver distention, limited time of support due to cadaver liver failure, and "outflow block syndrome" leading to increased trans-hepatic vascular resistance. (11,12) Because of these complications, an ECLP circuit was designed to facilitate extracorporeal liver decompression utilizing a centrifugal pump^a in the suprahepatic inferior vena cava line. This aided not only in draining the cadaver liver, but also in returning blood to the patient. This paper describes the procedure of ECLP in three patients treated in the intensive care unit (ICU) with this technique.

MATERIALS AND METHODS

Between January and July 1992 three patients were placed on ECLP using human donor livers that had been rejected for transplantation because of a blood type incompatibility, long cold ischemic time, or an unacceptable pathological diagnosis. Upon arrival, these livers were taken to the operating room where a standard back table procedure was performed. (13) They were placed in a sterile basin which was set on a small sterilely draped table. The cadaver livers were cannulated and flushed with 500 ml of cold 5% albumin. The celiac artery was cannulated with an 18 french aortic cannula^b. Umbilical tape was used to tie the celiac artery around the cannula's sew ring. The portal vein was cannulated with a 3/8" x 3/8" straight polycarbonate connector^c. A tie band was used to secure the vessel around the connector with a banding gun. Multiple tie bands were applied, if excess vein was present or a leak was detected. The same technique was used to cannulate the suprahepatic vena cava, and the infrahepatic cava was ligated. The basin was filled with a sterile cold irrigation

solution containing 75,000 units of bacitracin and 750,000 units of polymyxin B sulfate. The liver was transported to the ICU with a sterile covering. The ECLP circuit was not attached to the cadaver liver until after transporting all items to the ICU.

The extracorporeal circuit for each case was customized using sterile technique in the operating suite to the specific needs of the patient. Each circuit contained the following basic components: cardiotomy reservoir^d, oxygenator^e, heat exchanger^f, CDI in-line blood gas monitor^g, and a pressure monitoring manifold^h.

Once a circuit was assembled, it was CO₂ flushed and primed with Plasma-Lyte A injection^h. After de-airing the entire circuit, the crystalloid prime was "chased" with packed red blood cells reconstituted with fresh frozen plasma, 3000 units of beef lung heparin, 25 grams of mannitol, and a calculated dose of albumin. (14) The circuit was then transported to ICU for cadaver liver attachment.

PATIENTS

Patient A was a sixteen year old, 70 kg female (BSA 1.82 m²), with non-A, non-B, non-C fulminant hepatic failure. An intracranial pressure monitor was placed and elevated pressures with cerebral edema were noted. Once diagnosed with class IV encephalopathy, ECLP was initiated with orthotopic liver transplantation occurring forty-nine hours later. (Figure 1)

Patient B was a six year old, 23 kg male (BSA 0.87 m²). He presented with Stevens-Johnson syndrome and massive hepatic necrosis which was believed to be secondary to phenobarbital administration. (15) Worsening cerebral edema with elevation of intracranial pressures was observed for several days prior to ECLP. Following seventy-two hours of successful support, the patient was discontinued from bypass. Despite adequate liver function, his neurological status had continued to deteriorate, and as a result he was no longer a candidate for transplantation. (Figure 2)

Patient C was a thirty-eight year old, 50 kg female (BSA 1.46 m²), who presented with acute non-A,B,C fulminant hepatic failure. In stage IV encephalopathic coma upon admission, she received ECLP for twenty-three hours prior to orthotopic liver transplantation. (Figure 3)

INITIATION

Once in the ICU the cadaver liver was connected to the circuit by the liver transplant surgeon. The hepatic artery and portal vein lines were connected to their respective cannulas and total hepatic flow was initiated at approximately 100 ml/min. The extracorporeal liver was allowed to fill and de-air by transfusing 600-800 ml of volume from the cardiotomy reservoir to the liver. Once perfusate was seen flowing from the suprahepatic vena cava connector, the outflow tract line was connected.

Isolated liver perfusion was then initiated, perfusing the portal vein with approximately 75% of the total hepatic flow. (16) While monitoring line pressures, one perfusionist increased the

- a Medtronic Bio-Medicus Inc., Eden Prairie MN 55344
- b Research Medical, Inc., Midvale UT 84047
- c Bentley Laboratories, Inc., Irvine CA 92714
- d orin Biomedical, Irvine CA 92714
- e AVECOR Cardiovascular Inc., Plymouth MN 55441
- f CDI, 3M Health Care, Tustin CA 92680
- g COBE Laboratories, Inc., Lakewood CO 80215
- h Baxter Health Care, Deerfield IL 60015

hepatic artery and portal vein blood flows, with a second perfusionist monitoring the cadaver liver and slowly increasing the hepatic decompression/patient reinfusion pump. Flows were steadily increased until the hepatic artery line pressure was 80 to 100 mmHg, and the portal vein line pressure was 10 mmHg. Occasionally, volume was added to maintain a full, but not distended extracorporeal liver. The color of the liver quickly turned from deep purple to bright red once perfusion was initiated.

The ECLP circuit was allowed to recirculate for a short period to enable the donor liver to warm to 37°C and become metabolically active. A sterile bowel bag¹ was then placed over the basin to help maintain sterility and minimize heat loss. Five minutes into reperfusion of the cadaver liver, a complete blood count, electrolytes, fibrinogen, total protein, and an arterial blood gas (ABG) were obtained.

Hyperkalemia was always anticipated due to inadequate removal of the University of Wisconsin preservative solution and/or cellular potassium leaching, which is commonly seen with ischemic tissues. Prior to initiating ECLP on patient B, the perfusionists performed hemofiltration during isolated liver perfusion to remove a cardioplegic concentration of extracellular potassium. Once the perfusate met specified parameters as stated in table 1, the circuit was ready for patient attachment.

The patient was then heparinized with 150 units/kg, in preparation for cannulation and cross-circulation with the cadaver liver. After documentation of an activated clotting time (ACT) greater than 250 seconds, the patient was cannulated in bilateral femoral veins using identical 15 french percutaneous cannulae. The circuit was then connected to the patient, and ECLP via veno-venous bypass was initiated slowly over several minutes until targeted blood flows and line pressures were achieved.

The exsanguination pump flow was increased at the same rate as the hepatic decompression/patient reinfusion pump was increased. Once the hepatic artery line pressure reached 100 mmHg, the portal vein blood flow was initiated. Further increases in the exsanguination and reinfusion pumps were proportional to the increases of the portal vein pump. In this manner, hepatic artery line pressure remained stable at 100 mmHg. The portal vein line pressures ranged from 10 to 50 mmHg. Should portal vein line pressures increase above 50 mmHg, the portal vein pump and the exsanguination/reinfusion pumps were decreased proportionally.

Optimal line pressures were achieved at total blood flows ranging between 1.5-2.0 ml/min/gm of cadaver liver tissue. If venous return was limited due to hypovolemia additional blood was added to the circuit enabling blood flows to be increased. It was our experience that the extracorporeal liver required blood flows which at times could produce high end-range line pressures. These blood flows were necessary to adequately meet the

Table 1

Pre- and intra-ECLP perfusate parameter ranges.

Na: sodium, K: potassium, Cl: chloride, Ca: calcium, BUN: blood urea nitrogen, ABG: arterial blood gas, Hgb: hemoglobin.

Parameter	Maintenance range	Sampling Frequency
hematocrit	> 28%	two hours
platelet	100-200 x 10E3/mcl	two hours
total protein	6-8 gm/dl	two hours
fibrinogen	150-450 mg/dl	two hours
Electrolytes	Na 130-140 mEq/l	two hours
	K 3.5-4.7 mEq/l	two hours
	Cl 95-110 mEq/l	two hours
bicarbonate	18-23 mEq/l	two hours
ionized Ca	1.15-1.35 mEq/l	two hours
serum osmolality	> 320 mOsm/l	two hours
BUN	5-22 mg/dl	two hours
creatinine	0.6-1.1 mg/dl	two hours
prehepatic ABG	pO ₂ > 100 mmHg	continuous
plasma free Hgb	< 15 mg/dl	four hours

Table 2

Parameters monitored during ECLP.

CVP: central venous pressure, ACT: activated clotting time.

Parameter Monitored	Monitoring Frequency
mean art pressure	continuous
CVP	continuous
intracranial pressures	continuous
cerebral perf. pressure	continuous
ACT	20 minutes
theophylline clearance	hourly
cadaver liver O ₂ consumption	hourly
cadaver liver bile production	two hours
total bilirubin	two hours
arterial ammonia	two hours

metabolic requirements of the liver.

MONITORING

Once ECLP blood flow parameters had been optimized and patient volume requirements met, many parameters were monitored by the perfusionist and/or ICU nurses. (Tables 1 and 2) The frequency of these lab tests was increased, if values were out of range, or when patient parameters reflected a potential problem with the ECLP circuitry.

Anticoagulation management of the patient was by continuous heparin infusion with activated clotting times obtained every twenty minutes. The heparin infusion rate was frequently adjusted and occasional heparin boluses given. The patient's

i Med-Surg Division, 3M Health Care, St. Paul MN 55144

Figure 1
Diagram of circuit used for patient A.

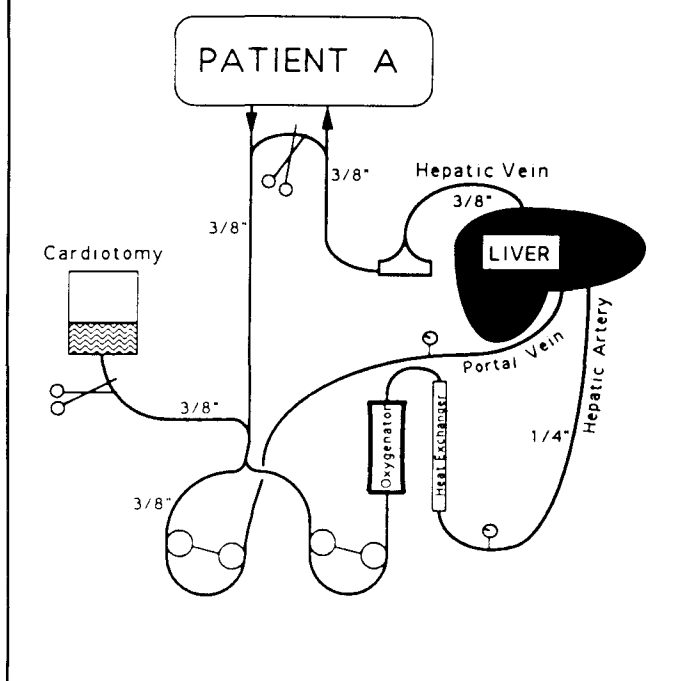
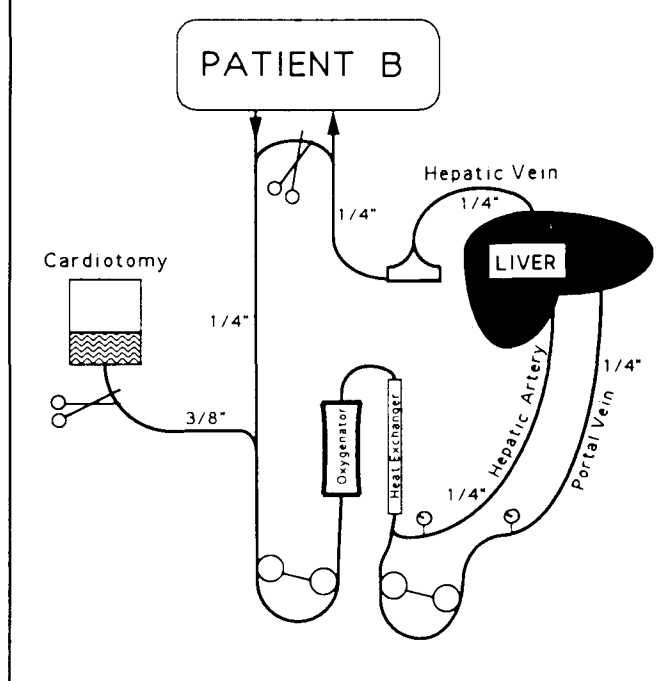


Figure 2
Diagram of circuit used for patient B.



central lines were used for administering platelets and vasoactive drugs. All other fluids were administered through the ECLP circuit.

Two registered nurses remained at the patient's bedside at all times, and were available to assist the perfusionist in monitoring the patient's vital signs, retrieving blood products, recording hourly intake and output of the ECLP, and performing numerous ancillary tasks. The perfusion record was generated by the attending perfusionist and included transfusion and medication additions, blood flow rates, line pressures, blender ventilation settings, ACTs, and blood gas results.

Through the course of ECLP, blood from the cannulation sites, and ascitic fluid which had seeped through the hepatic capsule, accumulated in the sterile liver basin. Removal of this fluid from the basin was achieved by gravity siphon, using a 1/4" sterile drain line which was placed in the basin prior to initiation of ECLP. One end was coiled in the bottom of the sterile basin, while the other end was connected to a collection canister on the floor beside the table. Occasionally vacuum was applied to the canister to clear the drain line of accumulated clots to restore the siphon. The nearly empty basin was then replenished with a warm antibiotic irrigation which allowed the liver to "float," thus preventing pressure necrosis and cannulae kinks.

Due to the "normal" blood loss seen with the ECLP, blood products were stored at the patient's bedside. Four units of packed red blood cells, two units of fresh frozen plasma, and six units of platelets were always readily available. A perfusion supply cart containing various crystalloids, colloids, drugs, and

safety backup equipment remained nearby. The entire ECLP circuit could be reconstructed at the bedside, if necessary.

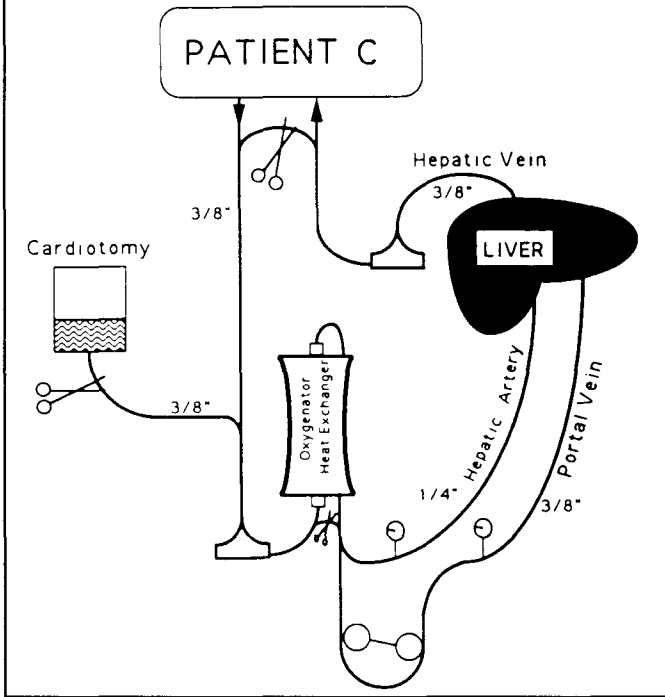
Per perfusion protocol, standing physician orders were signed by the attending liver transplant surgeon. Under these orders, the perfusionists, who were now outside the operating suite, could order lab tests, order and administer blood products, and make volume and blood flow changes per the discretion of the attending perfusion technologist. Following the initial stabilization period of ECLP, which required two perfusionists, one perfusionist remained at the bedside thereafter, with a second perfusionist in house.

RESULTS

ECLP demonstrates that ex-vivo livers are capable of detoxifying blood in near-death patients experiencing class IV encephalopathy secondary to acute fulminant hepatic failure. Encephalopathic symptoms were reversed in patients A and C, who later received orthotopic liver transplantation. Patient B never improved neurologically and expired seven days after discontinuation of ECLP. All three perfusions were considered successful based on detoxification data (Figures 4, 5 and 6) and theophylline clearance tests.

In the past, cadaver hepatic function during ECLP has been assessed through the monitoring of various parameters: patient elevation of blood urea nitrogen (BUN) with reduction of blood ammonia, excretion of sulfobromophthalein dye in the bile, and galactose elimination capacity tests. (1,7,9)

Figure 3
Diagram of circuit used for patient C.



The cytochrome P-450 enzyme system is known for its ability to catalyze the metabolism of theophylline. Cytochrome P-450, located in the hepatocytes, is responsible for many drug oxidations. Hepatic disease frequently alters functional hepatocytes rendering them incapable of metabolizing drugs dependent on Cytochrome P-450. (17) Patients B and C received theophylline during ECLP. The theophylline half-life was predicted for each patient and levels were analyzed hourly. During ECLP, both patients metabolized theophylline at normal or slightly elevated rates. Heparin was also metabolized at normal rates once ECLP was initiated. Following discontinuation of ECLP, the theophylline levels remained constant without further metabolism, and the heparin was neutralized with protamine.

Bile was produced consistently throughout all three perfusions. Initially, the bile was a golden color which progressively turned black. Gastroenterologist assumed bilirubin was responsible for this color change, although the bile was never analyzed for bilirubin content.

Prior to ECLP, each patient was observed to have a sub-normal BUN with toxic blood ammonia levels. Once ECLP had been initiated the BUN rose in response to the metabolism of blood ammonia by the cadaver liver, and the blood ammonia and total bilirubin levels fell sharply, reversing the hepatic coma in patients A and C. (Figures 4, 5 and 6)

Improved neurological function was observed within the first twelve hours following the initiation of ECLP in patients A and C. They regained consciousness and behaved in a manner which was considered to be "normal" for a post-transplant

Figure 4
Ammonia levels during ECLP.

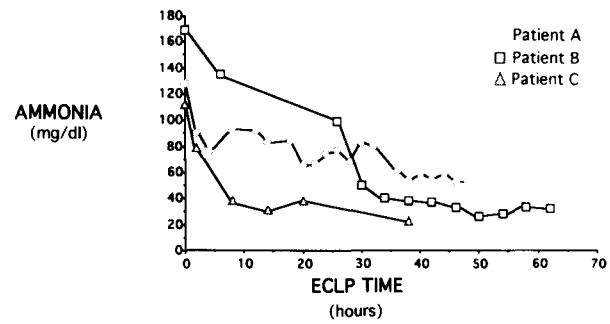


Figure 5
BUN levels during ECLP.

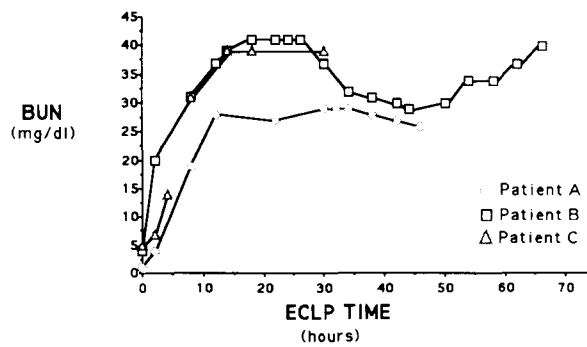
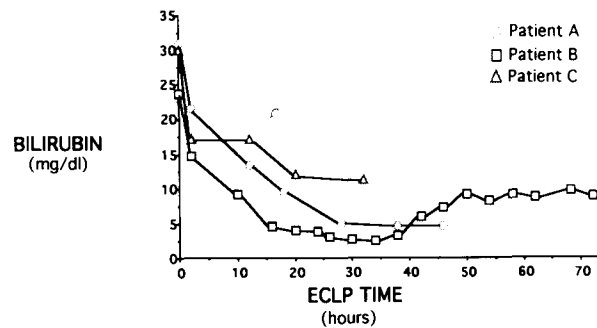


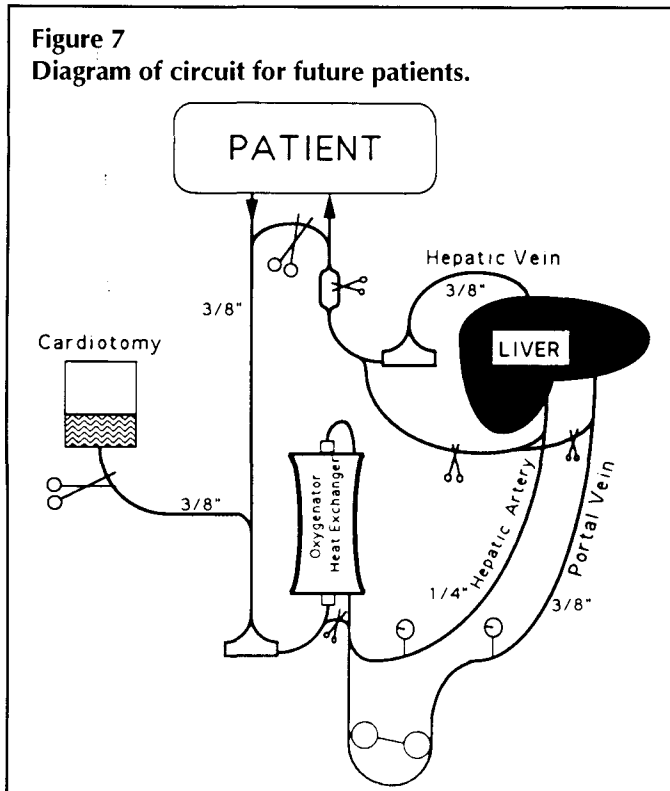
Figure 6
Total bilirubin levels during ECLP.



patient. Once the hepatic encephalopathy was documented to be reversible, the patient was placed at the highest priority for transplantation.

The oxygen consumption of the extracorporeal liver remained relatively constant (60 to 80 ml/min) throughout the

Figure 7
Diagram of circuit for future patients.



procedure. Currently, there is not enough data, either referenced or directly measured during these three ECLPs, to determine what an optimal oxygen delivery rate should be for a liver functioning outside of the body. However it was our experience that suprahepatic venous saturations of seventy percent were achieved when both the hepatic artery and the portal vein were perfused with fully oxygenated blood at hepatic flow rates between 1.5 and 2.0 ml/min/gm of cadaver liver tissue.

Few signs of donor liver failure were encountered, although many are common in the literature. (4,11,12) "Outflow block syndrome" or an increase in trans-hepatic vascular resistance was observed with each patient as described by these investigators. However, this was found to be progressive in nature and usually required up to twenty-four hours to occur. Reductions in blood flows were required to prevent donor liver engorgement and portal hypertension. Hepatic artery and portal vein line pressures were allowed to rise to maximum mean pressures of 150 mmHg and 55 mmHg, respectively. When outflow block syndrome occurred, blood flows were decreased to prevent donor liver hypertension. A decrease in donor liver oxygen consumption, hepatic function, or in the base excess was not observed. However, it was anticipated that another donor liver would be required to continue ECLP, and modifications for future circuits have been made to facilitate emergent cadaver liver change out (Figure 7). Suitable donor livers were obtained during this "low-flow high-pressure" period, with orthotopic liver transplantation occurring shortly thereafter.

DISCUSSION

Variations in ECLP for these three patients demonstrate an evolution in basic circuit design and operation. As experience was gained in the operation of the ECLP, selection of circuit components and hardware varied. With the completion of each procedure, data concerning the donor liver's metabolic requirements, and detoxifying abilities were generated. This greatly enhanced the perfusionists' abilities to construct safer, more efficient, and easier to manage circuits for future patients.

Initially, the decompression/patient re-infusion pump was placed in the circuit as a safety device only to be used if cadaver liver distention was encountered. However, upon initiation of ECLP the cadaver liver became engorged and distended, and the hepatic decompression/patient reinfusion pump was activated. Without the use of this device, the attempt at supporting these patients would have been greatly impaired.

Data from patient A, suggested that the portal vein, as well as the hepatic artery should be perfused with oxygenated blood. When only the hepatic artery was perfused with oxygenated blood (patient A), the donor liver suprahepatic oxyhemoglobin saturation was unacceptably low (30-40%). It was felt that the reinfusion of heavily desaturated venous blood to a patient who may already be in respiratory difficulty could prove to be deleterious, if not life threatening. This technique of oxygenating both the hepatic artery and portal vein greatly improved the suprahepatic venous oxygen and carbon dioxide concentrations when performed (patient B).

In the past roller pumps have been used for exsanguinating patients for ECLP. (2,3,5) This allowed for blood flow control very similar to that used in the management of extracorporeal membrane oxygenation (ECMO). However, the extracorporeal liver requires significantly higher oxygen delivery rates than those typically used in neonatal ECMO. As experience was gained with patient B, it became evident that a centrifugal exsanguination pump would be more efficient and safer than a roller pump. The centrifugal pump would be inflow sensitive to volume changes within the patient's body and to transient manipulations of the venous drainage cannula. The exsanguination line was monitored for cavitation which frequently occurred using the roller pump. The optimal rate of exsanguination was not attainable in patient B due to his small size and blood volume. This caused suboptimal total hepatic flow and reduced the amount of oxygen delivered to the donor liver.

We believe this ECLP system has advantages over circuits used in the past. The use of veno-venous bypass permits an efficient regulation of central venous and arterial blood pressures, and does not rely on patient cardiac function for perfusion or respiratory function for oxygenation. In addition, it has been hypothesized, but has not been our experience that patients experiencing respiratory distress might possibly be managed by the inclusion of an oxygenator distal to the hepatic decompression/patient reinfusion pump. An oxygenator placed within the ECLP in this position could be utilized for extracorporeal carbon-

dioxide removal or veno-venous ECMO should the need arise. Adaptations to the ECLP now include a diamond bridge in the patient reinfusion line for inclusion of an oxygenator without discontinuation of bypass. Further study on the feasibility of this treatment modality should be done.

CONCLUSION

The results of this report are more encouraging than those of other investigators. Data suggest that the clinical application of ECLP is meritorious and deserves further work and study. Although the number of procedures to date have been limited, the preliminary results appear promising. Further evolution of the ECLP circuitry design and management will likely occur. Future plans include developing a servo-regulated ECLP system and neonatal/pediatric ECLP, and studying the feasibility of long term ECLP support.

At the time of this investigation, therapeutic modalities for the moribund patient in class IV or V hepatic encephalopathy have been only palliative in nature, with liver transplantation being the only viable long term treatment. The utilization of an ECLP system has been demonstrated to be useful as a bridge to transplantation, providing the time needed for procurement of a transplantable liver.

REFERENCES

1. Ranek L, Iversen HR, Hilden M, et al. Pig liver perfusion in the treatment of acute hepatic failure. *Scand J Gastroent.* 1971;Suppl.9:161-69.
2. Fernandez-Bueno C. Development of an extracorporeal liver support system: initial results. *Milit Med.* 1992;157:180-82.
3. Tung LC. Extracorporeal liver perfusion in the treatment of acute hepatic failure. *Artific Organs.* 1980;4:291-96.
4. Abouna GM, Ashcroft T, Muckle TJ, et al. Heterologous extracorporeal hepatic support: haemodynamic, biochemical, and immunological observations. *Brit J Surg.* 1970;57:213-20.
5. Mrus JM, Chao RYN, Chao SHY, Andrews WS, Eberhart RC. An extracorporeal perfusion system to bridge pediatric liver transplant candidates. *ASAIO-Trans.* 1990;36:M603-M605.
6. Eiseman B, Knipe P, McColl HA, Orloff MJ. Isolated liver perfusion for reducing blood ammonia. *Arch of Surg.* 1961;83:44-51.
7. Otto JJ, Pender JC, Cleary JH, Sensenig DM, Welch CS. The use of a donor liver in experimental animals with elevated blood ammonia. *Surg.* 1958;43:301-9.
8. Eiseman B, Velasquez A. Extracorporeal and auxiliary liver support. In: Hardy JD, ed. *Human Organ Support and Replacement.* Springfield: Charles C. Thomas;1971;100-10.
9. Ham JM, Pirola RC, Davidson GM, Yarrow S, Elmslie RG. Pig liver perfusion for the treatment of acute hepatic coma. *Surg Gynecol and Obstet.* 1968;Sept:543-49.
10. Eiseman B, Liem DS, Raffucci F. Heterologous liver perfusion in treatment of hepatic failure. *Ann Surg.* 1965;162:329-45.
11. Aubunda GM, Ashcroft T, Young JR. Trans-Hepatic vascular resistance during prolonged isolated liver perfusions. *Brit J Surg.* 1969;56:921-25.
12. Eiseman B, Knipe P, Koh Y, Normell L, Spencer FC. Factors affecting hepatic vascular resistance in the perfused liver. *Ann Surg.* 1963;157:532-47.
13. Shaw BW, Jr. Starting a liver transplant program. *Sem Liv Dis.* 1989;9:159-67.
14. Beshere GA, Camerlengo LJ, Dearing JP. Estimation of colloid osmotic pressure during hemodilutional cardiopulmonary bypass. *J Extra-Corpor Technol.* 1982;14:381-84.
15. Weston WL, Brice SL. Erythema multiforme minor in children. *Pediatr.* 1991;18:188-94.
16. Meyers WC. The liver. In: Sabiston DC, ed. *Textbook of Surgery.* Philadelphia: W.B. Saunders Company; 1986:1053-68.
17. Clark WG, Brater DC, Johnson AR. *Goth's medical pharmacology.* St. Louis: The C.V. Mosby Company; 1988:69-79.