

Case Report

Surgical Removal of a Left Atrial Myxoma Utilizing Cardiopulmonary Bypass

Paul Kerins, BS, RRT, CCP, Roger A Vertrees, BA, CCP, Louis Brownstein, BA, CCP, Richard L. Weiss, MD, Anthony J. DelRossi, MD

Department of Surgery and the School of Cardiovascular Perfusion, Cooper Hospital/University Medical Center, UMDNJ-Robert Wood Johnson Medical School at Camden, Camden, New Jersey

Keywords: atrial myxoma, cardiopulmonary bypass, cardiac tumor

ABSTRACT

An atrial myxoma is a benign intracavitary tumor of the heart. Clinical manifestations of the myxoma depend upon the location within the heart and the degree of obstruction to blood flow. This case report presents a patient who displayed all the clinical symptomology of mitral valve dysfunction, due to the presence of a left atrial myxoma. The diagnosis and subsequent surgical removal of the tumor, utilizing cardiopulmonary bypass, are the subject of this report.

Address all correspondence to:
Louis Brownstein, BA, CCP
Program Director
School of Cardiovascular Perfusion
Cooper Hospital/University Medical Center
310 Sarah Cooper Building, Camden, NJ 08103

INTRODUCTION

Atrial myxoma, a benign tumor of the heart, represents approximately half of all reported cardiac tumors (1). While treatment depends upon the clinical manifestations associated with the tumor and its intracavitary location within the heart, the majority of patients undergo surgical removal of the lesion. This case report presents a patient with a left atrial myxoma, causing symptomatology of mitral valve disease. The myxoma was clearly visualized by intraoperative transesophageal echocardiography (TEE). We demonstrated in a series of photographs the movement of the tumor throughout the cardiac cycle. The successful surgical removal of this atrial myxoma utilizing cardiopulmonary bypass is discussed.

CASE REPORT

A 54 year old Hispanic male presented with a recent history of dyspnea on exertion and substernal chest pain which was relieved by sublingual nitroglycerin. A diastolic murmur was discovered upon physical examination. Subsequent preoperative cardiac catheterization revealed a large left atrial myxoma and a 70 percent stenosis of the left anterior descending coronary artery (LAD). The left ventricular ejection fraction was normal. Chest radiography findings were consistent with moderate congestive heart failure (CHF). Preoperative medications included furosemide (40mg) and sublingual nitroglycerin. A surgical procedure, employing cardiopulmonary bypass, was planned for the removal of the myxoma and an aorto-coronary bypass.

The cardiopulmonary bypass circuit was prepared utilizing a membrane oxygenator^a, blood cardioplegia system^b, 40 micron arterial filter^c, roller blood pump with 1/2-inch diameter tubing^d, and a 3/8-inch diameter arterial and 1/2-inch diameter venous line in a custom tubing circuit^e. Separate cannulation of the superior and inferior vena cava would allow the perfusionist to continue cardiopulmonary bypass during the opening of the right atrium. The perfusion circuit was primed with 1850 ml of Ringers solution, 150 ml normal serum albumin

(25%), 12.5 g of mannitol, 50 mEq of sodium bicarbonate, and 10,000 units of heparin.

Intraoperative transesophageal echocardiogram was performed using a monoplane 5 Mhz TEE probe^f to assist in identification of the site of the tumor attachment, and for planning the surgical approach.

Figures 1 through 4 indicate the position of the myxoma in the left atrium and its movement through the mitral valve during the cardiac cycle. The echocardiogram photographs reveal the obstructive nature of the myxoma.

It is the mitral valve obstruction, as seen in this patient, that produces symptoms. In Figure 1, systole, the mitral valve is closed (MV) and the myxoma (T) is contained within the left atrium (LA). Figure 2, end systole, occurs at the completion of the ventricular ejection. During this stage, blood is filling the left atrium and forcing the myxoma into the mitral annulus. In Figure 3, atrial systole is seen as the blood passes through the open atrio-

Figure 1: Ventricular ejection. The left atrial mass (T) resides within left atrium (LA). The mitral valve (MV) is closed. Left ventricle (LV), right atrium (RA), right ventricle (RV)

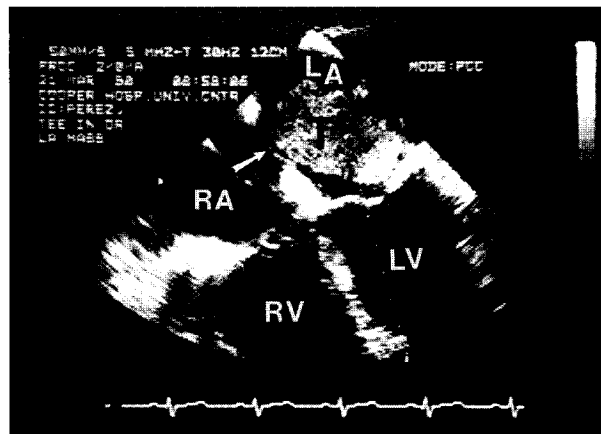
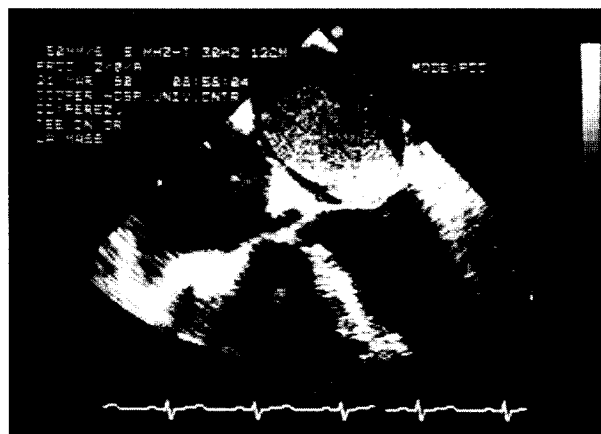


Figure 2: End systole. Aortic valve is closed, the left atrium (LA) enlarges as it becomes filled with blood. This allows the myxoma (T) to traverse the valve annulus. Note that the ventricular chambers appear to be small and the atrial chambers larger than in the previous photograph.



a Excell, Cobe Cardiovascular Inc., Arvada, CO
 b BCD+4, Sorin Biomedical, Irvine, CA
 c Bard Cardiopulmonary Div., Haverhill, MA
 d Cobe Cardiovascular Inc., Arvada, CO
 e Electromedics, Inc., Englewood, CO
 f Hewlett Packard, Paramus, NJ

ventricular valves. It is apparent in Figure 3 that mitral valve inflow is reduced by the presence of the myxoma, as it is forced into the ventricle by the blood flow. Figure 4 shows the myxoma retreating into the left atrium, with the mitral valve still open.

The surgical procedure consisted of grafting the left internal mammary artery to the LAD and excision of the left atrial myxoma. Upon opening the left atrium, a 3 X 8cm pedicled tumor was identified. The tumor had an hourglass shape, narrowed at its midposition where it had been compressed as it migrated through the mitral orifice. (see Figure 5). The pedicle attached to the atrial septum at the inferior border of the fossa ovalis. The mitral valve was slightly thickened, but with normal mobility. The right atrium was opened to facilitate exposure of the septum. A portion of the atrial septum, which appeared normal, was removed along with the myxoma. Following the anastomosis of the left internal mammary artery to the left anterior descending artery, the left and right atriotomies were repaired. A pericardial patch, approxi-

mately 2 centimeters in diameter, was sewn in place to repair the opening in the atrial septum. The surgeon instructed the anesthesiologist to inflate the lungs as the perfusionist decreased the flow from the left ventricular vent. As blood then filled the left atrium and ventricle, sutures were tightened on the patch as the air was evacuated from the left atrium. The superior and inferior vena caval tapes were slowly released, allowing blood to fill the right heart and displace any air as the right atriotomy was sutured closed. Prior to discontinuing cardiopulmonary bypass, the left ventricular vent was removed. Remaining air was evacuated from the left ventricle by insertion of a fourteen gauge needle into the left ventricular apex. The aortic cross clamp was removed and, when rewarming was completed, the patient was successfully weaned from bypass.

During cardiopulmonary bypass, activated clotting times (ACTs) were maintained between 550-850 seconds, alpha-stat blood gas management was adopted, and blood flows were

maintained between 50-70 ml/Kg/min in a non-pulsatile mode. Mild hypothermia and moderate hemodilution were employed maintaining a hematocrit of 24 percent. No blood products were administered while on bypass. Heparin was reversed with protamine sulfate. The patient tolerated the procedure well, and the post-operative course was uneventful. The patient was discharged the seventh postoperative day.

DISCUSSION

Myxomas are most likely to appear in persons between the ages of 30 and 60 years, occurring more frequently in women than in men (2). Familial occurrences of myxomas are also reported (1,3,4). Although historically benign, some myxomas have the ability to metastasize to areas such as the brain or bone (5). The usual site of attachment of an atrial myxoma is in the area of the fossa ovalis, though some have been found in the posterior wall of the atrium. The left side of the heart is three to four times more frequently involved (6,7).

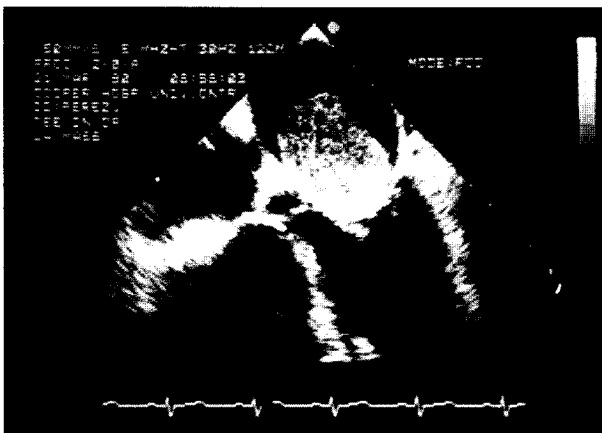
Primary tumors of the heart are uncommon. Approximately 30 to 50 percent of the observed cases are myxomas and over 90 percent of those occur in the atria (8).

The clinical signs and symptoms produced by intracavitary myxomas are constitutional and may depend upon whether the right or left side of the heart is involved. When located in the right side, these intracavitary tumors can produce the clinical picture of right ventricular failure, including venous distention with hepatic enlargement, ascites, and edema (9,10).

Figure 3: End diastole (presystole) or atrial systole. Blood is being pumped from the atria into the ventricles, causing a migration of the myxoma. The tumor resides in the mitral valve opening obstructing ventricular filling. Note: Mitral and tricuspid valves are open, aortic and pulmonic valves are closed.

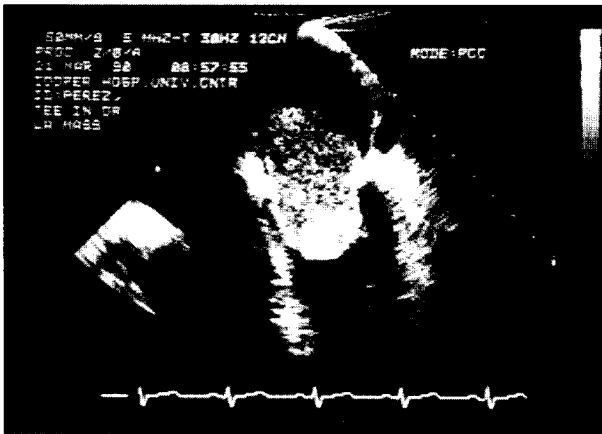

Figure 4: Early systole, rapid ejection phase. Atrio-ventricular valves closing (tricuspid closed). Mitral is closing, partial obstruction remains. Aortic valve open.



When located in the left side of the heart, they may produce symptoms which mimic mitral or aortic valve disease, including progressive dyspnea, substernal pain, orthopnea, and palpitation. Myxomas can be confused with mitral stenosis since both conditions may produce diastolic murmurs because of obstruction of the mitral valve. Additionally, a third heart sound has often been confused with an opening snap of mitral stenosis. Occasionally, symptom variations are manifested with change in position.

The physical signs produced by a left atrial myxoma depend on the size and location of the tumor and the degree of valvular obstruction produced. They may occur intermittently due to the ball valve-like action of the tumor. Histories of emboli to cerebral, mesenteric, renal and peripheral arteries, and sudden collapse followed by immediate and spontaneous recovery are not uncommon.

Surgical excision utilizing cardiopulmonary bypass is the accepted method of treatment of the left atrial myxoma, and is usually a curative treatment (11). Arrhythmias, although rare, have been observed in the late postoperative period (12,13). They are usually supraventricular in nature and most likely result from damage to the conduction pathways during resection of the tumor.

Atrial myxoma is a cardiac lesion that can be corrected surgically utilizing cardiopulmonary bypass. It is interesting for the perfusionist to appreciate the symptomatology associated with its diagnosis. In this case, visualization of the tumor in motion serves as an explicit demonstration of a myxoma inducing functional mitral valve disease. The use of transesophageal echocardiography after closure of the atrium allows the surgeon to determine visually if removal of the tumor has eliminated the source of the dysfunction.

REFERENCES

1. Hurst JW, Logue BR. *The Heart: Tumors of the Heart*. 2nd ed. New York: McGraw-Hill, Inc. 1970; 1278-1280.
2. Melo J, Ahmad AM, Chapman R, et al. Primary tumors of the heart: a rewarding challenge. *Am Surg*. 1979; 45(11): 681-3.
3. Powers JC, Falkoff M, Heinle RA, et al. Familial cardiac myxoma: emphasis on unusual clinical manifestations. *J Thorac Cardiovasc Surg*. 1979; 777-782.
4. Siltanen P, Tuuteri L, Norio R, et al. Atrial myxoma in a family. *Am J Cardiol*. 1976; 38(2):252-6.
5. Silverman J, Olwin JS, Graettinger JS. Cardiac myxomas with systemic embolization. Review of the literature and report of a case. *Circulation*. 1962; 26:99-103.
6. Bulkey BH, Hutchins GM. Atrial myxomas: a fifty year review. *Am Heart J*. 1979; 9 (5):639-43.
7. McAllister HA, Jr. Primary tumors of the heart and pericardium. *Pathol Annu*, 1979; 14 Pt 2:325-55.
8. Norman JC. *Cardiac Surgery. Tumors of the Heart*, 2nd ed. New York: Appleton-Century-Crofts. 1972; 488-491.
9. Waxler EB, Kawai N, Kasparian H. Right atrial myxoma: echocardiographic, phonocardiographic and hemodynamic signs. *Am Heart J*. 1972; 83(2):251-7.
10. Massumi R. Bedside diagnosis of right heart myxomas through detection of palpable tumor shocks and audible plops. *Am Heart J*. 1983; 105(2): 303-10.
11. Bortolotti U, Maraglino G, Rubino M, et al. Surgical excision of intracardiac myxomas: a 20-year follow-up. *Ann Thorac Surg*. 1990; 49(3):449-53.
12. Bateman TM, Gray RJ, Chauk A, Czer LS, Matloff JM. Arrhythmias and conduction disturbances following cardiac operation for the removal of left atrial myxomas. *J Thorac Cardiovasc Surg*. 1983; 86(4):601-7
13. Hanson EC, Gill CC, Razavi M, Loop FD. The surgical treatment of atrial myxomas. Clinical experience and late results in 33 patients. *J Thorac Cardiovasc Surg*. 1985; 89(2): 298-303.

Figure 5: The excised left atrial myxoma. Note the pedicle or point of attachment and narrowed "waist" produced by tumor's migration through and compression by mitral annulus.

