

**Case Report**

***Successful Support of the Right Ventricle Following Orthotopic Heart Transplantation Using the Abiomed BVS 5000 System: A Case Report***

Louis E. Samuels, MD; Sameer Sharma, BA; Verdi J. DiSesa, MD; Rohinton J. Morris, MD; M.L. Ray Kuretu, MD; Susan C. Brozena, MD; Jane M. Fitzpatrick, MD

Allegheny University Hospitals, Center City and East Falls, Philadelphia, PA

Keywords: right ventricular assist device, Abiomed BVS 5000 System, orthotopic heart transplantation

**ABSTRACT**

Acute right ventricular failure following orthotopic heart transplantation can occur in patients with elevated pulmonary artery pressure with high pulmonary vascular resistance. The result can lead to graft dysfunction and patient death if not managed aggressively. Successful restoration of cardiac hemodynamics was observed with reduction in pulmonary artery pressure and central venous pressure following right ventricular assist device placement. We describe the successful support of the right ventricle following orthotopic heart transplantation using the pneumatically driven Abiomed BVS 5000 system.

Address correspondence to:  
Louis E. Samuels, MD  
Allegheny University Hospitals, Center City  
Broad and Vine Streets, MS 111  
Philadelphia, PA 19102-1192

## INTRODUCTION

The relationship between pulmonary vascular resistance (PVR) and the risk of heart transplantation has been well described (1). Fixed elevated pulmonary vascular resistance is a major contraindication to orthotopic heart transplantation (OHT) (2). Pulmonary hypertension with reactive PVR, on the other hand, is not (3,4). Nevertheless, patients in the latter category can develop right ventricular failure as a result of this condition (5), and require prompt intervention before graft dysfunction becomes irreversible.

We present a patient with end-stage ischemic cardiomyopathy with pulmonary hypertension who underwent OHT followed by acute right ventricular failure. The patient was supported with the pneumatically driven Abiomed BVS 5000 right ventricular assist device (RVAD) for one week, after which the device was removed successfully. The patient was discharged from the hospital 16 days later. This case represents the successful support of the right ventricle following OHT using the Abiomed BVS 5000 system.

## CASE REPORT

A 49 year old male computer technician with a history of coronary artery disease and myocardial infarction in 1989 arrived at the hospital in November 1994 with severe biventricular failure. There was no other significant medical or surgical history. On physical examination, jugular venous distention, bibasilar rales, gallop rhythm, hepatomegaly, and pedal edema were present. The patient was admitted to the heart failure and transplant service. Right heart catheterization was performed with the following results:

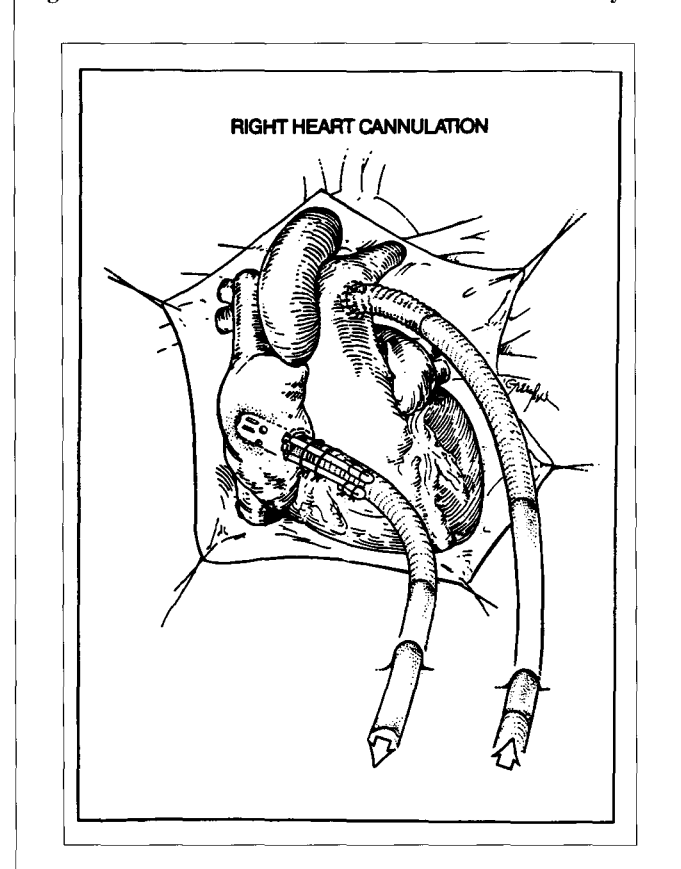
RA	20mmHg
PAP	76/33mmHg
PCWP	30mmHg
CI	1.1 L/min/m <sup>2</sup>

The patient was placed on intravenous dobutamine, sodium nitroprusside, and bumetanide, and was listed as status I for OHT. On December 1, 1994, the patient underwent OHT. The total ischemic time was less than three hours, and no technical problems occurred during the harvest or implantation. Following removal of the aortic cross clamp and discontinuation of cardiopulmonary bypass (CPB), restoration of cardiac function with satisfactory hemodynamics was observed. Approximately one hour later, the central venous pressure (CVP) rose from 14mmHg to 23mmHg, and the mixed venous saturation dropped from 70% to 38%. The right ventricle appeared distended, while the left ventricle remained vigorous. Pharmacologic intervention with epinephrine, dobutamine, and amrinone failed to alleviate the situation. The addition of an intra-aortic balloon pump (IABP) was also unsuccessful. An Abiomed BVS 5000 RVAD<sup>a</sup> was

placed with inflow from the right atrium and outflow to the pulmonary artery. Two 46 French wire-reinforced PVC cannulae were used. A lighthouse tip atrial cannula was inserted 3cm into the right atrial appendage and secured with two Prolene purse strings and tourniquets. The PA cannula, with its 14mm Dacron end, was beveled to accommodate an end-to-side anastomosis (Figure 1). The internal cannulae were connected to the external tubings, which were brought out of the body through separate stab wounds. With the circuit complete, the pump was positioned at the bedside and programmed with the console (Figure 2). Following application of the device, the CVP dropped to 14mmHg and the mixed venous oxygen (MVO<sub>2</sub>) saturation rose to 70%. The RVAD flow was 5.5 l/min. Heparinization was completely reversed with protamine. In the Intensive Care Unit, the CVP was 8mmHg, PAD was 25mmHg, and the MVO<sub>2</sub> saturation was 76% on dopamine at 3mcg/kg/min, epinephrine at 1.5mcg/min, and dobutamine at 5mcg/kg/min. Over the next two days, the inotropes were reduced, and the IABP was removed. The RVAD was maintained at a flow rate of 5.5 l/min. Anticoagulation was adjusted to keep the ACT between 180 and 200 seconds. On the third postoperative day, the flow rate was reduced to 4.5 l/min. On the fourth postoperative day, the flow

a Abiomed, Danvers, MA

Figure 1: Cannulations sites for the Abiomed BVS 5000 System



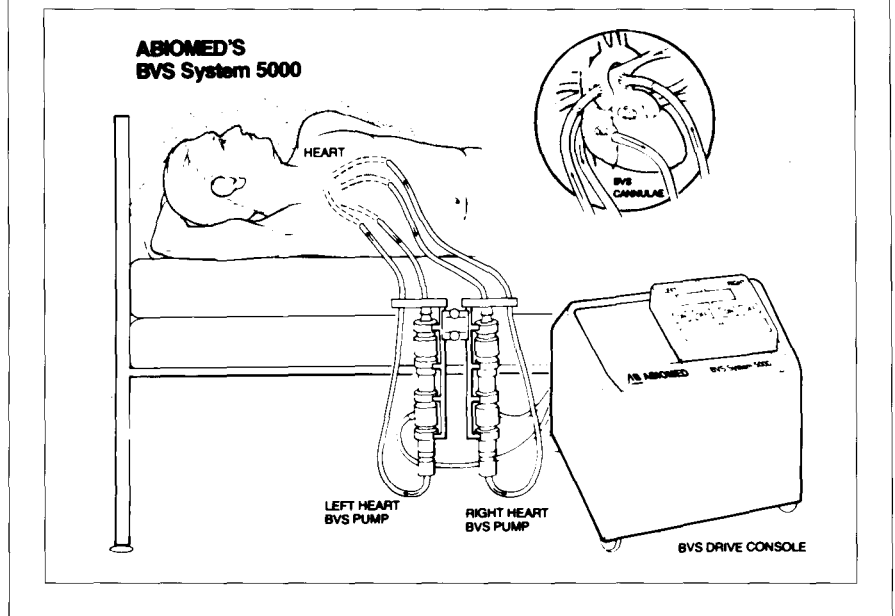
rate was reduced to 3.5 l/min. Little change was noted in the CVP and PAD. A transesophageal echocardiogram (TEE) showed moderate dysfunction of the right ventricle with preservation of left ventricular function. On the fifth postoperative day, the flow rate was decreased to 2.5 l/min. At this flow rate, the anticoagulation was adjusted to keep the ACT above 300 seconds. On the morning of the sixth postoperative day, a repeat TEE showed mild right ventricular dysfunction. The RVAD was removed successfully that afternoon, with subsequent maintenance of hemodynamic function. Postoperatively, the CVP was 8mmHg, PAD 19mmHg, and cardiac index 2.7 l/min/m<sup>2</sup>. The remainder of the hospital course was uneventful, and the patient was discharged from the hospital to home on the 22nd postoperative day.

## DISCUSSION

Acute right ventricular failure following OHT may occur as a result of several factors: diminished protection of the donor heart during harvesting, ischemic injury during long transports, elevated PAP and PVR of the recipient, size mismatch between the donor (e.g. small) and recipient (e.g. large), distention of the ventricles during reperfusion, and left heart failure (6). When left heart failure is a primary cause of right heart failure, an IABP or left ventricular assist device (LVAD) should improve right ventricular contractility by maintaining coronary perfusion and reducing left atrial pressure. This was not the situation in our case, as observed by a failure to improve hemodynamics with an IABP. When right ventricular failure is not a consequence of left ventricular failure, specific measures to support the right ventricle must be instituted. Several reports have demonstrated the efficacy of RVADs in this setting (6-13).

Zumbro and colleagues (11) reported mechanical support for biventricular failure following coronary bypass and heart transplantation. One patient was supported for six hours following heart transplantation and acute graft failure until another donor could be found. Centrifugal pumps were used. A similar scenario was reported by Jurmann and colleagues (6) in a 50 year old man who developed right heart failure following OHT. A centrifugal RVAD was inserted and supported the patient until he was retransplanted within 14 hours. Gonger and colleagues (9) used centrifugal RVAD with prostaglandin E<sub>1</sub> (PGE<sub>1</sub>) infusion to support a failing right ventricle following OHT. The patient was weaned successfully from CPB, but died four days later of acute massive endobronchial hemorrhage. Nakatani and co-workers (8) described a similar case of right heart failure following OHT in a 61 year old man with preoperative pulmonary hypertension and elevated PVR. The patient was supported with a centrifugal RVAD and PGE<sub>1</sub>. The RVAD was removed suc-

Figure 2: External configuration of the Abiomed BVS 5000 System



cessfully on day six, but the patient succumbed to fungal sepsis two weeks later. Emery and colleagues (9) reported a series of nine patients in whom mechanical circulatory assistance was required after OHT. Four patients were supported with IABPs alone, two with RVADs alone, one with an LVAD alone, and two with BIVADs. All VADs were centrifugal pumps. Finally, Sestino and co-workers (13) published a recent complex case in which the patient was supported with pneumatically driven VADs before transplantation. Following transplantation, the patient developed acute right ventricular failure, requiring insertion of an Abiomed RVAD. The device was removed eight days later, and the patient was subsequently discharged from the hospital to home.

From these studies, it has become clear that the failing right heart following OHT can be supported with an RVAD. Except for the last case described, the VADs were centrifugal in design. The concerns with centrifugal VADs are blood trauma and bleeding complications (5). This does not appear to be as prevalent with the pneumatic BVS 5000 unit. The anticoagulation protocol allows for complete reversal of heparinization with protamine following placement of the VAD. After 24 hours, the goal of anticoagulation is to maintain an ACT between 180 and 200 seconds. This level is half the amount that is normally maintained during CPB. The advantages of the pneumatically driven Abiomed BVS 5000 system are several: less blood trauma (i.e. hemolysis), maintenance of pulsatile circulatory support, infrequent neurologic events, automatic control of pump flow, and minimal system pressure (14). These features translate into ease of use, physiologic support, and minimal morbidity. Worldwide, the Abiomed BVS 5000 system has been used to support patients in refractory failure in 16 countries and over 60 centers (Abiomed BVS 5000 Training Manual, 1994. Danvers, MA pp.

63-4). Although the majority (200 patients, 49%) of indications were for post-cardiotomy heart failure, 11% (44 patients) have been supported with the Abiomed BVS 5000 system following failed transplantation. The majority of these patients required LVADs and BIVADs. Because of its ease of use and low morbidity profile, we support the use of the pneumatically driven Abiomed BVS 5000 RVAD for right ventricular failure following OHT.

## REFERENCES

1. Kirklin JK, Naftel DC, Kirklin JW, et al. Pulmonary vascular resistance and the risk of heart transplantation. *J Heart Transplant*. 1988; 7:331-6.
2. Shumway SJ, Shumay NE. *Thoracic Transplantation*. Cambridge: Blackwell Science. 1995; 109.
3. Sabiston DC, Jr., Spencer FC. *Surgery of the Chest*. 5th ed. Philadelphia: WB Saunders Co. 1990; 1940.
4. Baue AE. *Glenn's Thoracic and Cardiovascular Surgery*. Norwalk: Appleton & Lange. 1991; 1616.
5. Finger JD, Brocken AM, Baumgartner WA, et al. Acute right ventricular failure following heart transplantation: Improvement with PGE and right ventricular assist. *J Heart Transplant*. 1986; 5:317-21.
6. Jurmann MJ, Whalers T, Coppola R, et al. Early graft failure after heart transplantation: Management by extracorporeal circulatory assist and retransplantation. *J Heart Transplant*. 1986; 5:317-21.
7. Radovancevic B, Nakatani T, Frazier OH, et al. Mechanical circulatory support for perioperative donor heart failure. *Trans Am Soc Artif Organs*. 1989; 35:539-41.
8. Nakatani T, Radovancevic D, Frazier OH. Right heart assist for acute right ventricular failure after orthotopic heart transplantation. *Trans Am Soc Artif Organs*. 1987; 33:695-8.
9. Gonger JD, Borkon Am, Baumgartner WA, et al. Acute right ventricular failure following heart transplantation: Improvement with prostaglandin E<sub>1</sub> and right ventricular assist. *J Heart Transplant*. 1986; 5: 317-21.
10. Emery RW, Eales F, Joyce LD, et al. Mechanical circulatory assistance after heart transplantation. *Ann Thorac Surg*. 1991; 51:43-7.
11. Zumbro GL, Shearer G, Kitchens WR, Galloway RF. Mechanical assistance for biventricular failure following coronary bypass operation and heart transplantation. *J Heart Transplant*. 1985; 4(3): 348-52.
12. Hooper TI, Odam NJ, Fetherston GJ, et al. Successful use of left ventricular assist device for primary graft failure after heart transplantation. *J Heart Transplant*. 1988; 7:385-7.
13. Sistino JJ, Mongero LB, Levin HR, Rose EA. Use of the Abiomed BVS 5000 for temporary right ventricular assist following implantation of the TCI Heartmate for left ventricular assist: A case report. *J Extra-Corpor Technol*. 1995; 26(4):210-4.
14. Guyton RA, Schonberg JPAM, Everts PAM, et al. Postcardiotomy shock: Clinical evaluation of the BVS 5000 biventricular support system. *Ann Thorac Surg*. 1993; 56:346-56.