

Case Reports

The Additive Effects of Antifibrinolytics: Dangers in the OR

Joseph J. Sistino MPA, CCP; Carolyn Richards BS, CCP

Program in Extracorporeal Circulation Technology, Medical University of South Carolina, Charleston, South Carolina

Keywords: epsilon aminocaproic acid, antifibrinolytics, cardiopulmonary bypass

Presented at the 36th International Conference of the American Society of Extra-Corporeal Technology, March 15, 1998, Philadelphia, Pennsylvania.

ABSTRACT

The use of antifibrinolytic agents in recent years had been heralded as a major breakthrough in the prevention of postoperative bleeding. However, whenever the delicate balance between coagulation and fibrinolysis is altered, the potential exists for disaster. There have been a number of complications reported in the literature related to the use of antifibrinolytics.

With the availability of oral epsilon aminocaproic acid (EACA) as treatment for the symptoms of hemophilia and other secondary bleeding disorders, the possibility exists that a patient presenting for heart surgery may already be receiving antifibrinolytic therapy.

A 72 year-old female underwent double valve replacement which was complicated by postoperative bleeding. Her medical history included gastrointestinal bleeding which was being treated with oral EACA. The patient was heparin resistant with a dose response of 55 sec/unit/ml. Heparin was administered during cardiopulmonary bypass to maintain the ACT between 400–500 seconds using a heparin-coated bypass circuit. In spite of this, the patient became thrombocytopenic and bled excessively in the postoperative period.

Administration of additional antifibrinolytic agents in the operating room may be contraindicated when the patient is receiving this therapy preoperatively, and may contribute to the development of a procoagulant state during bypass.

Address correspondence to:
Joseph J. Sistino, MPA, CCP
Program in Extracorporeal Circulation Technology
Medical University of South Carolina
101 Doughty
Charleston, South Carolina 29401

INTRODUCTION

Bleeding remains a common complication after repeat and complex cardiac surgery, and results in increased operative time and blood transfusion requirements with both the attendant risks and cost (1). Because an increased fibrinolytic state has been documented following median sternotomy and cardiopulmonary bypass (CPB), prophylactic administration of antifibrinolytic agents has been used to minimize transfusion requirements (2–8). The two most common antifibrinolytic agents used are epsilon aminocaproic acid (EACA) and aprotinin.

EACA is a synthetic lysine analog that is effective in inhibiting the fibrinolytic system. EACA affects the fibrinolytic system by occupying the lysine binding sites on plasminogen and plasmin. EACA prevents the binding of these molecules with the lysine residues on fibrinogen and fibrin (9).

At serum levels of 13 mg/dl, EACA combines with both plasminogen activator and plasminogen preventing the formation of active plasmin. At higher serum levels of 130 mg/dl, EACA causes direct inhibition of already formed plasmin. The plasma concentration reported to inhibit fibrinolysis *in vitro* is 130mg/mL (10,11).

Renal excretion is the primary route of EACA elimination. Sixty-five percent of the dose is recovered in the urine unchanged and the 1/2 life is 2 hours. After prolonged administration, EACA has been found to distribute throughout extravascular and intravascular compartments of the body. This is due to the small size of the EACA molecule. Since EACA penetrates the entire extravascular space, complete elimination of the drug is slow. Total elimination can take 12–36 hours. High concentrations of EACA can occur in patients with severe renal failure resulting in overdosage after only 8 g. EACA can be removed by dialysis.

EACA is indicated for use in enhancing hemostasis when fibrinolysis contributes to bleeding. Fibrinolysis may cause bleeding during a surgical procedure such as a portacaval shunt placement or with hematological disorders such as aplastic anemia and hemophilia. Hepatic cirrhosis, neoplastic disease, and inflammation of the gastrointestinal tract are also associated with hyperfibrinolysis and may be treated with oral EACA (12,13).

Reported complications of EACA include thrombus formation on heparin-coated pulmonary artery catheters (14), fatal aortic thrombosis during ECLS in a neonate (15), fatal pulmonary embolism during liver transplantation (16), intracardiac thrombus formation during liver transplantation (17), and acute kidney failure (18,19). Allergic reactions range from acute hypotension (20,21) to contact dermatitis (22). Noninflammatory subepidermal bullous eruption on the legs due to cutaneous vascular thromboses (23), massive intravascular coagulation of the inferior vena cava, right atrium, right ventricle, and pulmonary arteries before phlebography (24), deep vein thrombosis (25,26), and extensive thrombosis after central venous catheter placement (27) have been reported. Complications after

long term treatment include myopathy, rhabdomyolysis, or myonecrosis. Patients who require long term treatment should be monitored for myoglobinuria, and changes in serum CK, LDH, and AST (28–30).

The administration of EACA in the presence of disseminated intravascular coagulopathy (DIC) may cause intravascular thrombosis. The distinction between primary fibrinolysis and DIC must be made before administering EACA. EACA also affects platelets and prolongs bleeding times at a dosage greater than 24 g/day. This is due to the inhibition of ADP and collagen induced platelet aggregation, with the release of serotonin and the binding of fibrinogen to platelets (31).

CASE REPORT

A 72 year-old female with a 50 pack/year smoking history, hypercholesterolemia, hypertension, and peripheral vascular disease presented for mitral and aortic valve replacements. Her symptoms included fatigue, shortness of breath at rest, and two-pillow orthopnea. Past medical history was significant for gastrointestinal bleeding due to an A-V malformation. The patient was transfused with 4 units of packed red blood cells during the six months prior to admission, and was taking oral EACA 500 mg QID to control the bleeding. Other preoperative medications included nitroglycerin patch, and furosemide. The past medical history also included chronic renal insufficiency due to hypertensive nephrosclerosis.

The patient's weight was 75 kg with a BSA of 1.6 m². Cardiac catheterization revealed mitral and aortic valve regurgitation and left ventricular hypertrophy with RV pressures of 74/16 and PA of 71/40. The PCWP was 40 mm Hg. The preoperative cardiac output was 4.0 L/min and the ejection fraction was 60%. The preoperative hematocrit was 25.4% and the platelet count was 284,000.

Prior to bypass, the patient received 10 g of EACA and a 1 g/h infusion for 5 hours was started. The initial dose of 300 iu/kg of beef lung heparin was followed by additional heparin to reach the minimum level required for bypass. A total of 43,000 iu (573 iu/kg) of beef lung heparin were necessary to achieve an ACT of 396 sec (Figure 1). The patient's blood volume was estimated to be 4908 ml and the heparin concentration was estimated to be 7.9 iu/ml at the start of bypass. The heparin dose response was estimated to be 55.2 sec/iu/ml. The ACT was maintained above 400 sec during bypass until the final ACT of 386 sec just before the termination of bypass.

Bypass time for the double valve replacement was 131 min and the aortic cross-clamp time was 109 min. Three units of packed red blood cells were transfused during bypass and the hematocrit was 32% at the termination of bypass. A heparin-coated cardiopulmonary bypass circuit was used for this procedure.

After bypass, heparin was reversed with protamine sulfate and the ACT decreased to 127 sec (baseline ACT = 121 sec). Additional protamine was given and the ACT decreased to

**Activated clotting time -
baseline, bypass, and post bypass**

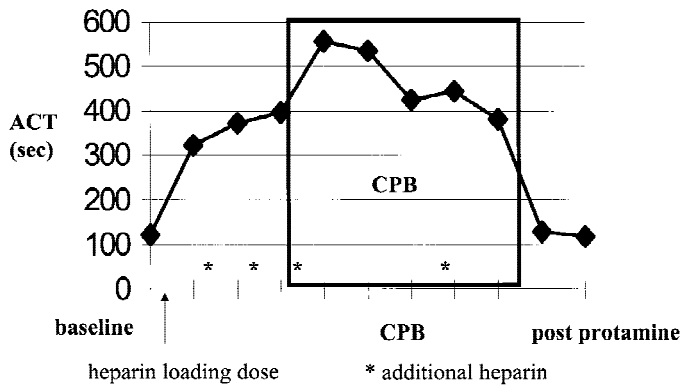


Figure 1: Activated clotting time and heparin administration—baseline, on bypass and post bypass

118. The patient was still bleeding and received two units of fresh frozen plasma. Coagulation studies revealed a fibrinogen of 285 mg/dl, a PT of 16 sec, a PTT of 56 sec and a platelet count of 95K/mm³ following transfusion. Ten units of pooled platelets were then given. The patient was transported to the Surgical Intensive Care Unit and continued to bleed at a rate of approximately 600 ml/h. After the third hour, the rate of bleeding increased further and the platelet count decreased to 39K/mm³, the fibrinogen level was 91mg/dl, and the D-dimers were > 8.0 (Table 1). EACA was restarted at the 6th hour postop and additional blood products were given.

The patient was returned to the operating room and reexplored for bleeding and tamponade after a decrease in cardiac output and mixed venous oxygen saturation. The abdomen was noted to be distended at this time. During the reexploration procedure, there was no tamponade noted, and the abdominal exploration was negative. Cardiac function suddenly deteriorated

and the heart could not be successfully resuscitated after a cardiac arrest.

DISCUSSION

The combination of long term EACA treatment for a gastrointestinal bleeding disorder and intraoperative EACA administration during cardiopulmonary bypass make this case unique. The patient received EACA preoperatively, and was hypercoagulable based on a preoperative activated partial thromboplastin time (APTT) of 22.3 sec. Fortunately, there was no massive thrombosis during cardiopulmonary bypass as reported in other cases of excessive EACA. The patient was resistant to heparin based on the increased heparin requirements necessary to achieve an adequate ACT for bypass and the reduced heparin dose response. One possibility is that this may have been related to decreased level of antithrombin III. Gastrointestinal inflammatory disease has been shown to increase fibrinolysis and decrease antithrombin III levels (12).

The question is whether EACA should be given intraoperatively in patients already receiving EACA therapy. This patient developed DIC following bypass based on the clinical presentation of multiple bleeding sites, decreased fibrinogen, and increased D-dimers. The ACT did not show an increase in the presence of this coagulation disorder. Every other coagulation parameter measured was abnormal and massive transfusion of blood products could not correct the disturbance. Replacement of plasma may have also replaced antithrombin III and allowed heparin rebound to occur. Based on the potential for heparin rebound, additional protamine was given to the patient.

Unrecognized DIC may have occurred during bypass which was masked by the EACA. Once the EACA infusion was completed, fibrin degradation products could have been incorporated into the new fibrin and prevented additional clot formation, producing the severe bleeding diathesis. When EACA was started again after the sixth postoperative hour, the bleeding had decreased, and there was no evidence of fibrinolysis on a thromboelastogram done at that time.

An important consideration to prevent this complication in the future may be the use of supplemental antithrombin III. Antithrombin III deficiency has been reported in patients with increased thrombin formation and in patients with gastrointestinal inflammatory disease producing gastrointestinal bleeding. Although the target ACT was achieved at approximately twice the normal heparin loading dose, this ACT level was inadequate to prevent the DIC during bypass. Supplementing antithrombin III during bypass may have reduced the thrombin formation, permitted a lower heparin dosing with a reduced potential for heparin rebound, and allowed the heparin-coated perfusion circuit to be more effective in blocking fibrin formation.

Patients that present with a history of a bleeding disorder are particularly challenging to the cardiac surgical team. A

Table 1: Postoperative coagulation studies

	PT (sec)	PTT (sec)	Platelets K/mm ³	Fibrinogen mg/dl	D-Dimers ug/ml
preop	12	22.6	284		
post bypass	16.3	65	95	295*	
1 hour					
2 hours	19	>100	75		
3 hours					
4 hours	18.2	>100		91	>8
5 hours			39		
6 hours					
7 hours	19.8	97.7	162		
8 hours					

*after 2 units of FFP

patient with a bleeding disorder that is undergoing treatment with an antifibrinolytic agent which may impact the coagulation process during cardiopulmonary bypass, needs careful review for the potential risks.

Based on this case report, the following recommendations can be made for patients presenting with long term treatment with oral EACA. First, proceed with caution. The patient may have ongoing fibrinolysis with evidence of increased D-dimers preoperatively. Second, measure the preoperative ATIII levels and if there is a deficiency, treatment should consist of replacement ATIII prior to CPB. And third, avoid the use of EACA during bypass due to the potential danger of a thrombotic state on bypass and subsequent DIC.

There are many pharmacologic agents that can be used to carefully control the balance between clotting and fibrinolysis. By reviewing our experience in this case, we hope to improve the care of patients with a similar clinical presentation.

REFERENCES

- Hardy JF, Belisle S. Natural and synthetic antifibrinolytics: inert, poisonous or therapeutic agents? *Can J Anaesth*. 1997; 44:913-917.
- Menichetti A, Tritapepe L, Ruvolo G, et. al. Changes in coagulation patterns, blood loss and blood use after cardiopulmonary bypass: aprotinin vs tranexamic acid vs epsilon aminocaproic acid. *J Cardiovasc Surg*. 1996;37:401-407.
- Penta de Peppo A, Pierri MD, Scafuri A, et. al. Intraoperative antifibrinolysis and blood-saving techniques in cardiac surgery. Prospective trial of 3 antifibrinolytic drugs. *Tex Heart Inst J*. 1995;22:231-236.
- Chen RH, Frazier OH, Cooley DA. Antifibrinolytic therapy in cardiac surgery. *Tex Heart Inst J*. 1995;22:211-215.
- Hardy JF, Belisle S. Natural and synthetic antifibrinolytics in adult cardiac surgery: efficacy, effectiveness and efficiency. *Can J Anesth*. 1994;41:1104-1112.
- DelRossi AJ, Cernaianu AC, Botros S, Lemole GM, Moore R. Prophylactic treatment of postperfusion bleeding using EACA. *Chest* 1989; 96:27-30.
- Daily PO, Lamphere JA, Dembitsky WP, Adamson RM, Dans NF. Effect of prophylactic epsilon-aminocaproic acid on blood loss and transfusion requirements in patients undergoing first-time coronary artery bypass grafting. A randomized, prospective, double-blind study. *J Thorac Cardiovasc Surg*. 1994;108:99-106.
- Karski JM, Teasdale SJ, Norman PH, Carroll JA, Weisel RD, Glynn MF. Prevention of postbypass bleeding with tranexamic acid and epsilon-aminocaproic acid. *J Cardiothorac Vasc Anesth*. 1993. 7:431-435.
- Moore RA. Intra-operative Evaluation of Hemostasis In: Lake C ed. *Clinical Monitoring*. Philadelphia: WB Saunders; 1990; 545-547.
- Bennett-Guerrero E, Sorohan JG, Canada AT, et al. Epsilon-aminocaproic acid plasma levels during cardiopulmonary bypass. *Anesth Analg*. 1997;85:248-251.
- Montesano RM, Gustafson PA, Palanzo DA, Manley NJ, Sadr FS. The effect of low-dose epsilon-aminocaproic acid on patients following coronary artery bypass surgery. *Perfusion*. 1996;11:53-56.
- Conlan MG, Haire WD, Burnett DA. Prothrombic abnormalities in inflammatory bowel disease. *Digestive Dis Sci*. 1989;34:1089-1093.
- Sherry S. Antifibrinolytic agents and their therapeutic use. In: *Fibrinolysis, Thrombosis, and Hemostasis*. Philadelphia: Lea and Febiger; 1992; 293-295.
- Dentz ME, Slaughter TF, Mark JB. Early thrombus formation on heparin-bonded pulmonary artery catheters in patients receiving epsilon aminocaproic acid. *Anesthesiol*. 1995 ;82:583-586.
- Hocker JR, Saving KL. Fatal aortic thrombosis in a neonate during infusion of epsilon-aminocaproic acid. *J Ped Surg*. 1995;30:1490-1492.
- Sopher M, Braunfeld M, Shackleton et. al. Fatal pulmonary embolism during liver transplantation. *Anesthesiol*. 1997; 87:429-432.
- Plotkin JS, Johnson LB, Kuo PC. Intracardiac thrombus formation during orthotopic liver transplantation: a new entity or and old enemy. *Transplant*. 1996; 61:1131.
- Pitts TO, Spero JA, Bontempo FA, Greenberg A. Acute renal failure due to high-grade obstruction following therapy with epsilon-aminocaproic acid. *Am J Kidney Dis*. 1986;8:441-444.
- Biriukova LS, Gumin LM, Gorodetskii VM. Acute kidney failure due to obstruction of the upper urinary tract during the use of aminocaproic acid. [Russian] *Terapevticheskii Arkhiv*. 1993;65:83-85.
- Yien HW, Hseu SS, Chan KH, Lee TY. Suspected anaphylactoid shock to aminocaproic acid during operation. *Chung Hua i Hsueh Tsa Chih [Chinese] Medical Journal*. 1992;50:415-419.
- Kazanbiev NK, Akhmedova DA, Gasanova RG, Bagamedov MM, Sfiev A. Anaphylactic shock in response to the administration of epsilon-aminocaproic acid.. [Russian] *Klinicheskaiia Meditsina*. 1987;65:140-141.
- Tanaka M, Niizeki H, Miyakawa S. Contact dermatitis from epsilon-aminocaproic acid. *Contact Dermatitis*. 1993;28:124.
- Brooke CP, Spiers EM, Omura EF. Noninflammatory bullae associated with epsilon-aminocaproic acid infusion. *J Amer Acad Derm*. 1992;880-882.
- Coste F, Tremolieres F, Bousquet M, et. al. Fatal massive intravascular coagulation during phlebography. Responsibility of epsilon-aminocaproic acid?. [French] *Presse Medicale*. 1985;14:832-834.

25. Tahmouresie A. Venous thrombosis. *J Neurosurg.* 1979; 51:266.
26. Sinclair J, Forbes CD, Prentice CR, Scott R. The incidence of deep vein thrombosis in prostatectomised patients following the administration of the fibrinolytic inhibitor, aminocaproic acid (EACA). *Urolog Res.* 1976;4:129–131.
27. Hayhurst MD. Extensive thrombosis following central venous catheterization—a relationship to antifibrinolytic therapy? *South Afric Med J.* 1983;63:797.
28. Seymour BD, Rubinger M. Rhabdomyolysis induced by epsilon-aminocaproic acid. *Ann Pharmacother.* 1997;31: 56–58.
29. Winter SS, Chaffee S, Kahler SG, Graham ML. Epsilon-aminocaproic acid-associated myopathy in a child. *J Ped Hematol/Oncol.* 1995;17:53–55.
30. Kane MJ, Silverman LR, Rand JH, Paciucci PA, Holland JF. Myonecrosis as a complication of the use of epsilon amino-caproic acid: a case report and review of the literature. *Amer J Med.* 1988;85:861–863.
31. Haddy SM, Shely WW, Rice N. Intravascular thrombosis after exsanguination in a patient treated with epsilon-aminocaproic acid. *J Cardiothorac Vasc Anes.* 1996;10: 510–512.