

---

**Original Article*****A Cardiopulmonary Bypass Perfusion Technique for the Surgical Repair of Aortic Type I Dissections Requiring the Elephant Trunk Procedure***

Tianyu Yang, MD\*; Lizhong Sun, MD†; Feilong Hei, MD\*; Yongmin Liu, MD†

\*Department of Cardiopulmonary Bypass and †Cardiac Surgery, Cardiovascular Institute and FuWai Hospital, Chinese Academy of Medical Sciences, Peking Union Medical College, Beijing

Keywords: cardiopulmonary bypass, selective cerebral and lower half of the body perfusion, elephant trunk procedure

**ABSTRACT**

The effect of cerebral and spinal cord protection by a modified perfusion technique during the elephant trunk procedure was assessed. Between 1997 and 1998, six patients underwent selective cerebral perfusion (SCP) and lower half of the body perfusion (LBP), in which the right subclavian and left femoral arteries were separately cannulated and perfused by individual pump heads. Moderate systemic cooling was used (nasal temp. 20–30°C; rectal temp. 23–26°C). The open distal aortic repair was performed using only the selective cerebral perfusion; while the aortic arch reconstruction was performed using both selective cerebral and lower half of the body simultaneous perfusion. Blood oxygen saturation of the left jugular vein (SjO<sub>2</sub>) and regional oxygen saturation cerebral (rSO<sub>2</sub>) in the front region of the brain, was monitored along with the pressure of the left temporal superficial and femoral artery. The mean cardiopulmonary bypass time was 136 minutes, with a mean arrest time of 92 minutes. Mean duration of isolated selective cerebral perfusion was 23 minutes, with flow rates of 5–8 mL/kg/min; a left temporal superficial artery pressure of 50 mmHg; SjO<sub>2</sub> 65–80%, and rSO<sub>2</sub> 58–72%. Mean duration of simultaneous selective cerebral and lower half of the body perfusion was 27 minutes; cerebral flow rates 5–8 mL/kg/min; the left temporal superficial artery pressure of 45–50 mmHg; SjO<sub>2</sub> 70–85% and rSO<sub>2</sub> 55–76%. At the same time, lower half of the body flow rates were maintained within 30–50 mL/kg/min; with a femoral artery pressure 50–80 mmHg. Mean extubation time was 28 hours; mean ICU time was 4.5 days. There were no neurologic complications in any patient. All patients survived the operation and were discharged from the hospital. This modified perfusion technique of SCP and LBP worked well and provided satisfactory cerebral and spinal cord protection.

Address correspondence to:  
Tianyu Yang, MD  
Division of Clinical Education  
University of Nebraska Medical Center  
Box 985155  
Omaha, NE 68198-5155  
Tyyang12@hotmail.com

## INTRODUCTION

Cerebral protection and adequate perfusion to prevent neuropsychologic dysfunction is a major concern and challenge during aortic arch and proximal descending aortic reconstructions. The surgical procedure often requires exclusion of the cerebral circulation for varying periods during cardiopulmonary bypass (CPB). Currently, the perfusion techniques used to prevent cerebral damage include deep hypothermia circulatory arrest (DHCA), selective cerebral perfusion (SCP), and retrograde cerebral perfusion (RCP) (1–4). DHCA is the most common method, but its principle drawbacks are: a limited safe ischemic period; longer duration of CPB for cooling and rewarming, and increased coagulation, renal, and pulmonary complications (5). The improvement of these perfusion techniques decreased the mortality rate from 50% in early years of aortic surgery to 4.8% in more recent studies (6). Although various cerebral protection methods have been introduced and used in our clinic, the incidence of postoperative brain damage is as follows: DHCA 3.6–11%; SCP 1.3–10.5%; RCP 0–11.8% (1–4). Spinal cord injury after aortic repair has been reported to occur in as many as 21% of patients (7).

Special cerebral and spinal cord protection methods are mandatory during surgical treatment of DeBakey type I dissections, which is a dissection involving the ascending, transverse, and descending aorta, using the elephant trunk procedure, because this complex operative procedure interrupts cerebral and spinal cord blood flow and requires longer support by CPB (8). We performed a modified perfusion technique (selective cerebral and lower body perfusion) during the elephant trunk procedure. The purpose of this study was to evaluate the effect of cerebral and spinal cord protection by a modified perfusion technique for surgical treatment of aortic dissection.

## PATIENTS AND METHODS

### PATIENTS

Between December 1997 and October 1998, the elephant trunk procedure was performed in six patients (four men and two women) for repair of DeBakey-I aortic dissection. The patients ranged in age from 34 to 68 years (mean age, 47 years). Acute dissection was diagnosed in four patients and chronic dissection in two patients.

### Anesthesia and Surgical Technique

The intraoperative anesthetic technique was standardized and consisted of intravenous fentanyl, midazolam, and vecuronium. Inhaled isoflurane was also used. Aprotinin was administered according to the high-dose Hammersmith protocol for all patients.

### Cardiopulmonary Bypass Technique

The pump-oxygenator system consisted of a Stockert–Shiley

roller pumps system<sup>a</sup> and a membrane oxygenator with integral sealed-hardshell reservoir.<sup>b</sup> The CPB system was primed with 1000 to 1500 mL of lactated Ringer's solution, Haemoceol 1000 mL, and heparin 2000 IU. A bolus dose of heparin (400 IU/kg) was administered intravenously before CPB, and the activated coagulation time (ACT) was maintained at a value more than 750 seconds during CPB. Myocardial protection was achieved by intermittent infusion of cold blood cardioplegic solution (crystalloid: blood = 1:4) via selective coronary perfusion. Systemic temperature was cooled to a nasal temperature of 20–23°C, rectal temperature of 23–26°C. The average cooling duration was approximate 20–25 min without ice packs applied to the patient's head. During cooling and rewarming, acid-base balance was managed according to the  $\alpha$ -stat strategy and pH-stat during the period of deep hypothermia.

Jugular vein oxygen saturation (SjO<sub>2</sub>), regional cerebral oxygen saturation (rSO<sub>2</sub>) in the frontal region of the brain, continuous venous blood oxygen saturation (SvO<sub>2</sub>), transcranial Doppler ultrasonography (TCD), electroencephalogram (EEG), and left temporal superficial and femoral artery pressure were all monitored.

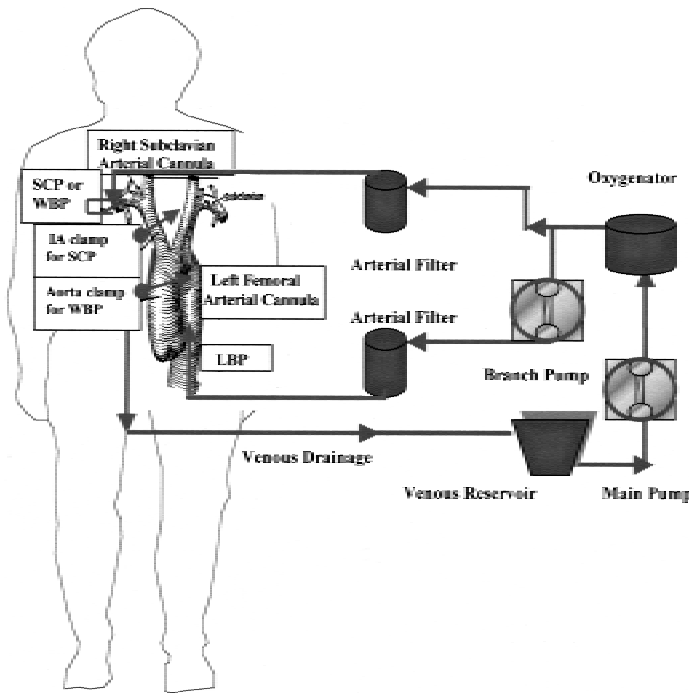
### Modified Perfusion Technique

Dual arterial cannulae<sup>c</sup> 22 Fr., 20 Fr. were separately placed in the right subclavian artery, positioned in the direction of the innominate artery and left femoral artery. A single dual-stage venous<sup>c</sup> cannula (34 or 36 Fr.) was placed in the right atrium. The main pump situated before the oxygenator performed a simplified selective cerebral perfusion or whole body perfusion via the right subclavian artery (Figure 1). Flow rates were maintained within 5–8 mL/kg/min during selective cerebral perfusion and flow rates of 2.0–2.8 mL/kg · min<sup>-1</sup> during whole body perfusion. The lower half of the body perfusion via the left femoral artery was performed by a branch pump situated after the oxygenator. Flow rates for lower body perfusion were maintained within 30–50 mL/kg/min (Figure 1). In the first stage, the ascending aorta or aortic root is repaired during deep hypothermia and whole body perfusion by cross-clamp aorta. The second stage descending aorta distal anastomosis is performed during system circulatory arrest and selective cerebral perfusion by cross clamping the innominate artery. The third stage, aortic arch reconstruction, is performed by replacement of the aortic arch with an island of aortic tissue containing the brachiocephalic vessels during selective cerebral perfusion and lower half of the body perfusion by cross clamping the descending aortic graft. Rewarming was begun with whole body perfusion maintaining venous blood oxygen saturation above 80%.

<sup>a</sup> Sorin Biomedical, Irvine, CA

<sup>b</sup> Medtronic, Anaheim, CA

<sup>c</sup> Teruno Sarns Healthcare, Ann Arbor, MI



**Figure 1:** IA immonate artery; LBP the lower half of the body perfusion; SCP selective cerebral perfusion; WPB whole body perfusion.

**RESULTS**

Types of operative procedures are shown in Table 1. The mean CPB time was 136 minutes (131–147); mean arrest time was 92 min (75–104). Mean duration of selective cerebral perfusion was 23 min (20–26); with flow rates maintained within 5–8 mL/kg/min. During selective cerebral perfusion, the left temporal superficial artery pressure was maintained at approximately 50 mmHg; SjO<sub>2</sub> ranged between 65 and 80%; rSO<sub>2</sub> was between 58 and 72%. Mean duration of simultaneous selective cerebral and lower half of the body perfusion was 27 min (14–34). During the simultaneous perfusion, the left temporal superficial artery pressure was maintained about 45–50 mmHg; SjO<sub>2</sub> was between 70 and 85%; rSO<sub>2</sub> was between 55 and 76%. At the same time, lower half of the body flow rates were maintained within 30–50 mL/kg/min; femoral artery pres-

**Table 1. Surgical Procedure**

Graft replacement + Concomitant procedure	No. of patients
Ascending aorta + total arch + descending aorta	4
Ascending aorta + total arch + descending aorta + replacement of aortic root	1
Ascending aorta + total arch + descending aorta + replacement of aortic valve (Bentall's procedure)	1

sure was maintained about 50–80 mmHg. Operative results and patient outcomes are shown in Table 2. There were no neurological complications in any patient. All patients survived the operation and were discharged from the hospital.

**DISCUSSION**

The elephant trunk procedure involves the placement of a tubular aortic graft prosthesis into the distal aorta and the repair of the descending aorta. The distal elephant trunk prosthesis is then used for a second stage operation that involves the replacement of sections of the distal aorta. The application of selective cerebral perfusion, which does not require deep hypothermia, is one of the most popular methods for cerebral protection during aortic arch repair (5, 6). Aoyagi and colleagues suggest that the simplified selective cerebral perfusion under hypothermic CPB provides as satisfactory cerebral protection as bihemispheric cerebral perfusion, as long as the patency of the circle of Willis is confirmed (9). The confirming methods include carotid artery compression test, monitoring of left middle cerebral artery flow velocity by transcranial Doppler, and preoperative cerebral angiography. However, no one method reflects cerebral perfusion adequately during operation. High flow and pressure can also produce brain damage, because high-flow perfusion increases pressures in intracranial and extracranial vessels (4). Combining several monitoring methods may provide better assessment of cerebral perfusion (4, 6). In addition to regulating right and left cerebral perfusion pressures and flow rates, other methods such as monitoring regional cerebral oxygen saturation, jugular vein oxygen saturation and monitoring cerebral blood flow by transcranial Doppler ultrasonography, and electroencephalography have been used in this study. This study has shown that the application of simplified selective cerebral perfusion is safe if extended neurophysiological monitoring is included in the clinical setting. Despite advances in surgical technique, spinal cord injury after aneurysm repair can occur, and paraplegia is a devastating and unpredictable complication (7). Neurological injury is a result of the ischemia brought on by aortic cross

**Table 2. Operative Results and Clinical Outcomes**

Parameters	Results mean range
Extubation mean time	28 hours (24–36)
Staying ICU mean time	4.5 days (4–5)
Neurological complications	
Stroke	None
Seizure	None
Paraplegia/paraparesis	None
Renal failure	None
Multiorgan failure	None
Mortality during hospital	None

clamping in the absence of adequate collateral flow and increases with the duration of occlusion. Efforts to protect the spinal cord during ischemia have ranged from purely mechanical such as perfusion of the aorta beyond the cross clamping. Cardiopulmonary bypass via lower half of the body perfusion is usually only used to re-establish the blood supply to the spinal cord. In this study, aortic arch reconstruction with cerebral and lower half of the body perfusion was performed simultaneously to decrease the time of spinal ischemia.

The advantages of a simplified selective cerebral perfusion and lower half of the body perfusion technique without deep hypothermia and circulatory arrest are: shortening CPB time; prolonging the aortic reconstruction period; and decreasing the risk of neurological dysfunction, coagulopathy, and organ failure. It provides satisfactory cerebral and spinal cord protection.

cerebral perfusion technique. *Thorac Cardiovasc Surg.* 1994;42:279–84.

## ACKNOWLEDGMENT

The authors thank Mr. Alfred Stammers for his help in preparing the manuscript.

## REFERENCES

1. Coselli JS, Buket S, Djukanovic B. Aortic arch operation: Current treatment and results. *Ann Thorac Surg.* 1995;59:19–27.
2. Hayashi JJ, Eguchi S, Yasuda K, et al. Aortic arch operation using selective cerebral perfusion for nondissecting thoracic aneurysm. *Ann Thorac Surg.* 1997;63:88–92.
3. Deeb GM, Jenkins E, Bolling SF, et al. Retrograde cerebral perfusion during hypothermic circulatory arrest reduces neurologic morbidity. *J Thorac Cardiovasc Surg.* 1995;109:259–68.
4. Sakurada T, Kazui T, Tanaka H, et al. Comparative experimental study of cerebral protection during aortic arch reconstruction. *Ann Thorac Surg.* 1996;61:1348–54.
5. Testolin L, Roques X, Laborde MN, et al. Moderately hypothermic cardiopulmonary bypass and selective cerebral perfusion in ascending aorta and aortic arch surgery. Preliminary experience in 22 patients. *J Cardiovasc Surg.* 1998;6:398–405.
6. Alamanni F, Agrifoglio M, Pompilio G, et al. Aortic arch surgery: Pros and cons of selective cerebral perfusion. *J Cardiovasc Surg.* 1995;3:31–7.
7. Cox GS, O'Hara PJ, Hertzner NR, et al. Thoracoabdominal aneurysm repair: A representative experience. *J Vasc Surg.* 1992;15:780–8.
8. Ando M, Takamoto S, Okita Y, et al. Elephant trunk procedure for surgical treatment of aortic dissection. *Ann Thorac Surg.* 1998;66:82–7.
9. Aoyagi S, Akashi H, Kubota Y, et al. Surgical treatment of aneurysms of the aortic arch using a simplified selective