

# Penetrating Injury to the Heart Requiring Cardiopulmonary Bypass: A Case Study

David P. Webb, MS, CCP; James J. Ramsey, CCP, JD; Rebecca J. Dignan, MD;  
Davis C. Drinkwater, Jr., MD

Vanderbilt University School of Medicine, Department of Cardiac and Thoracic Surgery, Nashville, Tennessee

---

**Abstract:** Penetrating wounds to the heart represent a significant surgical challenge because of their unique clinical course and the need for emergent operative care. This operative care, which may include cardiopulmonary bypass (CPB), must be initiated in a prompt yet careful fashion to optimize outcome, while minimizing morbidity. Trauma, because of its unpredictable and non-routine nature, may present many challenges to the perfusionist

in an attempt to anticipate surgical needs and requirements. In this case report, we describe the successful surgical repair of a cardiac nail gun injury, as well as strategies we feel are essential for the safe, successful, and timely application of emergent CPB. **Keywords:** trauma, safety, cardiopulmonary bypass, penetrating cardiac injuries, emergency, emergency CPB. *JECT 2001;33: 249–251*

---

Penetrating cardiac injuries are an increasing cause of traumatic deaths in urban areas (1–4). The over-all success in managing such injuries is often based on the timely application of resuscitative efforts and fluid management (5, 6). Other factors that significantly impact outcome include mechanism of injury and emergent operative care (5, 6, 7).

Understanding the mechanism by which nail guns inflict injury is pivotal to expectations of tissue destruction and surgical needs. Bolting instruments such as nail or stud guns first came into use in 1959 and subsequently found widespread acceptance in the 1960s (8). These tools are used to project nails into wood or concrete. They work by accelerating the projectile indirectly through a piston powered by compressed air (8, 9). Muzzle energies of these guns range between 100 and 1000 J secondary to their relatively large diameter (9, 10). Lack of stabilization allows tumbling of the projectile to occur close to the muzzle, thus causing poor target accuracy (9, 11, 12). Variable velocities and the tumbling of the projectile after a short distance lead to variable depths of injury from these penetrating weapon-like instruments (9, 11, 13).

Emergent operative care is often the determining factor for trauma victims with the application of life support measures (5, 6, 7, 14). Providing emergent cardiopulmonary support is not unique to most practicing clinical per-

fusionists, especially those involved in providing perfusion care at level one trauma centers. However, because of its unpredictable nature, trauma remains a challenge in anticipating appropriate needs for optimal clinical course.

## CASE DESCRIPTION

A 31 year-old white male apparently fell from an 11-foot ladder onto a nail gun which delivered five sixteen penny nails into the mediastinum (Figure 1). He was subsequently transported to a local urban hospital where a left sided chest tube was placed before he was air lifted to a level one trauma center. Upon arrival, another left-sided chest tube was placed, which showed a combined drainage of approximately 2.5 L of blood. The patient was intubated and transported to the operating room after a flat plate chest X-ray was taken (Figure 2).

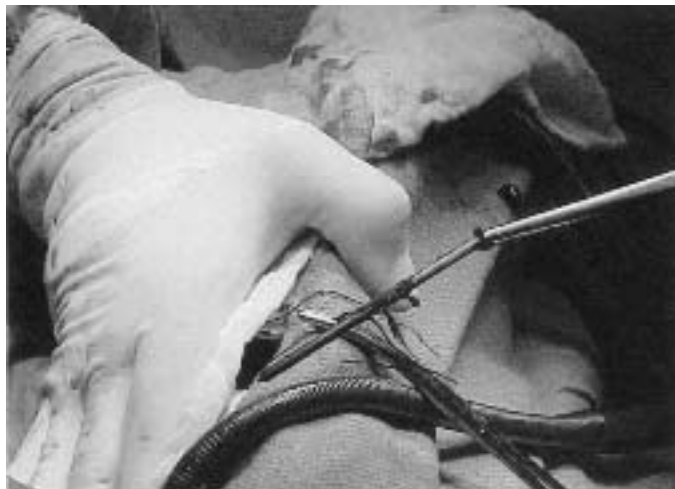## CASE MANAGEMENT

On arrival in the operating room, the patient was transferred to a dedicated open-heart suite where a left radial arterial line, left antecubital intravenous line, and a central venous line were placed. The patient was then prepped and draped in a sterile fashion with his left side slightly elevated, keeping his spine immobilized. A transesophageal probe was placed to help identify the location of the nails and to detect possible changes in cardiac wall motion. The patient then underwent a full median sternotomy. The pericardium was opened, which showed a sig-

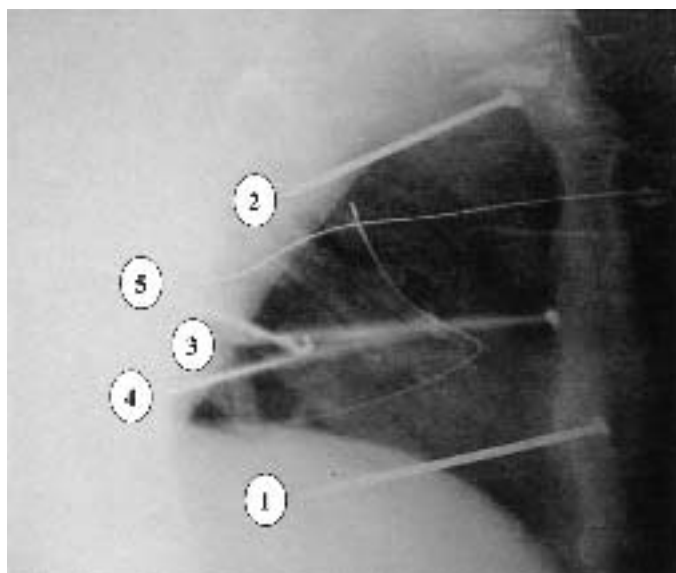
---

Address correspondence to: David P. Webb, MS, CCP, 2986 The Vanderbilt Clinic, Nashville, TN 37232. E-mail: david.webb@mcm.vanderbilt.edu

Received January 25, 2001; accepted August 1, 2001.



**Figure 1.** This shows the third sixteen penny nail removed from the chest during cardiopulmonary bypass.



**Figure 2.** Lateral chest X-ray; the numbers concur with the location of each nail as reported in the text.

nificant amount of blood, all of which was transferred to an autotransfusion device (Autolog, Medtronic Cardiopulmonary Inc., Anaheim, CA, 92807). The first nail that was noted went through the lateral aspect of the right ventricle without injury to the right coronary artery. It was removed without difficulty after placing a purse string suture around the anterior hole in the right ventricle. The posterior hole was oversewn. The second nail was located in the anterior upper left chest wall, terminating in the left upper lobe of the lung. This nail was removed and the holes oversewn without bleeding into the lung. At this point, the patient was placed on CPB to facilitate removal of the remaining nails.

The patient was given 35,000 USP bovine heparin before placing a 19.5 Fr. aortic cannula (Sarns, Terumo Cardiovascular Systems Corp., Ann Arbor, MI 48103) into the ascending aorta. Two 24 Fr. single stage venous cannulas (DLP-Medtronic, Grand Rapids, MI 49501) were then inserted into the right atrium to access the superior and inferior venae cavae. CPB was initiated in a timely yet careful fashion before complete hemodynamic collapse.

The third nail addressed was located approximately 6 mm medial to the left anterior descending (LAD) coronary artery through the posterior lateral aspect of the left ventricle terminating in the lingula. It was removed and the holes were over sewn without injury to the LAD. The fourth nail was observed to pass through a small branch of the circumflex obtuse marginal coronary artery in the lateral posterior wall of the left ventricle, terminating in the left lower lobe of the lung. This nail was removed and the holes over sewn, taking care to avoid another larger branch of the circumflex marginal coronary artery. The fifth nail was the most problematic given that it could be palpated posteriorly, exiting the left atrium superior to the coronary sinus. The entry site was at the most superior aspect of the right ventricle and just inferior to the right atrium, and thought to be traversing the right atrium and/or ventricle with possible tricuspid valve injury. Therefore, after snaring down the superior and inferior vena cava cannuli, the right atrium was opened. The head of the fifth nail was noted in the Triangle of Koch passing into the left atrium and terminating distally through the posterior wall of the left atrium. On opening the posterior pericardium, the nail had entered the esophagus. The nail was removed and the esophagus repaired in two layers. The entry and exit sites of the left atrium were carefully over sewn. There was no evidence of heart block before or after surgical intervention.

During the course of CPB (121 min), the patient was given two bowls of salvaged blood, two units of leukoreduced homologous blood, 250 mL of 5% albumin, and 150 mEq NaHCO. A hemoconcentrator (Minntech Corp., Minneapolis, MN) was used to remove approximately 1400 mL of effluent. The prime consisted of 2300 mL of plasmalyte-A, 1 gm CaCl, 500 mg solumedrol, and 2000 USP bovine heparin. Flow ranged between 4.2 and 5.0 L/min with the patient's temperature ranging between 35 and 37°C. The ACT measured 933 s after the initial bolus of heparin and was out of range until after protamine was administered. Blood gases were sent to the medical laboratory every 30 min, and appropriate manipulations were made to bring them within normal acceptable range before CPB termination. The patient was successfully weaned from CPB on the second attempt with dopamine, dobutamine, and calcium. The patient remained in the hospital for 12 days and recovered uneventfully.

## DISCUSSION

Although some patients do survive such dramatic injuries, many die regardless of the energy and resources expended in attempts to save them. Although penetrating wounds to the heart represent just one of the many unique applications of CPB, trauma in general may present numerous challenges to the perfusionist because of its unpredictable and nonroutine nature. Although it may be impossible to be prepared for all circumstances, there are steps that may be taken to assist with situations out of the ordinary. The following are some strategies the authors feel are essential for safe, successful, and timely application of emergent care requiring CPB:

1. *Good Communication* is a vital component of all facets of emergent care, because of time constraints superimposed upon the quest for successful outcomes. From having a reliable and effective method of contacting those involved in providing emergent operative care, to utilizing an established standard of communication within the operating room used routinely to lessen the potential for human error, are essential.
2. *Dedicated Surgical Suite* capable of providing the power requirements for all equipment needed.
3. *Software Intact* and ready for use. Maintaining a dry circuit on a heart–lung machine, and have a cell salvage device situated within the dedicated surgical suite. In addition, have a heater/cooler device for thermal manipulations, and ample solutions to prepare all devices and equipment.
4. *Emergency Disposable Kit* containing various cannula, catheters, connectors, and tubing applicable to any CPB situation should be in place.
5. *Established Protocols* should be readily available for all CPB interventions, in addition to guidelines that are routinely reviewed and updated by all applicable personnel for routine and unusual circumstances.

6. *Perfusion Savvy.* All personnel should understand and know limitations of equipment and circuit, practice emergency procedures and protocols, and anticipate manipulations required at field to fulfill situational responsibilities.

Although there are many factors that do affect the outcome of trauma patients, perfusionists should be the most prepared personnel to deal with such situations. Trauma may even provide another venue for the extracorporeal circulation technologists to employ their skills in areas outside of the surgical setting.

## REFERENCES

1. Sugg WL, Rea WJ, Ecker RR, et al. Penetrating wounds of the heart: An analysis of 459 cases. *J Thorac Cardiovasc Surg.* 1968;56:531–45.
2. Mittal V, McAleese P, Young S, et al. Penetrating cardiac injuries. *Am Surg.* 1999;65:444–48.
3. Kamry-Jones R, Wijngaarden MH, Talwar MK, et al. Penetrating cardiac injuries. *Injury.* 1997;28:57–61.
4. Follette DM. Penetrating cardiac injuries. *Ann Thorac Surg.* 1991; 51:701–2.
5. Degennaro VA, Bonfils-Roberts EA, Chang N, et al. Aggressive management of potential penetrating cardiac injuries. *J Thorac Cardiovasc Surg.* 1980;79:833–37.
6. Asensio JA, Murray J, Demetriades D, et al. Penetrating cardiac injuries: A prospective study of variables predicting outcomes. *J Am Coll Surg.* 1998;186:24–34.
7. Asensio JA, Berne JD, Demetriades D, et al. One hundred five penetrating cardiac injuries: A 2-year prospective evaluation. *J Trauma.* 1998;44:1073–82.
8. Lyons FR. Industrial nail gun injuries. *Med J Aust.* 1983;2:483–7.
9. Vosseinkel JA, Bilfinger TV. Cardiac nail gun injuries: Lessons learned. *J Trauma.* 1999;47:588–90.
10. Opeskin K, Cordner S. Nail-gun suicide. *Am J Forensic Med Pathol.* 1990;11:282–84.
11. Spitz WU, Wilhelm RM. Stud gun injuries. *J Forensic Med.* 1970;17: 5–11.
12. Weedn VW, Mittleman RE. Stud guns revisited: Report of a suicide and literature review. *J Forensic Sci.* 1984;29:670–8.
13. Kizer KW, Boone HA, Heneveld E, et al. Nail gun injury to the heart. *J Trauma.* 1995;38:382–3.
14. Atter S, Suter C, Hankins JR, et al. Penetrating cardiac injuries. *Ann Thorac Surg.* 1991;51:711–6.