

Case Report

Argatroban in Adult Extracorporeal Membrane Oxygenation

Nicklett Johnston, RN BSN, CCP; Michael Wait, MD; Lynne Huber, RNFA

Department of Cardiothoracic Surgery. The University of Texas Southwestern Medical Center at Dallas

Abstract: This case report addresses the use of Argatroban, an anticoagulant and thrombin inhibitor for treatment of thrombocytopenia in an adult patient on extracorporeal membrane oxygenation (ECMO). After 5 days on ECMO, the patient showed signs of heparin-induced thrombocytopenia (HIT) with a platelet count of 20K. Argatroban was initiated to decrease progression of HIT and continue treatment with ECMO proved to

be successful. Given the occurrence of HIT with heparin therapy, a need for alternate drug therapy is required for patients requiring treatment with ECMO. The use of Argatroban in adult ECMO is outlined and includes dosage, monitoring, and patient treatment. **Keywords:** thrombocytopenia, thrombin time, activated partial thromboplastin time, extracorporeal membrane oxygenation. *JECT. 2002;34:281–284*

Extracorporeal membrane oxygenation (ECMO) is used for long term support in cases of respiratory distress syndromes and for resuscitating patients with circulatory collapse caused by acute myocardial infarction and post-operative cardiac failure (1). Extracorporeal circulation for cardiac surgery requires full heparinization; however, extracorporeal circulation for ECMO does not require an activated clotting time (ACT) of 450 or above. The use of heparin coatings, connectors, and cannulae, with the use of a centrifugal pump, have made it possible to perform extracorporeal circulation procedures without full heparinization (1). The prolonged use of heparin activates platelets and enhances platelet aggregation and prolongs bleeding time. Heparin induced thrombocytopenia (HIT) is an adverse reaction to heparin mediated by an immune mechanism that can present as an isolated event or an event associated with thrombotic events. Alternative anticoagulation therapy is required for patients needing ongoing anticoagulation for underlying medical conditions. This case study describes the results of a patient on ECMO for 10 days and the use of Argatroban as an alternative anticoagulant after the patient was suspected of having HIT. The use of Argatroban directly reduced the risk of thrombosis and death caused by thrombosis. It also

offered a therapeutic alternative for a patient with limited options.

CASE STUDY

The patient is a 32-year-old African American female admitted to the hospital with the diagnosis of acute cardiac rejection with refractory cardiogenic shock following heart transplantation for heart failure secondary to a primum atrial septal defect and collapsed mitral valve. The patient was in acute rejection and was treated with steroids and antithymocyte globulin without noted improvement. To improve falling oxygen saturations and hypotension the patient was intubated and supported with intravenous inotropes. An intra-aortic balloon was also inserted to augment support. Because of continued hemodynamic collapse a more advanced method for circulatory support was required. ECMO was initiated and felt to be a viable option with a plan for recovery.

A customized, heparin-bonded, transportable circuit was used for ECMO. The ECMO circuit consisted of a Biomedicus centrifugal pump and a Maxima Plasma Resistant Fibers Carmeda Coated Membrane Oxygenator (Medtronic, Minneapolis, MN). Percutaneous cannulation was achieved via the left femoral vein using a Medtronic 30/33 French Dual stage single venous catheter. A 10 French Bard arterial catheter was placed in the left distal femoral artery (for leg perfusion), and a 19 French arterial catheter was placed proximally to achieve flows of 3–4 liters per min. ECMO was maintained with an ACT of

Address correspondence to: Nicklett Johnston, RN BSN, CCP, Department of Cardiothoracic Surgery, University of Texas Southwestern Medical Center at Dallas, 5161 Harry Hines Boulevard, Dallas, TX 75390-8879. E-mail: johnstonr@sbcglobal.net
Received January 2002; accepted August 2002.

100–200 seconds with flows of 3–4 L/min fluctuating with volume requirements. The ECMO provided temporary support and allowed less aggressive mechanical ventilation, permitting rest to the lungs and heart. A slight increase of heart contractibility was noted, while the lungs continued to be less responsive. Venous saturations remained at 95% on ECMO, while continuing hemodynamic improvements, such as an increase of mean blood pressure and urinary output, were noted. Platelet counts decreased from 278 k/mm³ before ECMO to 28 k/mm³ on day 4 of ECMO (Figure 1). At this point, HIT was suspected because of the patient's extremely low platelet counts. To obtain a diagnosis of HIT, a blood specimen was sent for PF4 enzyme-linked immunosorbent assay (ELISA) analysis. The PF4 ELISA is a solid phase assay based on the reaction of patient antibodies. A positive result is confirmed by revealing an inhibition of antibody binding by heparin (2). The PF4 ELISA analysis has a 3–4 day holdup in responding, so treatment therapies must be continued while awaiting results. At this point, the patient continued to show an improvement of heart function, but the lungs persisted in pulmonary edema. Thus, it was felt a continuation of ECMO was required to uphold therapeutic treatment.

Preparations to use Argatroban were instituted to stop the progression of the thrombocytopenia. The elimination of all heparin exposure was initiated. Removal of all heparin line flushes, and all heparin-coated in-dwelling catheters were replaced with nonheparin-bonded catheters.

The ECMO circuit was exchanged for a nonheparin-coated circuit and membrane. The heparin drip was exchanged for Argatroban. A 10-mg bolus of Argatroban was given, and 2 mcg/kg/h drip was established to maintain blood levels. The Argatroban was monitored with ACTs and activated partial thrombin times (aPTT). The range of ACTs were 200–400, and aPTTs ranged from 80–90, with no sign of clot in the extracorporeal circuit. Blood products were given to maintain a hematocrit greater than 30%. Platelets were given to increase platelet level equal to or greater than 50,000. Intravenous inotropes continued, and the patient was sedated with a propofol drip. On day 6 of ECMO, attempts were made to discontinue the ECMO therapy. The ECMO flows were gradually decreased, while patient evaluation was ongoing. At the outset, flows were decreased from 4 to 3 L/min for 24 h. After the patient was evaluated and ascertained to be stable at a lower flow, the flow was decreased to 2 L/min (Figure 2). The ECMO flow remained at 2 L/min for another 24 h. Subsequently, the ECMO flow was then readjusted to 1–1.75 L/min during the last 48 h on ECMO. At these flows, the ACTs were maintained in the 300–400 range, with the aPTTs at 70s–80s. Episodic increases in the flow (2–3 L/min) were done to avoid stagnation of flow. The patient was separated from ECMO on day 10 to avert the increased risk of sepsis. The patient continued to remain on inotropic and ventilatory support. Slowly the patient continued to improve, and 3 weeks post-ECMO was transferred to a step down unit.

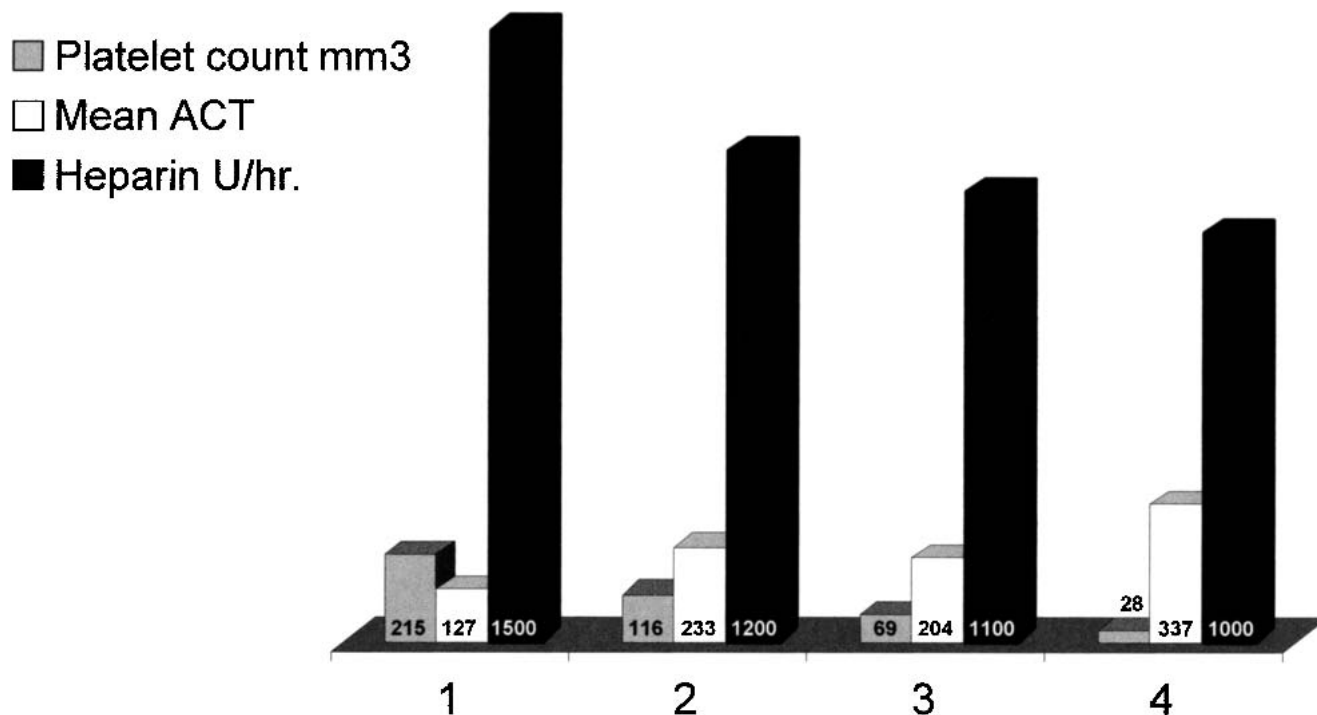


Figure 1. Heparin dose, ACTs, and platelet counts on 1–4 days before Argatroban use. ACT-activated clotting time U/h, units per hour.

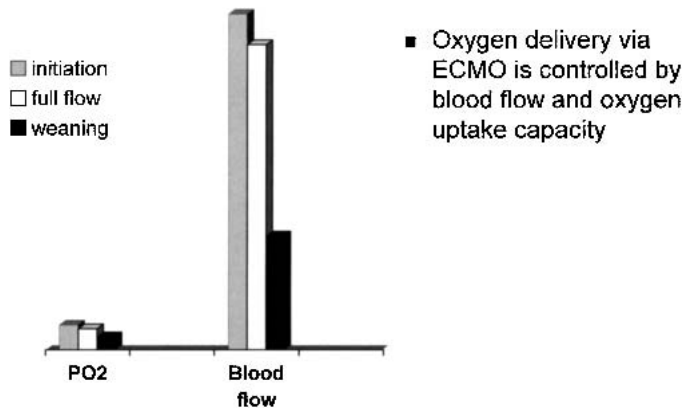


Figure 2. The PO₂ during the variations of flows during ECMO.

DISCUSSION

Patients who present with a platelet count that drops below 50% of the baseline value within the fifth day of heparin treatment are at risk of HIT (3). The patient in this case study elicited symptoms of HIT, but in fact, did not have the antibody. Therefore, the drop in platelet count was linked with the ECMO circuit and not considered to be a true HIT. The use of Argatroban in this case did not result in continual platelet count decline.

Argatroban blocks the activity of thrombin, and is the first synthetic direct inhibitor approved for the prevention and treatment of thrombosis in patients with HIT. Diagnosis of HIT can be challenging because of similarities to HIT and other syndromes, limitations of existing laboratory assays, and the presentation of clotting instead of bleeding (4). Argatroban's safety profile and efficacy were demonstrated in studies involving HIT patients. Argatroban therapy provided a 21% relative reduction in the risk of death, amputation, or new thrombosis and delayed the onset of these adverse effects (4). Bleeding is the most common adverse effect of Argatroban. This includes gastrointestinal and genitourinary bleeding (3). Results from laboratory assays to diagnose HIT often cause delays in beginning treatment, and heparin should be stopped once there is a suspicion of HIT. The risk of thrombus within the extracorporeal circuit, especially with low-flow perfusion, requires the use of anticoagulation.

Argatroban works by blocking the thrombin-induced platelet aggregation, and it does not cross react with HIT antibodies, a disadvantage of low-molecular weight heparin and danaparoid (5). Furthermore, Argatroban does not induce formation of antibodies that alter its clearance, which is a drawback of lepirudin (5). In comparing Argatroban with lepirudin, dosages do not have to be adjusted for patients with renal failure. Argatroban is metabolized in the liver; therefore, no dose adjustment is needed in patients with renal insufficiency. Dosage reduction is advised in patients with significant hepatic disease (3).

The dosing of Argatroban is based on patient weight. The recommended starting infusion rate is 2 (μg/kg/min); adjusted to achieve an aPTT of 1.5 to 3 times the baseline value (3). Adding an intravenous bolus of Argatroban, 200 to 300 μg, can help provide a rapid anticoagulant effect (1). Argatroban has a short half-life of about 15 minutes, so continuous intravenous administration is recommended for a constant anticoagulant effect (1).

Technical equipment has improved and become more simplified during the last decade, and with this improvement, there has been a growing experience with ECMO. A greater survival rate with adults progressing from less than 10% to a survival rate of greater than 80% has come about (6). These improved outcomes in adult ECMO are results of improved technology and better patient selection. ECMO has been shown to provide effective treatment for acute respiratory failure in adults. No consensus has been made for placing adults on ECMO for acute rejection status post-heart transplant. Left and right ventricular assist devices have been used to aid the heart in such situations, but ECMO has been tried for acute respiratory distress syndrome and not acute rejection associated with biventricular failure. Extracorporeal circulation used to aid the lungs can be effective if heart function is mechanically able to overcome the extracorporeal circulation and prevent pulmonary edema. When the lungs worsen during ECMO, usually it is attributable to a depressed heart function. When this occurs, the lungs will only improve if cardiac function improves. The provision of temporary support and less aggressive ventilation provided effective treatment in respiratory distress syndrome. (Figure 3).

CONCLUSION

ECMO provided a reprieve for a failing heart suffering from acute rejection. The course of treatment showed that ECMO was beneficial in acute rejection post-heart transplant. Acute pulmonary edema improved after contractility of the heart became stronger. The ECMO was complicated by thrombocytopenia and led to a suspicion of HIT. This was treated by the removal of heparin and the use of Argatroban. The Argatroban proved to be an effective alternate anticoagulant and helped to speed up platelet count recovery. Monitoring the anticoagulation range was not difficult, and the results of the aPTT and ACT gave an accurate range for treatment. The Argatroban also maintained anticoagulation during low-flow perfusion without thrombus formation in the extracorporeal circuit. Argatroban proved to be useful as an alternative anticoagulant and provided a lower risk to systemic thromboembolization and excessive blood loss while preserving the platelet count and plasma levels of fibrinogen. In this case of post-transplant organ rejection, ECMO proved to be a feasible mechanical support in aiding the patient to overcome

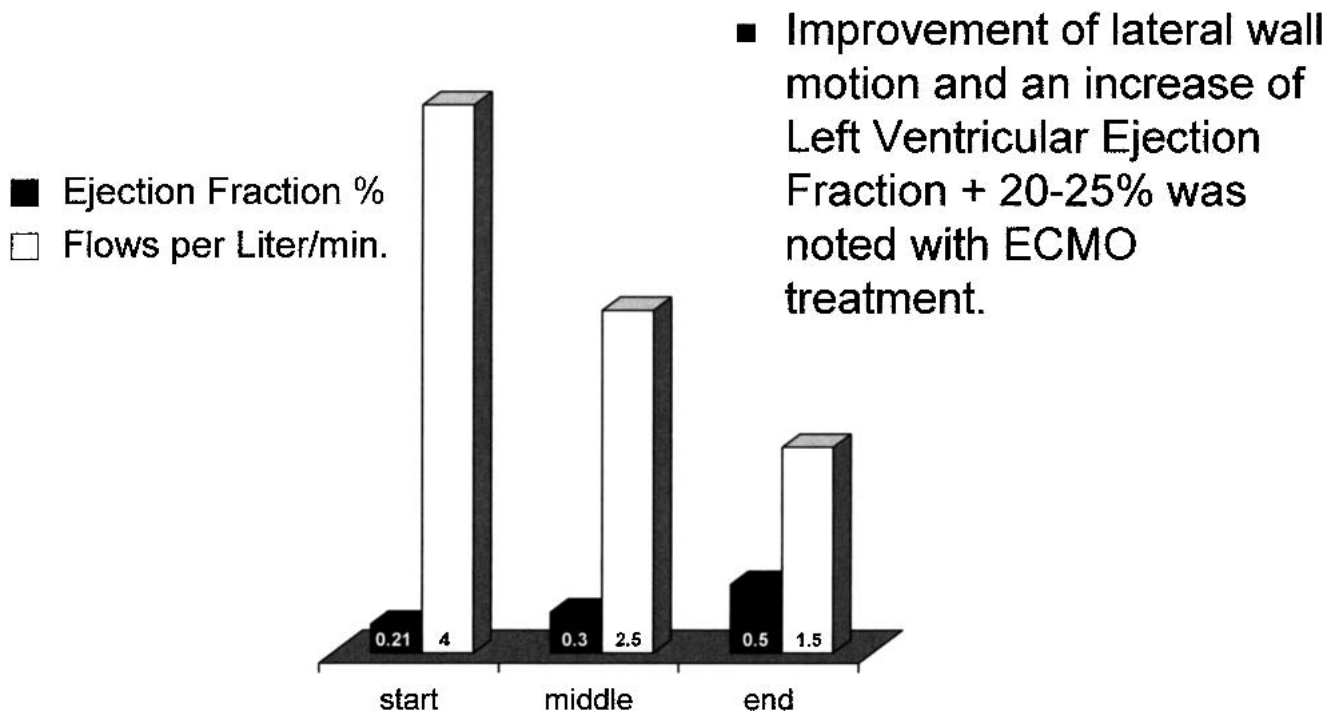


Figure 3. Heart function and blood flows during ECMO.

pump failure and respiratory distress. The use of the more invasive ventricular assist device was not an option with this particular patient and her recent transplanted heart. Utilization of percutaneous ECMO proved to be the treatment that allowed the patient to regain heart function and improve her respiratory status.

REFERENCES

1. Kawada T, Kitagawa G, Hoson M, Okada Y, Shiinyra J. Clinical application of Agatroban as an alternative anticoagulant for extracorporeal circulation. *Blood Stasis Thromb.* 2000;14:445-57.
2. Visentin G, Moghaddam M, Collins J, McFarland J, Aster R. Antibodies associated with heparin-induced thrombocytopenia report conformation changes in platelet factor four induced by linear, polyanionic compounds. *Blood.* 1997;90:460a.
3. Deitcher S. Heparin-induced thrombocytopenia: Pathogenesis, management, and prevention. *Formulary.* 2001;36:26-41.
4. Beyzarov E. Anticoagulant approved for heparin complication. *Drug Topics.* 2001;144:14-6.
5. Wallis L, Berkowitz S, Matthai W, et al. Argatroban anticoagulant therapy in patients with heparin-induced thrombocytopenia. *Circulation.* 2001;103:1838-46.
6. King P, Rosalion A, McMillan J, Buist M, Holmes P. Extracorporeal membrane oxygenation in pregnancy. *Lancet.* 2000;356:45-6.