

Argatroban Usage For Anticoagulation for ECMO on a Post-Cardiac Patient with Heparin-Induced Thrombocytopenia

Brian Mejak, BS, CCP; Carmen Giacomuzzi, BSN, CCP; Eileen Heller, BS, CCP;
Xiaomang You, PhD, CCP; Ross Ungerleider, MD; Irving Shen, MD; Lynn Boshkov, MD

Doernbecher Children's Hospital, Oregon Health & Science University, Portland, Oregon

Presented at the 19th Annual CNMC Symposium for ECMO & the Advanced Therapies for Respiratory Failure, Keystone, Colorado, February 2003

Abstract: We report a post-Norwood Stage I patient requiring ECMO support using Argatroban as an anticoagulant following diagnosis of heparin-induced thrombocytopenia (HIT). A 2.6 kg female was born with hypoplastic left heart syndrome and underwent a Norwood Stage I operation on day 4 of life. The patient weaned off cardiopulmonary bypass with no complications and was routinely placed on a ventricular assist device (VAD) for 3 days. Heparin was infused at a rate of 16–32 IU/kg/h to maintain an ACT of 160–180 seconds. Two days after VAD termination, the patient was placed on continuous veno-

veno hemofiltration (CVVH). Shortly after CVVH, the patient was diagnosed with HIT and placed on an Argatroban infusion. Five days later, a VAD and subsequent ECMO was used because of decreasing left ventricular function, gross body edema, and poor renal function. This case report summarizes the use of Argatroban during VAD and ECMO support for a patient diagnosed with HIT. **Keywords:** Argatroban, anticoagulant, extracorporeal membrane oxygenation (ECMO). *JECT. 2004;36:178–181*

Heparin is an anticoagulant used in many areas of the health care system, such as operating rooms, intensive care units, dialysis units, and emergency rooms. A potentially lethal side effect of heparin is heparin-induced thrombocytopenia (HIT). HIT occurs when the immune system develops antibodies to the heparin/platelet factor 4 complex after an exposure or prolonged exposure to heparin. The effects of the presence of these antibodies can be platelet clumping, dramatic drops in platelet counts, and arterial and venous thrombi. This condition is even more serious when patients need extracorporeal support such as cardiopulmonary bypass, extracorporeal membrane oxygenation (ECMO), or dialysis. Alternative drugs to heparin must be used to obtain anticoagulation during extracorporeal support. We report successful use of Argatroban as an anticoagulant during ECMO support for a postoperative cardiac patient.

CASE REPORT

A 2.6-kg patient was born with hypoplastic left heart syndrome and underwent a Norwood Stage I operation on day 4 of life. The operation required full systemic heparinization and cardiopulmonary bypass with intermittent periods of circulatory arrest. The patient was weaned off cardiopulmonary bypass with no complications (Figure 1) and was routinely placed on a ventricular assist device (VAD). An 8 French aortic cannula (Medtronic, Minneapolis, MN) was placed in the proximal aorta and a 20 French venous Medtronic cannula was placed in the right atrium. The VAD circuit (Figure 2) consists of a HL-20 roller pump (Jostra, Hirrlingen, Germany) with interfaced pressure transducing, a Medtronic silicone bladder, a Medtronic Ectotherm II heat exchanger, a venous saturation/hematocrit cuvette and an arterial blood gas cuvette (Terumo Cardiovascular, Ann Arbor, MI). Heparin was used as an anticoagulant at an infusion rate of 16–32 IU/kg/h to maintain an activated clotting time (ACT) of 160–180 seconds. The patient received daily transfusions of fresh frozen plasma (FFP), platelets, and cryoprecipitate to maintain adequate international normalized ratios

Address correspondence to: Brian Mejak, CCP, Pediatric Perfusion, Doernbecher Children's Hospital, Oregon Health & Science University, DCH85, 3181 S.W. Sam Jackson Park Road, Portland, OR 97239. E-mail: mejakb@ohsu.edu

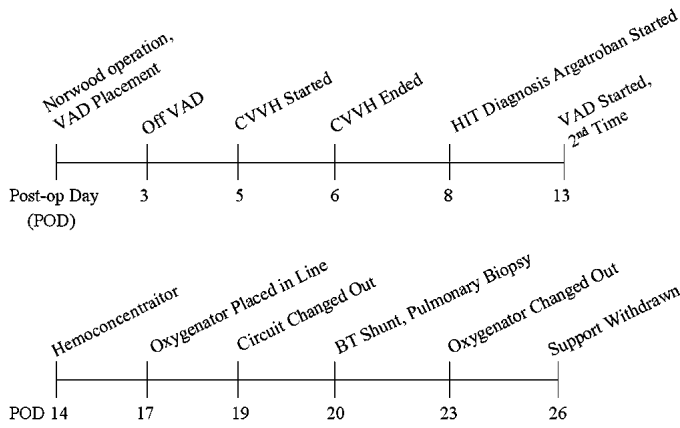


Figure 1. Timeline of events.

(INRs), platelet counts, and fibrinogen levels, respectively. The patient was supported for 64 hours and weaned from ventricular assist without complication on postop day 3.

On postop day 5, the patient was placed on continuous veno-veno hemofiltration (CVVH) to mobilize fluids. Upon initiation of CVVH and partial heparinization, multiple lines appeared clotted, and the platelet count had dropped to 53,000 from the previous day's count of 185,000. Hematology was consulted, and coagulation tests were performed to find the source of clotting, and CVVH was discontinued. AT III levels, protein C, and protein S were within normal ranges for the patient's age. In addition, HIT assays were negative for the next 2 days. Three days after CVVH initiation and after a weak positive assay for HIT, the patient was treated with Argatroban. The patient was given an initial bolus of 200 µg/kg followed by an infusion of 3.0–7.5 µg/kg/min, which adequately maintained a target prothrombin time (PTT) between 60 and 80 seconds. Over the next several days, the patient re-

quired increasing inotropic support as well as nitric oxide to decrease pulmonary artery pressures. The patient was taken to the catheterization lab the following day and was found to have minimal clot in the innominate and distal inferior vena cava.

On postop day 13, the decision was made to place the patient back on VAD support to alleviate gross body edema, acute renal failure, and decreasing left ventricular function. The circuit setup was identical to the previous VAD run. The prime consisted of normosol, 350 mL of washed red blood cells, 50 mL of fresh frozen plasma, 50 mL of 25% albumin, 30 mL of sodium bicarbonate (1 mEq/mL), 400 mg of calcium gluconate, and 50 µg of Argatroban. An ACT of 614 seconds was measured from a blood sample from the circuit before ECMO initiation. Argatroban was discontinued 4 hours before VAD initiation to allow the coagulation parameters to normalize. Then, an Argatroban infusion rate of 0.2 µg/kg/min was started, which resulted in a patient ACT of 218 seconds, and VAD support was initiated. An HPH-400TS hemoconcentrator (Minntech, Minneapolis, MN) was placed in the circuit to remove excess volume. ACT levels were maintained between 160 and 180 seconds. INRs, fibrinogen levels, and activated PTT were drawn every 4 hours and treated as needed.

On day 4 of VAD support, a Medtronic 800 silicone membrane oxygenator was placed in the circuit at the ¼–¼ connector site (Figure 2) because of pulmonary dysfunction, of unclear etiology. ACT target levels were raised to 200–220 seconds. Argatroban infusion rates ranged from 0.05 to 1.8 µg/kg/min. Figure 3 shows a comparison between PTTs, ACTs, and Argatroban infusion rates while on ECMO. On day 7 of support, the entire circuit was changed out because of numerous fibrin strands and clots, and 4 days later, the oxygenator was changed out because of presence of clots and a decreasing ability to oxygenate. On day 8 of support, the patient was taken to the operating room for a B-T shunt revision and a pulmonary biopsy. The pulmonary biopsy showed

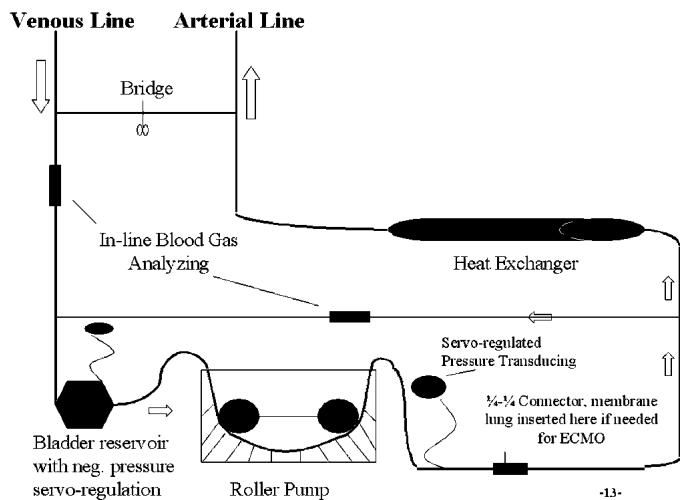


Figure 2. VAD/ECMO circuit.

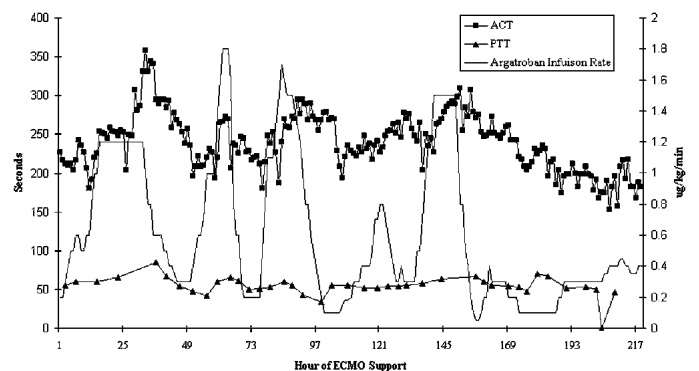


Figure 3. ACT and PTT vs. Argatroban infusion rate during ECMO.

thrombus present in a venule 10–14 days old. In the clinical timeline of events, this diagnosis places the formation of the thrombus around the time of re-exposure to heparin for CVVH. Tissue plasminogen activator (tPA) was given on day 12 of support in an attempt to reduce or eliminate these thrombus formations but discontinued because of excessive bleeding. During tPA administration, anticoagulation protocols were not changed, but the Argatroban infusion level decreased to 0.1 $\mu\text{g}/\text{kg}/\text{min}$, and ACTs were kept in range. ECMO support was withdrawn 2 days later, and the patient expired shortly thereafter.

DISCUSSION

HIT can present as a difficult diagnosis for clinicians. In fact, it is our belief that HIT is frequently overlooked or under-recognized in neonates and infants. One reason for this is the variability of the HIT assay being used. There are two types of assays, quantitative and functional. Functional assays detect patient platelet activation *in vitro* in the presence of therapeutic levels of heparin concentration. We use functional assays because we feel they are more reliable, although these tests may take more time to obtain a positive HIT test. Quantitative or antigen ELISA based assay tests were not used because studies have shown that as much as 50% of post-cardiac patients will yield positive HIT-IgG antibody tests (1). If these assays were solely relied on for diagnosis, unnecessary treatment for HIT would occur more often. Clinical observations still remain the gold standard for establishing a clinical diagnosis of HIT. Clinical existence includes thrombosis formation 5–14 days following heparin exposure, reduction in platelet count by 50% of baseline or less than 100,000, and recovery of platelet count after discontinuation of heparin (2).

Argatroban is approved by the FDA for both prophylactic and treatment of thrombosis associated with HIT. Argatroban has the ability to inhibit both clot-bound and soluble thrombin (3). The half-life of Argatroban is 39–51 minutes, and it is metabolized in the liver.

DosinDd There is little information in the literature currently on dosing protocols for Argatroban usage with pediatrics or neonates. One Argatroban protocol was developed for adults undergoing left-heart bypass suggests an intravenous bolus of 200–300 $\mu\text{g}/\text{kg}$ and an infusion rate of 2 $\mu\text{g}/\text{kg}/\text{min}$ (4). The 200 $\mu\text{g}/\text{kg}$ bolus for this patient overshoot the PTT target range of 60–80 seconds, so we suggest a bolus of 100–150 $\mu\text{g}/\text{kg}$ for a loading dose on neonatal or pediatric patients. The patient was not given a loading dose at the time of ECMO initiation because the ACT was 218 seconds from ongoing Argatroban therapy. In addition to PTTs, ACTs were viewed as an effective method to assess anticoagulation because ACTs correlate

well with Argatroban plasma concentrations (5). Figure 3 tracks the patient's PTT and ACT measurements and compares them with the Argatroban infusion rates. This graph demonstrates how infusion rates may affect ACT and PTT measurements and also exhibits some lag times in effectiveness.

Other case reports suggest Argatroban can be used as an anticoagulant during adult ECMO (6) and pediatric ECMO (4). Also, Argatroban was used successfully as a substitute for heparin in an emergency cardiopulmonary bypass operation, but the patient required many transfusions of red blood cells, cryoprecipitate, and fresh frozen plasma following termination of bypass (7). The patient received no further transfusions after the 24-hour postop period and survived to discharge. In another study, Argatroban was compared with heparin in a dog bypass model for 120 minutes in which the Argatroban group showed lower levels of fibrin degradation products, lower thrombin-antithrombin III complexes, and higher platelet counts when compared to heparin (8). We suggest Argatroban can be used as a successful anticoagulant only when heparin is not available or contraindicated as with HIT. With the exception of the above mentioned, very few Argatroban studies exist focusing on the use of Argatroban on patients and extracorporeal surfaces. It is still optimal if surgery can be delayed for 100 days after discontinuation of heparin because heparin-dependent antibodies do not invariably reappear with subsequent re-exposure (9). In such cases, heparin use should be discontinued immediately following cardiopulmonary bypass.

There are still too many unknowns to consider using Argatroban as a replacement for heparin. No reversal agent is currently available, so if Argatroban is used then clinicians must wait for hepatic clearance of the drug. In addition, Argatroban affects clot bound thrombin and it is not known to what extent it will interfere with the clotting cascade and healing of the surgical wounds. Last, studies must be performed assessing interactions between Argatroban and other drugs used in extracorporeal circulation, such as aprotinin, amicar, and albumin.

In conclusion, the clinical findings in this case suggest the patient developed heparin-induced thrombocytopenia and subsequent thrombosis at the time of re-exposure to heparin for the purpose of CVVH. Argatroban, an alternative to heparin, can provide a safe and effective means of anticoagulation while on ECMO. The diagnosis, experience, and lack of research in this area are challenges clinicians must overcome.

REFERENCES

1. Warkentin T, Sheppard J, Horsewood P, Simpson P, Moore J, Kelton J. Impact of the patient population on the risk for heparin-induced thrombocytopenia. *Blood*. 2000;96:1703–8.

2. Aburahma AF, Malik FS, Boland JP. Heparin-induced thrombocytopenia with thrombotic complications. *W Va Med J*. 1992;88:95–100.
3. Schwarz R, Becker J, Brooks R, et al. The preclinical and clinical pharmacology of Novastan (Argatroban): A small-molecule, direct thrombin inhibitor. *Clin Appl Thromb/Hemost*. 1997;3:1–15.
4. Kawada T, Kitagawa H, Hoson M, Okada Y, Shiomura J. Clinical application of Argatroban as an alternative anticoagulant for extracorporeal circulation. *Blood Stasis Thromb*. 2000;14:445–57.
5. Walenga J, Fasanella AR, Iqbal O, et al. Coagulation laboratory testing in patients treated with Argatroban. *Semin Thromb Hemostas*. 1999;25:61–6.
6. Johnston N, Wait M, Huber L. Argatroban in adult extracorporeal membrane oxygenation. *J Extra Corpor Technol*. 2002;34:281–4.
7. Edwards J, Hamby J, Worrall N. Successful use of Argatroban as a heparin substitute during cardiopulmonary bypass: Heparin-induced thrombocytopenia in a high-risk cardiac surgical patient. *Ann Thorac Surg*. 2003;75:1622–4.
8. Sakai M, Ohteki H, Narita Y, Naitoh K, Natsuaki M, Itoh T. Argatroban as a potential anticoagulant in cardiopulmonary bypass-studies in a dog model. *Cardiovasc Surg*. 1999;7:187–94.
9. Warkentin T, Kelton J. Temporal aspects of heparin-induced thrombocytopenia. *N Engl J Med*. 2001;344:1286–92.