

## Case Reports

# Novoseven Use in a Non-Cardiac Pediatric ECMO Patient With Uncontrolled Bleeding

Thomas J. Preston, BS, RRT; Vincent F. Olshove Jr., BS, CCP; Onsy Ayad, MD;  
Kathleen K. Nicol, MD; Jeffrey B. Riley, MHPE

*Nationwide Children's Hospital, Columbus Ohio Circulation Technology Division, The Ohio State University, Columbus, Ohio*

Presented at the 22nd Annual Children's National Medical Center (CNMC) Symposium, Extracorporeal Membrane Oxygenation and Advanced Therapies for Respiratory Failure, Keystone, Colorado, February 26 to March 2, 2006.

**Abstract:** Despite the presence of normal coagulation values, refractory bleeding during extracorporeal membrane oxygenation (ECMO) is encountered. Occasionally, hemostasis is not achieved through traditional techniques including surgical exploration, anti-fibrinolytics, increasing fibrinogen level, increasing platelet counts, and decreasing activated clotting time (ACT). We report the case of an infant on veno-arterial ECMO for respiratory syncytial virus with severe bleeding and the use of recombinant activated factor VII (rFVIIa; NovoSeven; Novo Nordisk, Copenhagen, Denmark). This was a retrospective review of the patient's medical records, laboratory values, and chest radiographs. rFVIIa was given to this patient on two separate occasions for bleeding unresponsive to traditional bleeding

management. On both occasions, the patient's blood loss returned to zero within 20 minutes of administration and remained there for a minimum of 4 days. Continued bleeding on ECMO unresponsive to current medical management may be an indication for rFVIIa. However, rFVIIa should not be administered without first considering the ECMO circuits conditions to include presence of clot, and documentation of circuit pressures, which, after rFVIIa, may be the first indication of intra-oxygenator clot formation. Additionally, rFVIIa should not be a first-line treatment until continued studies allow for approved use in this patient population. **Keywords:** extracorporeal membrane oxygenation, NovoSeven, bleeding, factor VIIa. *JECT. 2008;40:123–126*

Successful extracorporeal membrane oxygenation (ECMO) requires balancing coagulation and anti-coagulation while avoiding circuit compromise or causing the patient to hemorrhage. Bleeding is a recognized complication with post-cardiotomy ECMO, and achieving hemostasis can be a challenge. Despite the presence of normal to supra-normal coagulation values, refractory bleeding may still be encountered. Severe bleeding in ECMO is difficult to manage when traditional techniques for bleeding have failed despite maximal effort including: surgical exploration, elevating platelet counts, increasing fibrinogen levels, use of anti-fibrinolytics, and a decreasing target activated clotting time (ACT) (1). Currently, recombinant

activated human factor VIIa (rFVIIa; NovoSeven; Novo Nordisk, Copenhagen, Denmark) is gaining popularity in this patient category (1–6). rFVIIa is currently approved by the Food and Drug Administration for use in hemophilia A or B patients with inhibitors to factor VIII or factor IX for the treatment of bleeding episodes and those patients that are factor VII deficient (manufacturers instructions for use, 2006). We report the case of an infant on veno-arterial ECMO for pulmonary support with refractory bleeding that was successfully treated with rFVIIa.

## CASE REPORT

A 6-week old, 4.5-kg male patient was admitted to the pulmonary service with increasing work of breathing and a positive culture for respiratory syncytial virus (RSV). Within hours, the patient was transferred to the pediatric

Address correspondence to: Thomas Preston, 700 Children's Drive, Columbus, OH 43205. E-mail: Thomas.Preston@nationwidechildrens.org  
The senior author has stated that authors have reported no material, financial or other relationship with any healthcare-related business or other entity whose products or services are discussed in this paper.

intensive care unit because of respiratory failure. He was intubated and mechanically ventilated for 35 hours before conversion to high-frequency oscillatory ventilation (HFOV) as a result of progressive hypoxemia. On hospital day 4, the patient developed a left pneumothorax, with subsequent deterioration, despite placement of a pig-tailed catheter, leading to the initiation of veno-arterial ECMO and heparin anti-coagulation.

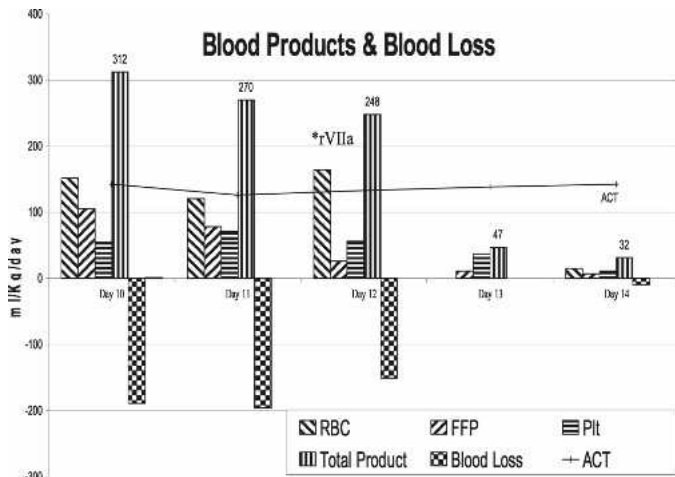
On ECMO, the patient was stable but remained on HFOV with settings as follows: Hertz, 15; amplitude, 38 cmH<sub>2</sub>O; mean airway pressure, 17 cmH<sub>2</sub>O; F<sub>i</sub>O<sub>2</sub>, 0.21; ECMO pump flow, 111 mL/kg/min. On hospital day 6 (ECMO day 3), the patient developed a (second) left tension pneumothorax. A 16-F Argyle catheter was placed to reduce the pneumothorax, with no significant bleeding noted from the site or chest tube. On hospital day 7 (ECMO day 4), bloody output from the chest tube was 10–40 mL/h (2–7 mL/kg/h). There was no significant bleeding or oozing from the cannulation sites. Aminocaproic acid (Amicar, Abbott Laboratories, Chicago, IL) was started at 30 mg/kg/h after an initial loading dose of 100 mg/kg. On hospital days 8–9 (ECMO days 5–6), bloody output from the chest tube had increased to 10–60 mL/h (2–13 mL/kg/h) despite the use of aminocaproic acid over the 5 previous days. Fibrin degradation products (FDPs) checked on this day were negative. The bloody output continued, and on hospital days 10–11 (ECMO days 7–8), it was 20–80 mL/h (4–18 mL/kg/h). The patient's coagulation studies during the time of the worsening bleeding were as follows: prothrombin time (PT), 12 seconds; activated partial thromboplastin time (aPTT), 92 seconds; platelet count, 142,000 mm<sup>3</sup>; fibrinogen, 303 mg/dL (Table 1).

On hospital day 12 (ECMO day 9), a multi-disciplinary team discussed two approaches for the management of this continued bleeding: (i) surgical exploration and (ii) off-label administration of rFVIIa. Each of these options had potential complications including, but not limited to, surgical exploration may not produce the desired reduction in bleeding, because a surgical cause for bleeding is found in only 50% of patients explored, and potentially may increase the bleeding secondary to further tissue damage, rFVIIa may cause circuit or patient thrombosis

secondary to the hypercoagulable state present in ECMO patients from, among other things, the shear stress, turbulence, and mechanical injury to the blood and tissue factor expressed from vascular injury (1,6). Before the multi-disciplinary meeting, a literature review provided little literature regarding rFVIIa in conjunction with ECMO. One report described fatal thrombosis of the ECMO circuit when activated prothrombin complex concentrate (APCC) was administered to the ECMO circuit 6 hours after the last dose of rFVIIa (4). The decision was made to administer rFVIIa off-label using the ECMO circuit before any surgical exploration. Surgical exploration remained the alternative plan in the event rFVIIa was unsuccessful in controlling blood loss. At this point, the patient had received the following over the preceding 96 hours to no avail: packed red blood cells, 3475 mL (772 mL/kg); fresh frozen plasma, 3020 mL (671 mL/kg); platelets, 1032 mL (229 mL/kg). Bloody output from the chest tube was 30–90 mL/h (7–20 mL/kg/h). Before administration, a quantitative factor VII level was drawn and reported as 149% (reference range, 20–70%) activity. Despite the absence of clot within the ECMO circuit, a second ECMO circuit was setup, primed with crystalloid, and remained outside the patient's room recirculating throughout and for several hours after rFVIIa administration. Because of the reported variability in dosing regimens (20–125 µg/kg), it was decided to give this patient a total of 90 µm/kg of rFVIIa (1,2,6). The dose was divided into two 45-µm/kg aliquots and administered to the ECMO circuit 2 hours after the aminocaproic acid was stopped [the elimination (T<sub>1/2</sub>) of Amicar is 2 hours]. Within 20 minutes of the initial 45-µm/kg aliquot, the output from both chest tubes had dropped to zero. The second 45-µg/kg aliquot was administered to the circuit 1 hour after completion of the first. The chest tube output remained zero, and chest radiographs over the next 4 days failed to show hemothoraces. Likewise, there was no indication of peripheral clot formation, because distal pulses and capillary refill remained unchanged. Thorough examination of the circuit during that time showed no evidence of significant fibrin deposition or clots. Additionally, the ECMO circuit pre/post oxygenator pressures did not vary after rFVIIa administration. Figure 1 shows the day-to-

**Table 1.** ACT, PT, PTT, \*rFVIIa, and Xa.

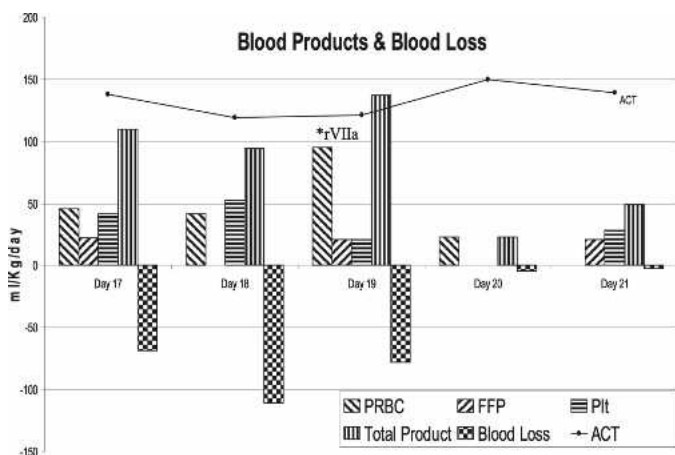
	Day 7	Day 8	Day 9	Day 10	Day 11	Day 12*	Day 13	Day 14
PT (s)	13.1	12.8	12	12.6	13.1	9.3	12.8	12.4
PTT (s)	249	249	130	211	66	212	249	113
INR	1.28	1.22	1.1	1.2	1.28	0.69	1.23	1.17
ACT (s) (hemochron JR, ACT+ cartridge)	149	144	138	142	126	133	138	142
Heparin (units/kg/h)	49	49	30	40	45	40	49.3	49.4
Xa (U/mL)		0.7	0.8	0.5	0.5	0.8		
Fibrinogen (mg%)	231	289	262	200	279	351	323	412
Platelets (K/mm <sup>3</sup> )	143	104	164	141	158	126	114	118



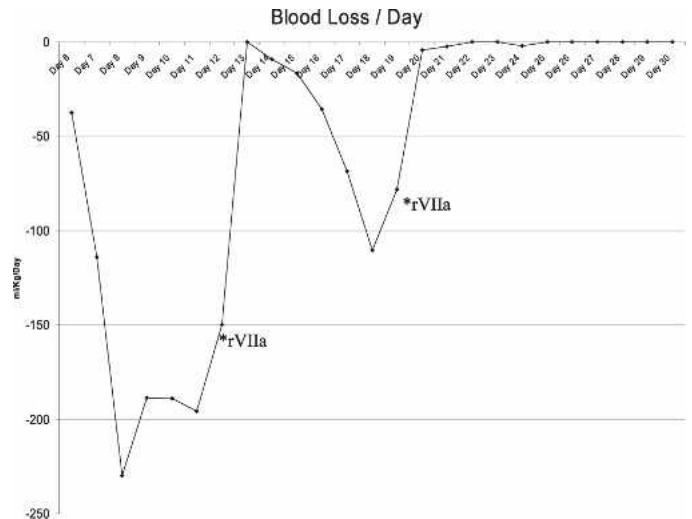
**Figure 1.** ACT, blood loss (blood lost during the previous 24 hours), FFP, platelets (Plt), PRBCs, total product (summary of all blood or blood products administered in the previous 24 hours excluding albumin), and \*rFVIIa.

day blood loss and product administration for the 2 days preceding rFVIIa administration and 2 days after administration.

The patient remained clinically stable; however, on hospital day 16 (ECMO day 13), the patient's bleeding began again from the left chest tubes at a rate of 2–10 mL/h (.5–2 mL/kg/h). This rate of output continued until hospital day 19 (ECMO day 16), when the bleeding increased to 10–30 mL/h (2–7 mL/kg/h), and the patient was again treated with rFVIIa as previously described. Figure 2 shows the day-to-day blood loss and product administration for the 2 days preceding the second round of rFVIIa administration and 2 days after administration. Once again, chest tube output returned to zero, where it remained throughout the remainder of the ECMO course. Figure 3 shows the blood



**Figure 2.** ACT, blood loss (blood lost during the previous 24 hours), FFP, platelets (Plt), PRBCs, total product (summary of all blood or blood products administered in the previous 24 hours excluding albumin), and \*rFVIIa.



**Figure 3.** \*rFVIIa.

loss and rFVIIa administration while on ECMO. The ECMO circuit was visually inspected and pre/post-membrane pressures were charted every hour. Visual inspection and circuit pressures showed that the circuit remained macro-clot-free throughout the ECMO run. The patient was weaned off ECMO on hospital day 28 and discharged home on hospital day 66. At discharge, the patient was receiving oxygen through a nasal cannula at .3 L/min and naso-jejunal feeds. The head ultrasound remained normal. There was no evidence of pulmonary hypertension, and he was discharged on the following medications: Lasix (Hospira Inc., Lake Forest, IL), Albuterol (Armstrong Pharmaceuticals, West Roxbury, MA), and Budesonide (AstraZenaca, Wilmington, DE).

**COMMENT**

Rare reports document the use of rFVIIa in ECMO patients. The use of rFVIIa in the setting of uncontrollable severe bleeding during ECMO seemed to be effective in achieving hemostatic control in this patient. Despite the presence of an elevated quantitative factor VII level, this patient responded to treatment with rFVIIa, and rFVIIa should be considered in similar patients. However, rFVIIa should not be administered without consideration of the potentially severe consequences, which include clot formation, total circuit failure, extremity hypoperfusion with the potential for amputation, and death.

A review of the current literature related to the use of rFVIIa in the presence of severe bleeding during ECMO/ cardiopulmonary support yielded varied results (1–8). Unfortunately, most of the literature surrounding rFVIIa use is in the form of individual case reports, and the use for these patients has not been validated with a prospective randomized controlled trial because of both cost and con-

sequence. Recently Agarwal et al. (6) reported thrombosis complications in 25% of the patients receiving rFVIIa while on ECMO. A retrospective review from their institution discussed an increase in the potential for thrombosis in (i) patients bleeding from multiple sites and (ii) within circuits with preexisting clot before rFVIIa administration (6). Therefore, use of rFVIIa should be carefully weighed against the potential consequences before administration in the ECMO patient. Extreme caution and vigilance must accompany its use in patients with multi-site bleeding, extremity vessel damage inherent to multi-attempt line placement, and ECMO circuits containing clot formation before rFVIIa administration, because these groups have shown an increase in post-administration complications. In November 2005, Novo Nordisk released new adverse event warnings regarding the use of rFVIIa. These included increased risks of thrombotic events caused by circulating tissue factor or predisposing coagulopathy in patients with concurrent disseminated intravascular coagulation, crush injury, septicemia, advanced atherosclerotic disease, or concomitant treatment with activated or non-activated prothrombin complex concentrates (manufacturers' instructions for use, October 3, 2005).

## REFERENCES

1. Wittenstein B, Ng C, Ravn H, Goldman A. Recombinant factor VII for severe bleeding during extracorporeal membrane oxygenation following open heart surgery. *Pediatr Crit Care Med.* 2005;6:473-6.
2. Murkin JM. A novel hemostatic agent: the potential role of recombinant activated factor VII (rFVIIa) in anesthetic practice. *Can J Anesth.* 2002;49:521-6.
3. Dominguez TE, Mitchell M, Friess SH, et al. Use of recombinant factor VIIa for refractory hemorrhage during extracorporeal membrane oxygenation. *Pediatr Crit Care Med.* 2005;6:348-51.
4. Diprose P, Herbertson MJ, Shaughnessy DO, Gill RS. Activated recombinant factor VII after cardiopulmonary bypass reduces allogeneic transfusion in complex non-coronary cardiac surgery: randomized double-blind placebo-controlled pilot study. *Br J Anesth.* 2005;95:596-602.
5. Brose S, Sirbu H, Engel M, Kuhlen R, Autschbach R. Successful use of recombinant factor VIIa in a patient with intractable bleeding during extra-corporeal membrane oxygenation. *Thorac Cardiovasc Surg.* 2005;53:389-90.
6. Agarwal HS, Bennett JE, Churchwell KB, et al. Recombinant factor seven therapy for postoperative bleeding in neonatal and pediatric cardiac surgery. *Ann Thorac Surg.* 2007;84:161-9.
7. Bui JD, Despotis GD, Trulock EP, Patterson GA, Goodnough LT. Fatal thrombosis after administration of activated prothrombin complex concentrates in a patient supported by extracorporeal membrane oxygenation who had received activated recombinant factor VII. *J Thorac Cardiovasc Surg.* 2002;124:852-4.
8. O'Connell KA, Wood JJ, Wise RP, Lozier JN, Braun MM. Thromboembolic adverse events after use of recombinant human coagulation factor VIIa. *JAMA.* 2006;295:293-8.