

# Extracorporeal Membrane Oxygenation for the Management of Respiratory Failure Caused by Diffuse Alveolar Hemorrhage

Zhen Guo, MD;\* Xin Li, MD;\* Li-yan Jiang, MD;† Ling-feng Xu, MD\*

\*Department of Extracorporeal Circulation, and †Department of Respiratory Diseases, Shanghai Chest Hospital Affiliated to Shanghai Jiao Tong University, Shanghai, China

**Abstract:** Extracorporeal membrane oxygenation (ECMO) was developed as a supportive therapy to treat severe respiratory failure. When conventional mechanical ventilation has failed or when there is not enough time to treat the pathology, ECMO has the potential to sustain life. In this report, successful use of ECMO to support an adult patient with antineutrophil

cytoplasmic antibody (ANCA)-associated systemic vasculitides complicated by severe respiratory failure caused by diffuse alveolar hemorrhage will be discussed. **Keywords:** extracorporeal membrane oxygenation, diffuse alveolar hemorrhage, systemic vasculitides, respiratory failure. *JECT. 2009;41:37–40*

Systemic vasculitides encompasses a large group of inflammatory diseases affecting blood vessels of various sizes. These diseases have a suggested or proven immunopathogenesis that can affect various organ systems. Organs commonly involved include the lungs and kidneys. Although rare, diffuse alveolar hemorrhage is an important complication, because it is associated with a high mortality rate. Extracorporeal membrane oxygenation (ECMO) was developed to treat severe respiratory failure when conventional mechanical ventilation has failed or when there is not enough time to treat the underlying pathology. A case study of successful ECMO treatment for a patient diagnosed with antineutrophil cytoplasmic antibody (ANCA)-associated systemic vasculitides, further complicated by severe respiratory failure caused by diffuse alveolar hemorrhage, will be discussed.

## CASE REPORT

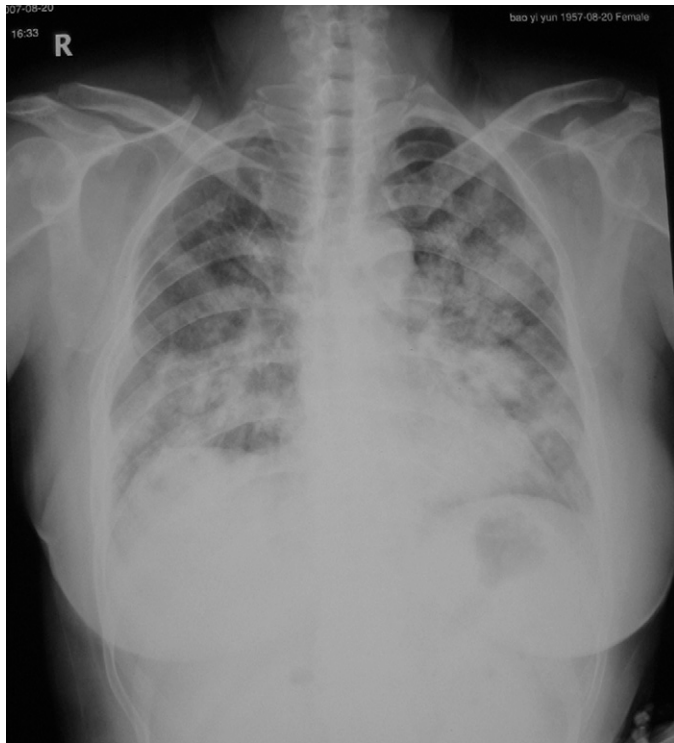
A 51-year-old Chinese woman presented at the emergency department of the Shanghai Chest Hospital with hemoptysis and dyspnea. The patient had a history of a cough and bloody sputum for 1 month before admission and had previously been treated empirically for

community acquired pneumonia. On physical examination, the patient's temperature was 37.9°C, heart rate was 90 beats/min, blood pressure was 115/71 mmHg, and respiratory rate was 28 breaths/min. The patient's conjunctiva and nail beds were pale. On auscultation, crackles were heard bilaterally. Cardiovascular, abdominal, extremity, musculoskeletal, and neurologic examinations were normal. The chest radiograph (Figure 1) showed bilateral alveolar opacities. Laboratory results on admission included the following: hemoglobin, 10.3 g/dL; hematocrit, 30.9%; albumin, 3.9 g/dL; C-reactive protein, 23.90 mg/L; lactate dehydrogenase, 326 units/L; rheumatoid factor, 13.72 ng/mL (reference range, 0–10 ng/mL); white blood cell count, 16,200 cells/ $\mu$ L; significant hematuria, 508 red blood cells per high-power field). The blood levels of glutamate-pyruvate transaminase, glutamic-oxalacetic transaminase, urea nitrogen, creatinine, electrolytes, glucose, and total bilirubin were normal. Arterial blood gas analysis found a pH of 7.28, a  $P_{CO_2}$  of 51.1 mmHg, a  $P_{O_2}$  of 41.4 mmHg, and a  $SaO_2$  of 56.2%.

On the first day of admission, the patient was treated with 500 mg methylprednisolone and 200 mg cyclophosphamide intravenously. Once on oxygen via face mask, the patient's  $P_{O_2}$  increased to 83.6 mmHg. The patient had severe hemoptysis during the first night, and arterial blood gases were measured at a pH of 7.31,  $P_{CO_2}$  of 48.0 mmHg,  $P_{O_2}$  of 51.1 mmHg, and a drop in  $SaO_2$  to 50.2% and hemoglobin of 7.1 g/dL. The patient was intubated the second night after worsening hypoxemia ( $P_{O_2}$  to 43 mmHg). Despite a positive end-expiratory pressure (PEEP) of 15  $cmH_2O$  and a fraction of inspired oxygen ( $FiO_2$ ) of 1.0, the patient's oxygen saturations

Address correspondence to: Xin Li, MD, Department of Extracorporeal Circulation, No. 241, West Huaihai Road, Shanghai 200030, China. E-mail: leex21@hotmail.com

The senior author has stated that authors have reported no material, financial or other relationship with any healthcare-related business or other entity whose products or services are discussed in this paper.



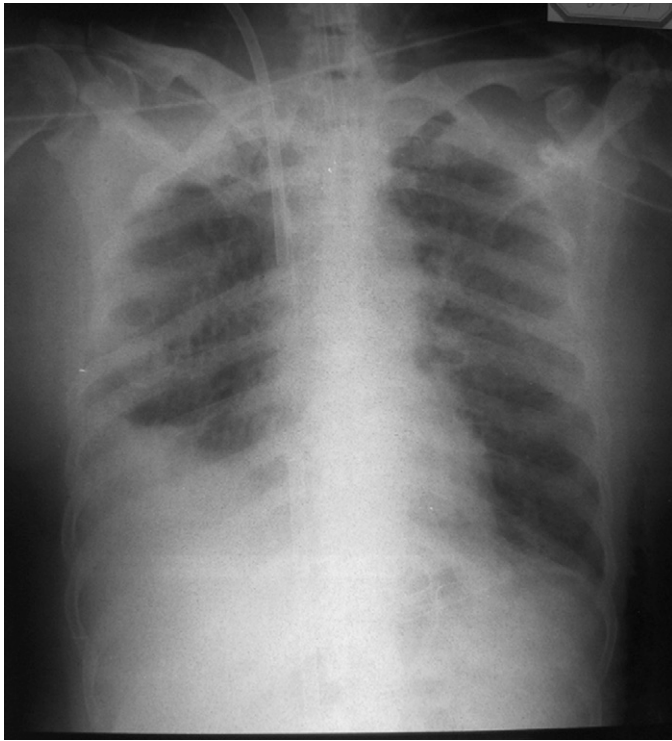
**Figure 1.** Chest radiograph showing bilateral diffuse alveolar opacities (orthotopia).

continued to drop, and peak inflating pressure (PIP) climbed to 44 cmH<sub>2</sub>O. After 16 hours of ventilation, venovenous (VV) ECMO was initiated. Based on clinical presentation and laboratory data that the perinuclear ANCA antibodies and anti-myeloperoxidase antibodies (anti-MPO) were positive, a diagnosis of primary systemic vasculitides was made.

The ECMO system was set up at the bedside of the intensive care unit. A centrifugal pump (550 Bio-Console Extracorporeal Blood Pump Speed Controller; Medtronic, Minneapolis, MN), Medtronic Hollowfiber Oxygenator and Tubing Pack (Custom Tubing Pack with Carmeda Bioactive Surface, CB1V97RI; Medtronic) were used. A 21-Fr cannula (Bio-Medicus Cannula, CB96670-21; Medtronic) was placed in the patient's right femoral vein, and a 17-Fr cannula (Bio-Medicus Cannula, CB96570-17; Medtronic) was placed percutaneously in the patient's right internal jugular vein. The best location of the cannulas, which should be placed at the junction of vena cava and right atrium, was confirmed by transesophageal echocardiography (TEE) to minimize recirculation. Blood drained from the patient's femoral vein and returned through the internal jugular vein. At initiation of ECMO, average flow rate was set at 3.5 L/min, sweep gas flow rate at 2 L/min, and FiO<sub>2</sub> at 1.0. Tidal volumes were decreased, and FiO<sub>2</sub> was lowered to prevent further lung damage caused by barotraumas and oxygen toxicity. The

ventilator was set at a rate of 12 breaths/min, tidal volume of 300 mL, PEEP of 12 mmHg, and FiO<sub>2</sub> of .6. The PIP was not higher than 30 mmHg. The SaO<sub>2</sub> of the venous drainage and arterial return into the internal jugular were maintained at ~65–85% and >95% by adjusting flow rate and FiO<sub>2</sub>, respectively. Because we used a centrifugal pump with a coated circuit including the cannula, we felt it justified avoiding the administration of heparin for the first 3 days to prevent aggravating the diffuse alveolar hemorrhage. A maintenance dose of heparin was started on day 3 at 4–8 units/kg/h until weaned from ECMO, and the activated clotting time (ACT) was maintained between 127 and 172 seconds. On the third day of ECMO, the oxygenator was replaced (QUARDROX-D Diffusion Membrane Oxygenator; MAQUET Cardio-pulmonary, Hirrlingen, Germany) after the discovery of a lamellate thrombus. Because of mild hematuria on day 9 of ECMO, the centrifugal head was replaced. Each day, platelets were injected slowly through the port of the oxygenator, and packed red blood cells were intermittently given by intravenous drip to ensure maintenance of a platelet count over 50 × 10<sup>9</sup>/L and an hematocrit (HCT) >40%. The patient remained stable on hospital day 11 (ECMO day 9), after the flow rate was decreased to 2 L/min, sweep of 3 L/min, and FiO<sub>2</sub> of .5. On hospital day 15 (ECMO day 13), the gas source to the oxygenator was discontinued for the next 8 hours with no major changes made with the ventilator except increasing the tidal volume. The patient maintained a Pco<sub>2</sub> < 50 mmHg, a Po<sub>2</sub> > 80 mmHg, and a SvO<sub>2</sub> > 70 mmHg without ECMO, and the chest radiograph continued to gradually improve (Figure 2). The patient was subsequently decannulated at bedside.

The patient's pathology was aggressively treated with high doses of methylprednisolone (500 mg IV daily for 2 days). The dose was decreased to 80 mg daily from hospital day 3 to day 30 and to 40 mg daily from hospital days 30 to 55. Once the methylprednisolone was discontinued, prednisone (30 mg daily) was taken orally until discharge. To minimize exposure to cyclophosphamide, 200 mg was intravenously administered every other day originally and reduced to 200 mg twice a week. The patient also received immunoglobulin and albumin therapy. To decrease the pulmonary pressure caused by diffuse alveolar hemorrhage (DAH), alprostadil (prostaglandin E1) was perfused continuously at 80 units/min from hospital days 5 to 31 to lower recirculation and keep stable hemodynamics. The patient underwent plasmapheresis three times on hospital days 5, 7, and 16, and continuous renal replacement therapy (CRRT) twice on hospital days 5–8 and 17–20. Chest physiotherapy and bronchial lavage were important for infection prevention and recovery of lung function. Blood, sputum, and urine cultures were tested daily to monitor for infection and guide the use of antibiotics. Table 1



**Figure 2.** Chest radiograph showing normal on the day of weaning ECMO.

summarizes the major events of therapy during the hospital stay. The patient continued to improve gradually, was extubated on hospital day 60, and was discharged home on hospital day 85 with normal pulmonary and renal function.

## DISCUSSION

DAH is a serious complication of ANCA-associated vasculitides. Mortality rate has been shown to exceed 80%

**Table 1.** Major events of therapy initiated during hospital stay.

Event	Time	Duration (hospital day)	Dose
ECMO		3–15	
Ventilation		2–60	
CRRT	2	5–8, 17–20	
PE	3	5, 7, 16	
MePr	Once per day	1–2	500 mg
	Once per day	3–29	80 mg
	Once per day	30–55	40 mg
Prednisone	Once per day	1–2	200 mg
	Once per day	55–discharge	30 mg
CTX	Once every other day	3–29	200 mg
	Twice per week	30–discharge	200 mg
PGE1		5–31	80 U/min

ECMO, extracorporeal membrane oxygenation; CRRT, continuous renal replacement therapy; PE, plasma exchange; MePr, methylprednisolone; CTX, cyclophosphamide; PGE1, prostaglandin E1.

when the  $Pao_2/Fio_2$  ratio falls below 100 mmHg in mechanically ventilated patients (1,2). Although immunosuppressive therapy with glucocorticoids and cyclophosphamide has dramatically improved the survival rate, sufficient time for treatment remains a problem with severe hemoptysis caused by DAH. This suggests that supportive therapies, such as ECMO and CRRT, for complications affecting vital organs are indispensable (3).

ECMO was developed as a supportive therapy for severe respiratory failure and has been able to sustain life in neonates and children with respiratory failure (4). Conflicting findings have been reported regarding the use of ECMO in adults with respiratory failure (5). It is likely that patient selection and ventilator settings are determining factors in the outcome of ECMO use. Because the lung is irreversibly damaged with prolonged mechanical ventilation, the duration of the supportive therapy is important (6). When conventional mechanical ventilation has failed, ECMO can supply oxygenation and, in this case, may have had a direct beneficial effect in improving the outcomes of diffuse alveolar hemorrhage. The use of ECMO may be able to prevent further lung damage caused by high airway pressures and oxygen toxicity while allowing more time for aggressive treatment (3). Although the hemorrhagic disease is generally considered to be a contraindication to ECMO, many other cases of respiratory failure secondary to DHA have been successfully treated this way (7,8).

ECMO was an essential part of this patient's treatment; without it, the patient would most likely have died because of severe hemoptysis and respiratory failure. Lung hemorrhage presents an increased risk of bleeding when paired with the heparinization usually used in ECMO; therefore, dealing with anticoagulation is a critical issue. To avoid excessive bleeding, the patient in this case study was not treated with heparin for the first 72 hours. A lower activated clotting time range (~150 seconds) was subsequently maintained to minimize the risk based on adequate flow rates and utilization of a tip to tip heparin-bonded system. Small clots are not fatal in VV ECMO, because they are captured in the pulmonary vascular bed. Fortunately, in this case study, diffuse alveolar hemorrhage was controlled and confirmed by bronchofibroscopy on ECMO day 3. To lower pulmonary pressure while the patient was on ECMO, alprostadil was administered on day 3. Bronchoalveolar lavage is an important intervention to maintain an unobstructed airway and to prevent lung infection. It is important to note that large doses of steroids and heat loss by the ECMO circuit could mask a fever. Therefore, it is essential to routinely collect cultures of blood, urine, and sputum to be tested for infections.

Although ECMO is a highly invasive procedure, it can be necessary to sustain life in acute respiratory failure if conventional therapy has failed or if there is insufficient time to treat the disease. Successful implementation of

ECMO involves identifying patients who are appropriate for this type of treatment and the careful management of the treatment. Early initiation of ECMO in patients with a potentially reversible pathology and who are appropriate candidates for the treatment would likely increase the success ratio. In this case study, ECMO was indicated for the patient because of severe DAH and lack of time to implement conventional therapy. In conclusion, early initiation of ECMO and meticulous care during treatment should be considered an effective treatment for patients with respiratory failure caused by DAH when conventional therapy fails.

## REFERENCES

1. Langford CA, Talar-Williams C, Barron KS, et al. A staged approach to the treatment of Wegener's granulomatosis: induction of remission with glucocorticoids and daily cyclophosphamide switching to methotrexate for remission maintenance. *Arthritis Rheum.* 1999; 42:2666-73.
2. Vasilyev S, Schaap RN, Mortensen JD. Hospital survival rates of patients with acute respiratory failure in modern respiratory intensive care units. An international, multicenter, prospective survey. *Chest.* 1995;107:1083-8.
3. Ahmed SH, Aziz T, Cochran J, et al. Use of extracorporeal membrane oxygenation in a patient with diffuse alveolar hemorrhage. *Chest.* 2004;126:305-9.
4. UK Collaborative ECMO Trail Group. UK collaborative randomised trial of neonatal extracorporeal membrane oxygenation. *Lancet.* 1996;348:75-82.
5. Peek GJ, Moore HM, Moore N, et al. Extracorporeal membrane oxygenation for adult respiratory failure. *Chest.* 1997;112:759-64.
6. Matsumoto T, Ueki K, Tamura S, et al. Extracorporeal membrane oxygenation for the management of respiratory failure due to ANCA-associated vasculitides. *Scand J Rheumatol.* 2000;29:195-7.
7. Hartmann A, Nordal KP, Svennevig J, et al. Successful use of artificial lung (ECMO) and kidney in the treatment of a 20-year-old female with Wegener's syndrome. *Nephrol Dial Transplant.* 1994;9:316-9.
8. Daimon S, Umeda T, Michishita I, et al. Goodpasture's-like syndrome and effect of extracorporeal membrane oxygenator support. *Intern Med.* 1994;33:569-73.