

The Role of Extracorporeal Life Support in Acute Myocarditis: A Bridge to Recovery?

D. Bradford Sanders, MS, CCP;*‡ Steven R. Sowell, CCP;*‡ Brigham Willis, MD;*‡
John Lane, MD;*‡ Christopher Pierce, MS, CCP;† Stephen Pophal, MD;*‡
Francisco A. Arabia, MD;† John J. Nigro, MD*‡

*Eller Congenital Heart Center, St. Joseph's Hospital and Medical Center, Phoenix, Arizona; †Mayo Clinic, Scottsdale, Arizona; and ‡Phoenix Children's Hospital, Phoenix, Arizona

Abstract: Acute myocardial failure associated with myocarditis is highly lethal. Left ventricular assist device support for these patients has been advocated to decompress the left ventricle and facilitate myocardial remodeling and recovery. Concerns exist regarding the ability of venoarterial (VA) extracorporeal life support (ECLS) to decompress the left ventricle and allow effective myocardial recovery. ECLS has several advantages, including availability, rapid deployment, and flexibility, as compared with contemporary ventricular assist devices. The objective of this study was to provide a brief review of acute myocarditis and present our series of patients. After Institutional Review Board approval, we conducted a retrospective data analysis of patients on ECLS experiencing rapidly progressive myocardial failure from a normal baseline. Patients with a history of intrinsic heart disease were excluded. All patients were thought to have myocarditis and had failed medical therapy requiring emergent ECLS support. Five patients demographics are detailed in Table 1.

Patients experienced life-threatening intractable dysrhythmias or cardiac arrest and were refractory to medical therapy with severe acidosis and impending multisystem organ failure. All patients were stabilized with VA ECLS, and the left ventricle and atrium were decompressed in four of five patients. A left atrial vent was placed in one patient. Myocardial recovery with successful weaning from ECLS was obtained in four of five patients and to a normal ejection fraction in three of the five. One patient failed ECLS weaning and required biventricular VAD support secondary to severe myocardial necrosis from giant cell myocarditis and was transplanted, one died, all others are alive at follow-up. ECLS is safe and effective to treat acute myocardial failure and may be used to obtain myocardial recovery in certain subsets. We devised a decision algorithm for ECLS deployment in this patient cohort and routinely use ECLS. **Keywords:** ECLS, LVAD, acute myocardial failure, myocardial recovery. *JECT. 2012;44:205–209*

Myocarditis is an inflammatory process within the myocardium that produces life-threatening ventricular systolic dysfunction (1,2). Acute fulminant myocardial failure is associated with a rapid, profound decompensation in systolic function and severe heart failure, resulting in circulatory collapse (3). Despite the acute nature and profound sequelae, if myocarditis is quickly diagnosed and aggressively treated, greater than 90% will make a full recovery with minimal long-term complications (4). Patients diagnosed with acute, nonfulminant myocarditis experience a course characterized by a gradual progression to heart failure with subsequent development of chronic

myocarditis. Patients progressively develop chronic, stable, dilated cardiomyopathy (4). Histologically, lymphocytic infiltration and myocardial cytolysis are common to myocarditis and likely account for the associated severe systolic dysfunction and refractory/intractable arrhythmias (1,5,6).

Myocarditis is caused by a myriad of agents including infectious disease, autoimmune syndromes, or exposure to drugs, noxious compounds, or heavy metals (Table 2) (4). The majority of myocarditis cases are likely the result of virus-borne infection, primarily coxsackievirus, parvovirus, and adenovirus; however, a definitive diagnosis often proves difficult (7).

Patients generally present with flu-like symptoms, fever, and malaise days or weeks before an acute event (8). On physical examination, cardiogenic shock symptoms are manifest, including tachycardia, hypotension, and hypoperfusion (9). After an acute exacerbation, the patient can demonstrate profoundly diminished ventricular function, malignant

Received for publication July 17, 2012; accepted October 18, 2012.
Address correspondence to: D. Bradford Sanders, Chief Perfusionist, Cardiothoracic Surgery, Phoenix Children's Hospital, 1919 E. Thomas Road, Phoenix, AZ 85016. E-mail: dsanders3@phoenixchildrens.com
The senior author has stated that authors have reported no material, financial, or other relationship with any healthcare-related business or other entity whose products or services are discussed in this paper.

Table 1. Patient data.

Sex	Age (years)	Weight (kg)	Pre-ECMO pH	Pre-ECMO Lactate	CPR	Maximum Inotropic Support	Pre-ECMO EF	Significant Arrhythmias Present	ECMO Support (hours)	Post-ECMO EF	Outcome	Status	Complications
M	36	75	7.32	8.6	Y	Y	<15%	Y	70	WNL	Recovery	Alive	None
M	1	9.8	7.29	.8	Y	Y	<20%	Y	111	29%	Recovery	Alive	Coagulopathy, transplant as Status II
M	32	84	7.07	14.2	Y	Y	<10%	Y	611	BiVAD	ECLS to BiVAD support to heart treatment	Alive	Complex Treatment Course
M	5	22	7.07	5.3	N	Y	<10%	N	147	WNL	Recovery	Alive	None
F	1	12.2	6.89	16	Y	Y	<10%	Y	123	WNL	Recovery	Death	Suspected pre-ECMO anoxic brain injury

ECLS, extracorporeal life support; CPR, cardiopulmonary resuscitation; EF, ejection fraction; M, male; F, female; Y, yes; N, no; WNL, within normal limits; BiVAD, bilevel ventricular assist device.

arrhythmias, circulatory collapse, indications of multiorgan failure, and can be quite difficult to manage. At this point, successful care is contingent on preserving end-organ function. Institution of early ECLS can support end organ function and reverse an unstable clinical situation.

Relative to other mechanical support means, using ECLS for these patients is a safe and reliable therapy. ECLS support results in an immediate reduction in inotropic support, reduction of mechanical respiratory support, stabilization of end organ function, and reduced need for aggressive antidysrhythmic management or cardioversion. Modern ECLS technology has improved dramatically in the last 10 years. The blood/device interface has become more biopassive, and the technology has enjoyed renewed interest. However, ECLS is not a benign therapy. Significant morbidity can be associated with its use.

Several authors have documented the use of ventricular assist devices (VADs) for support and have suggested

only these devices effectively decompress the left ventricle and hence allow for myocardial remodeling and recovery (5–7,10–13). Concern remains regarding the ability of ECLS to effectively decompress the left ventricle in these patients and provide for myocardial recovery (12,13).

A growing body of literature suggests some patients may experience myocardial recovery such that ECLS can actually represent a definitive therapy (14–17). With this in mind, we review our patient series treating acute decompensatory myocarditis using ECLS and the role of ECLS for myocardial recovery.

METHODS

We conducted a retrospective study from 2006–2010 of all patients at our institution who experienced rapidly

Table 2. Potential causes of myocarditis.

Most Commonly Associated Causes	Less Frequent Causes
Viral infections Adenovirus HIV Coxsackievirus parvovirus B19 Cytomegalovirus	Autoimmune diseases Giant cell myocarditis Churg–Strauss syndrome Inflammatory bowel disease Kawasaki disease Systemic lupus erythematosus Drugs of abuse Cocaine Methamphetamine Ethanol Heavy metals Copper Iron Lead
Anthracycline Doxorubicin Epirubicin Idarubicin Valrubicin	Infections <i>Aspergillus</i> Epstein–Barr virus Hepatitis C virus Influenza A and B virus Mycoplasma pneumoniae Streptococcal species Hypersensitivity reaction Cephalosporins Diuretics Penicillin Phenytoin Sulfonamides Tetracycline

progressive acute myocardial failure from a normal baseline and lacked a history of intrinsic heart disease. All were thought to have myocarditis, had failed medical therapy including intravenous inotropic support, and all demonstrated symptoms of profound clinical compromise with impending multiorgan failure. The patient data are detailed in Table 1.

Patients were cannulated at the bedside in the intensive care unit. Adults were cannulated by the femoral artery and vein as well as a small distal perfusion cannula. Children were cannulated through the carotid artery and jugular vein. Patients were supported with an ECLS circuit consisting of a Rotaflow™ centrifugal pump (MAQUET Cardiovascular, LLC, Wayne, NJ), Quadrox D™ diffusion membrane oxygenator (MAQUET Cardiovascular, LLC), SMARTx™ tubing (Sorin, Arvada, CO), and Biomedicus™ cannulae (Medtronic, Minneapolis, MN). Anticoagulation was accomplished with a standing institutional protocol. Activated clotting time was the primary end point with a normal range of 160–220 seconds for all patients. Fibrinogen, platelet count, and hematocrit were maintained in the following ranges: fibrinogen >300 mg/dL, platelet count >125,000/mL, and hematocrit >30%. These ranges could be altered in the presence and absence of active bleeding. All ECLS support was conducted in the critical care setting and all patients remained intubated. Adult patients were transported on ECLS to a collaborating facility with adult transplant capabilities. Patients were maintained on inotropes with the goal to reduce significant inotropic side effects but to maintain left ventricular ejection. Serial echocardiograms were performed to assess myocardial function and ventricular decompression/distension.

After 72 hours of support, patients were assessed for ability to wean as determined by the ability to maintain cardiac output and pulmonary function at low ECLS flow rates and by echocardiography. Patients that tolerated the weaning trial were subsequently separated from ECLS, decannulated at the bedside, and supported with optimal medical therapy.

RESULTS

All patients were stabilized with ECLS. Four of the five patients were males. There were two young adults and three pediatric patients. Flu-like symptoms preceded decompensation in four of the five patients with a clinical diagnosis of viral-related fulminant myocarditis. Patients were treated with steroids and intravenous immunoglobulin. Myocardial recovery and complete weaning from ECLS was obtained in four of five and to a normal ejection fraction in three of five of patients. Myocardial recovery occurred within 3–5 days of ECLS support initiation.

One pediatric patient was discharged home on optimal medical therapy but experienced chronic heart failure and was subsequently successfully transplanted as a United Network for Organ Sharing Status II 1 year after ECLS support. One adult patient had refractory myocardial failure secondary to giant cell myocarditis with severe myocardial necrosis. This patient was successfully bridged to long-term biVAD support, treated for autoimmune-mediated myocardial necrosis, and ultimately transplanted after an extended course of support. One patient sustained an anoxic brain injury possibly related to prolonged cardiopulmonary resuscitation (CPR) while en route and before ECLS support. This patient experienced complete myocardial recovery; however, this patient did not survive. The left ventricle and atrium were effectively decompressed in four of five patients. A transseptal left atrial vent was placed percutaneously in the cardiac catheterization laboratory to decompress the left atrium in one patient. Average support time for patients weaned from ECLS support was 113 hours.

There were no embolic events in the study population. All patients were successfully bridged to other therapies and three of five obtained full myocardial recovery. One patient died and the remaining four of five are alive in New York Heart Association functional class 1.

DISCUSSION

Acute fulminant myocarditis is associated with a rapid, profound decompensation in systolic function and severe heart failure, resulting in circulatory collapse (3). Affected patients can be in extremis with severe dysrhythmias and acidosis. Survival is contingent on appropriate support that preserves end organ function. ECLS support has been used to successfully support these patients. This technology can be used to reverse an unstable clinical situation, provide time to determine the underlying etiology of heart failure, to ascertain major organ system status, and enlist other supportive therapies. Centers with highly evolved ECLS programs and little VAD experience are confronted with the use of ECLS for acute myocardial failure and recovery. A growing body of literature suggests that modern ECLS systems may be capable of supporting this patient cohort to myocardial recovery (14–17).

Our current ECLS technology and clinical management techniques have demonstrated decompression of the left ventricle in four of five patients, reduction of inotropic and antidysrhythmic therapy, and stabilization of end organ function. This group was very ill, four of five patients receiving periods of CPR, maximal inotropic support, myocardial irritability, and severe runs of dysrhythmias.

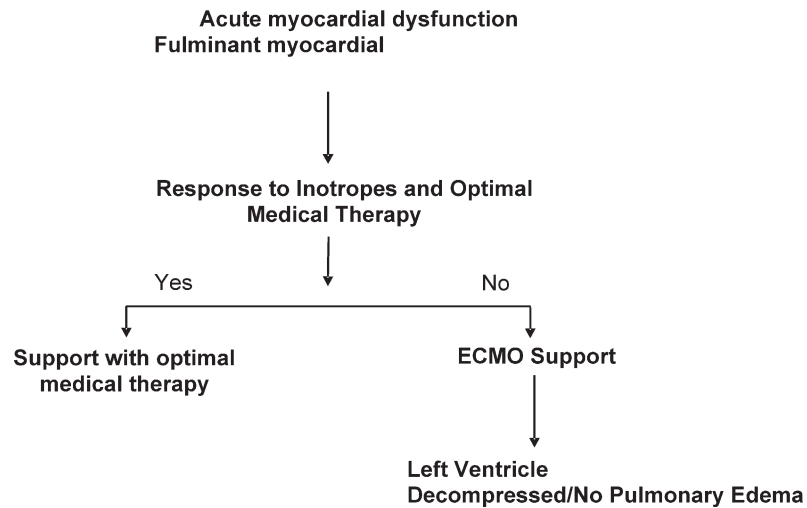
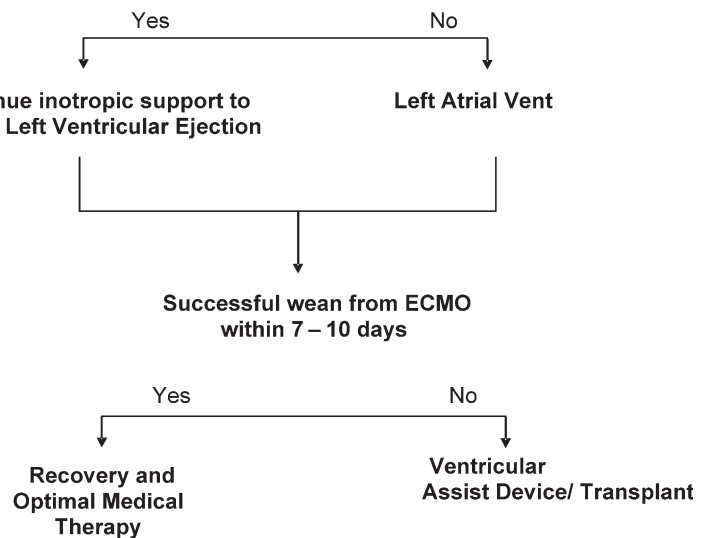


Figure 1. Decision algorithm for mechanical support.



Based on this experience, we have developed and algorithm for support of patients with acute myocardial failure related to myocarditis as delineated in Figure 1. Patients are assessed and supported with optimal medical therapy. Those patients in severe myocardial failure with intractable acidosis or recurrent severe dysrhythmias are placed on ECLS. Inotropes are weaned to reduce vasopressor effects but are maintained at inotropic doses to maintain left ventricular ejection. Echocardiography or chest radiography are the primary examinations to assess the left atrium and ventricle for appropriate decompression. Evidence of left-sided distension is quickly treated using afterload reduction and inotropic manipulation. If unsuccessful, placement of a left atrial vent follows. When the patient demonstrates adequate myocardial recovery, ECLS flows are weaned and, if well tolerated, the patient is optimized and decannulated. In the absence of myocardial recovery after 7–10 days of ECLS support, the patient

is evaluated for long-term support with a VAD and/or cardiac transplantation.

CONCLUSION

ECLS is a safe and effective modality to support patients with fulminant myocardial failure. This small study demonstrated long-term survival of 80% in patients with myocardial failure and initial myocardial recovery in 80% with ECLS support alone.

ECLS is accepted, rapidly and easily deployed, relatively inexpensive, and associated with low embolic potential. Furthermore, ECLS is flexible both in terms of application as well as patient size. These capabilities make ECLS an attractive mode of support for acute myocardial decompensation. During this experience, ECLS has facilitated myocardial recovery, good long-term outcomes, and

this center continues to use ECLS as a “bridge to decision” or first line of therapy.

ACKNOWLEDGMENTS

We recognize the other contributors to this manuscript: The ECMO Team, the people who stand beside the ECLS machine day and night and rarely receive the deserved recognition they should. Many thanks to you all, especially Emily Ramthun and Debbie Leiferman.

REFERENCES

1. Feldman AM, McNamara D. Myocarditis. *N Engl J Med*. 2000;343:1388–98.
2. Magnani JW, Dec GW. Myocarditis: Current trends in diagnosis and treatment. *Circulation*. 2006;113:876–90.
3. McCarthy RE III, Boehmer JP, Hruban RH, et al. Long-term outcome of fulminant myocarditis as compared with acute (nonfulminant) myocarditis. *N Engl J Med*. 2000;342:690–5.
4. Gupta S, Markham DW, Drazner MH, Mammen PPA. Fulminant myocarditis. *Nat Clin Pract Cardiovasc Med*. 2008;5:693–706.
5. Dec GW Jr, Palacios IF, Fallon JT, et al. Active myocarditis in the spectrum of acute dilated cardiomyopathies. Clinical features, histologic correlates, and clinical outcome. *N Engl J Med*. 1985;312:885–90.
6. Vignola PA, Aonuma K, Swaye PS, et al. Lymphocytic myocarditis presenting as unexplained ventricular arrhythmias: Diagnosis with endomyocardial biopsy and response to immunosuppression. *J Am Coll Cardiol*. 1984;4:812–9.
7. Grumbach IM, Heim A, Pring-Akerblom P, et al. Adenoviruses and enteroviruses as pathogens in myocarditis and dilated cardiomyopathy. *Acta Cardiol*. 1999;54:83–8.
8. Felker GM, Boehmer JP, Hruban RH, et al. Echocardiographic findings in fulminant and acute myocarditis. *J Am Coll Cardiol*. 2000;36:227–32.
9. Lee CH, Tsai WC, Hsu CH, Liu PY, Lin LJ, Chen JH. Predictive factors of a fulminant course in acute myocarditis. *Int J Cardiol*. 2006;109:142–5.
10. Arabia FA, Tsau PH, Smith RG, et al. Pediatric bridge to heart transplantation: application of the Berlin Heart, Medos and Thoratec ventricular assist devices. *J Heart Lung Transplant*. 2006;25:16–21.
11. Zimmerman H, Covington D, Smith R, Inaht C, Barber B, Copeland J. Recovery of dilated cardiomyopathies in infants and children using left ventricular assist devices. *ASAIO J*. 2010;56:364–8.
12. Kawashima D, Gojo S, Nishimura T, et al. Left ventricular mechanical support with Impella provides more ventricular unloading in heart failure than extracorporeal membrane oxygenation. *ASAIO J*. 2011;57:169–76.
13. Imamura M, Dossey AM, Prodhan P, et al. Bridge to cardiac transplant in children: Berlin heart versus extracorporeal membrane oxygenation. *Ann Thorac Surg*. 2009;87:1894–901.
14. Pages ON, Aubert S, Combes A, et al. Paracorporeal pulsatile biventricular assist device versus extracorporeal membrane oxygenation–extracorporeal life support in adult fulminant myocarditis. *J Thorac Cardiovasc Surg*. 2009;137:194–7.
15. Asaumi Y, Yasuda S, Morii I, et al. Favourable clinical outcome in patients with cardiogenic shock due to fulminant myocarditis supported by percutaneous extracorporeal membrane oxygenation. *Eur Heart J*. 2005;26:2185–92.
16. Nahum E, Dagan O, Lev A, et al. Favorable outcome of pediatric fulminant myocarditis supported by extracorporeal membranous oxygenation. *Pediatr Cardiol*. 2010;31:1059–63.
17. Sansone F, Campanella A, Rinaldi M. Extracorporeal membrane oxygenation as a ‘bridge to recovery’ in a case of myotomy for myocardial bridge complicated by biventricular dysfunction. *J Artif Organs*. 2010;13:97–100.