

Bloodless Pediatric Cardiopulmonary Bypass for a 3.2-kg Patient Whose Parents are of Jehovah's Witness Faith

Todd M. Ratliff, BS, CCP;* Ashley B. Hodge, MBA, CCP, FPP;*
Thomas J. Preston, BS, CCP, CCT, FPP;* Mark Galantowicz, MD;†
Aymen Naguib, MD;‡ Daniel Gomez, BS, CCP, FPP*

*The Heart Center at Nationwide Children's Hospital, Columbus, Ohio; the †Department of Surgery, The Ohio State University College of Medicine, Columbus, Ohio; and the ‡Department of Anesthesiology and Pain Medicine, Nationwide Children's Hospital, Columbus, Ohio

Abstract: Patients and parents of Jehovah's Witness (JW) faith present multiple challenges to a medical team, especially in the neonatal and pediatric population. The medical team must balance honoring the parents' request of not receiving blood products and fulfilling our commitment as advocates for the child's well-being. A multidisciplinary approach to cardiac surgery must be embraced for bloodless cardiopulmonary bypass (CPB) to be successful. At our institution, we have developed strategies and techniques for blood conservation that are used preoperatively, intraoperatively, and postoperatively for every CPB case with the goal of a bloodless procedure. These protocols include: preopera-

tive erythropoietin, preoperative iron administration, selection of a CPB circuit specific to the patient's height and weight, acute normovolemic hemodilution, retrograde autologous prime and venous autologous prime, tranexamic acid administration, zero-balance ultrafiltration, flushing of the pump suckers post-CPB, modified ultrafiltration, and cell salvage. We present an 8-day-old, 3.2-kg patient of JW faith with aortic valve stenosis and regurgitation and a patent foramen ovale who underwent a bloodless left ventricle-to-aorta tunnel repair and aortic valve repair on CPB. **Keywords:** Jehovah's Witness, bloodless, pediatric cardiopulmonary bypass. *JECT. 2014;46:173–176*

We present an 8-day-old female (52 cm, 3.2 kg, .21 m²) whose parents are of Jehovah's Witness (JW) faith with aortic valve stenosis and regurgitation and a patent foramen ovale. The patient presented for left ventricle-to-aorta tunnel repair as well as aortic valve repair. At our institution we have developed a specific protocol for our JW patient population. In compliance with this protocol, preoperative medications consisted of erythropoietin[®] injections (Amgen Inc., Thousand Oaks, CA) and ferrous sulfate (Mead Johnson, Glenview, IL) supplements. EPO[®] (500 U/kg) was given subcutaneous every other day, for a total of two doses before surgery. Ferrous sulfate (5 mg/kg) was given twice a day for a total of four doses before surgery. The cardiopulmonary bypass (CPB) circuit consisted of a Terumo FX05[®] (Terumo Cardiovascular Systems Corporation, Ann Arbor, MI) oxygenator, 1/8-inch

arterial and 3/16-inch venous line, 3/16-inch arterial boot, and 3/16-inch suckers, Minntech[®] Hemocor[®] HPH MINI hemofilter (Minntech, Minneapolis, MN), Sorin Cobe CSC-14 Custom 1:1 cardioplegia delivery system (Sorin Group USA Inc., Arvada, CO), level sensor (Maquet, Hirrlingen, Germany) placed at the manufacturer's recommended minimum operating level, and a bubble detector (Maquet) placed on the arterial line post oxygenator. Prime volume of the circuit, cardioplegia, and hemofilter was 176 mL. Minimizing the circuit prime volume during complex congenital defects reduces the need for blood transfusion without jeopardizing tissue oxygenation or patient safety (1). Circuit prime consisted of Normosol-R[™] (Hospira, Inc., Lake Forest, IL), 320 mg tranexamic acid (Pfizer Inc., New York, NY), 6 mEq sodium bicarbonate (Hospira, Inc.), 1000 IU sodium heparin (Fresenius Kabi USA, LLC, Schaumburg, IL), 1750 mg mannitol 25% (Hospira, Inc.), and 50 mL albumin 25% (Grifols Therapeutics Inc., Research Triangle Park, NC). During the consent process, all JW patients were asked if albumin may be used. After induction of general anesthesia, an arterial line was placed and preoperative blood analysis was obtained (Table 1). The Hepcon[®] HMS Plus (Medtronic, Inc., Minneapolis, MN) was used for heparin management

Received for publication March 24, 2014; accepted May 30, 2014.
Address correspondence to: Todd M. Ratliff, BS, CCP, Perfusionist, Heart Center, Nationwide Children's Hospital, 700 Children's Drive, Columbus, OH 43205. E-mail: Todd.Ratliff@nationwidechildrens.org
The senior author has stated that the authors have reported no material, financial, or other relationship with any healthcare-related business or other entity whose products or services are discussed in this paper.

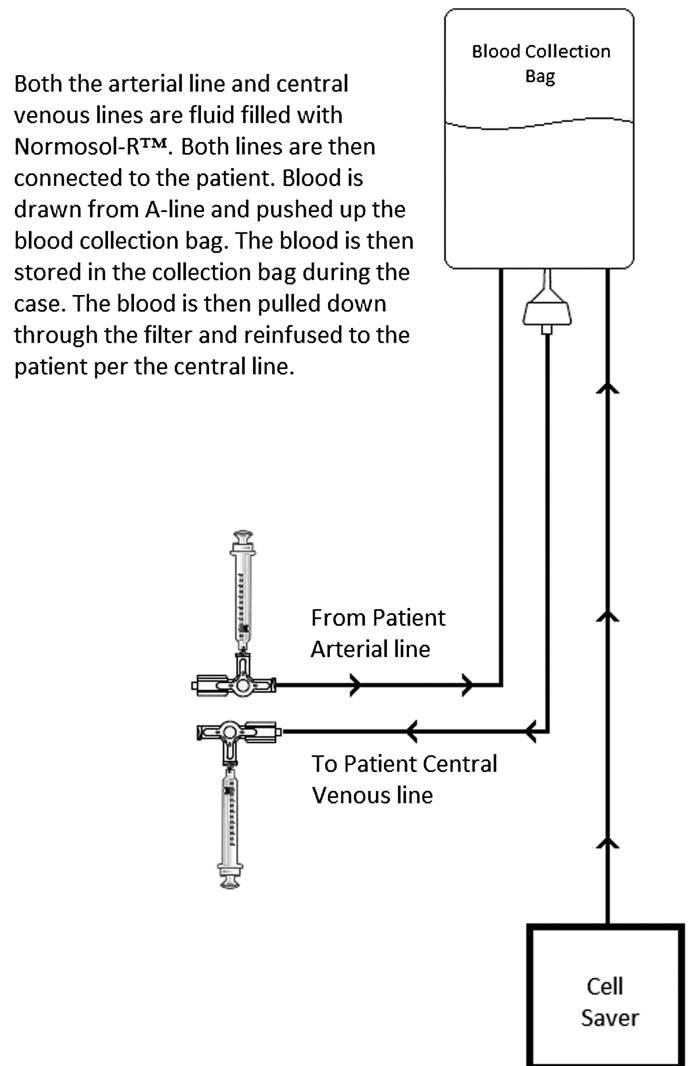
Table 1. Blood analysis results.

	Hematocrit (%)	Hemoglobin (g/dL)	Sodium (mmol/L)	Potassium (mmol/L)	Calcium (mg/dL)	Glucose (mg/dL)	Lactate (mmol/L)	HDR (U/mL)	ACT (seconds)
Baseline 0832	49	16.7	140	4	1.33	92	.8	4.7	139
S/P 0937	41	13.9	140	4.2	1.34	102	.9	3.4	475
First on CPB 1010	26	8.8	137	4.6	1.17	71	.8	***	>999
Second on CPB 1115	18	6.1	138	4.8	1.5	245	1.26	3.4	>999
Off CPB 1125	29	9.9	137	4.3	1.16	220	1.09	.0	153
ICU 1300	34	11.3	140	4.7	1.44	212	.7	N/A	N/A
Discharge POD3	30	10.0	136	3.7	1.26	122	.8	N/A	N/A

***Did not run HDR to decrease blood volume used for analysis.

HDR, heparin dose response; ACT, activated clotting time; CPB, cardiopulmonary bypass; ICU, intensive care unit; S/P, status post; CPB, cardiopulmonary bypass; N/A, not available; POD, postoperative day.

throughout the case. Initial heparin dose response (HDR) was 4.7 U/mL and activated clotting time (ACT) was 139 seconds. The target HDR was 4.7 U/mL and ACT \geq 480 seconds was used throughout the case based on the initial HDR results and heparin protocol. After determining that the dilutional hematocrit on bypass would be $>20\%$, 20 mL/kg of acute normovolemic hemodilution (ANH) was then taken in a continuous loop with the patient (Figure 1) (2). All of the cell saver lines were primed with Normosol-R™. A 60-mL syringe with 8 mL of Anticoagulant Citrate Dextrose Solution USP (ACD; Fenwal, Inc., Lake Zurich, IL) was connected to the arterial line stopcock. Blood was drawn back into the syringe and then pushed up into the blood collection bag. With the central venous line already attached to the patient, the arterial line was disconnected and drained back to the blood collection bag. Per protocol, 20 mL/kg of ANH was taken from the patient for a total of 64 mL of ANH anticoagulated with 8 mL of ACD. During this process, anesthesia maintained hemodynamic stability with the administration of phenylephrine and 25% albumin, based on the cerebral saturation, blood pressure (MAP), and electrocardiographic (EKG) changes (2). The parents of this patient consented for the use of 25% albumin, which was given during the collection of ANH to offset the loss of volume. While collecting ANH cerebral saturations ranged between 64% and 71%, MAP >25 mmHg, and no EKG changes were noted. A median sternotomy was then performed followed by the administration of the heparin loading dose of 1300 IU. An 8-French DLP Medtronic arterial cannula (Medtronic, Inc.) was placed and retrograde autologous prime (RAP) was completed. A single venous 16-French Medtronic cannula (Medtronic, Inc.) was placed and venous autologous prime (VAP) was completed with a

**Figure 1.** ANH autotransfusion set up for Jehovah's Witness patients.

total RAP/VAP volume of 110 mL. Just before the initiation of bypass, tranexamic acid was added to the reservoir. A three-dose regimen of 320 mg tranexamic acid per dose was administered throughout the case (2). The first dose is administered during anesthesia induction, the second by perfusion with the initiation of bypass, and the last is given after the administration of protamine by anesthesia. Bypass was initiated without the use of vacuum-assisted drainage at a flow of 2.2 L/min/m² per protocol and 3 mL were drawn for initial blood analysis (Table 1). The patient was cooled to 32°C, cross-clamp applied, and cardioplegia was administered using the Sorin CSC-14 Custom 1:1 delivery system (Sorin Group USA, Inc., Arvada, CO) directly into both the right and left coronary ostia with a 2-mm arteriotomy cannula (Medtronic, Inc.) for a total of 15 mL/kg (Table 2). Subsequent cardioplegia doses (7.5 mL/kg) were delivered every 30 minutes. Zero-balance ultrafiltration was initiated after the administration of cardioplegia and continued throughout the case (Table 3). Blood analysis was drawn every 60 minutes throughout the case. The aortic cross-clamp was removed; 1750 mg mannitol 25% and 160 mg magnesium sulfate were administered. The patient was warmed to a rectal temperature of 36°C. Once the patient reached normothermia, blood analysis was drawn and out-of-range results were corrected (Table 1). The patient was then weaned from CPB. The lowest CPB hematocrit was 18% with a corresponding lactate of 1.26 mmol/L (Table 1). The lowest SvO₂ was 52% with subsequent CrO₂ at 66% (Figure 2). Total CPB time was 91 minutes and ischemic time was 70 minutes. Modified ultrafiltration (MUF) was started immediately after CPB support was weaned, the venous cannula was removed, and drained back to the reservoir. MUF was stopped after 9 minutes with 130 mL of effluent removed. After the completion of MUF, 15 mg of protamine sulfate (APP Pharmaceuticals, LLC., Schaumburg, IL) was administered by anesthesia.

Table 2. Cardioplegia solution.

Component	Cardioplegia Solution (1:1)
KCl	60 mEq/L
Mannitol	12.5 mg/L
Bicarbonate	35 mEq/L*
5% dextrose and .9% NaCl	Balance to total 500 mL

*Pharmacy will pH balance crystalloid solution, so HCO₃⁻ concentration may vary.

Table 3. Zero-balance ultrafiltration (ZBUF) solution.

Component	ZBUF Solution
Normosol-R™	1 L
Sodium bicarbonate 8.4%	20 mEq/L
Calcium chloride	200 mg/L

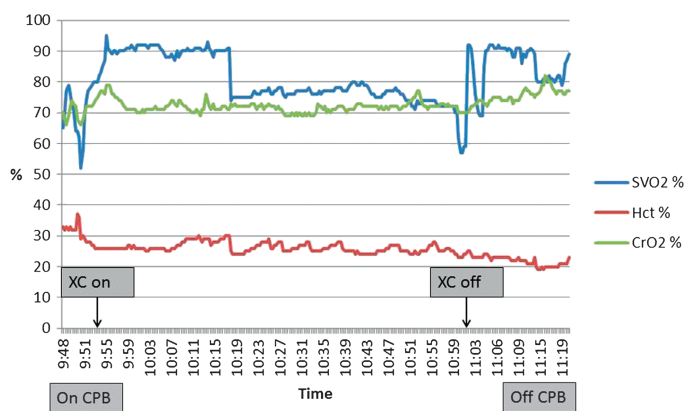


Figure 2. Cerebral saturations, hematocrit, and venous saturations throughout the case.

After the protamine administration, anesthesia attached a 60-mL syringe onto the central venous line stopcock (right internal jugular vein). The ANH was pulled through the blood filter and reinfused back to the patient. Pump suckers were subsequently flushed with Normosol-R™ to ensure complete red blood cell return. Before the removal of the arterial cannula, the remainder of the CPB circuit volume was pumped to the Fresenius Continuous Auto Transfusion System (Terumo Cardiovascular Systems Corporation, Ann Arbor, MI). Normosol-R™ is used for cell saver wash to decrease the amount of acid base, electrolyte, and hematologic changes that occur when normal saline is used (3). The circuit volume was washed and pushed into the collection bag. A total of 34 mL of cell saver product was reinfused. Blood analysis was performed after reinfusion of the cell saver product and ANH (Table 1). Recombinant Factor VIIa (NovoSeven®; Novo Nordisk Inc., Plainsboro, NJ) was administered (90 mg/kg) immediately after ANH to promote hemostasis according to our institutional JW protocol (4). The patient was extubated and placed on a nasal cannula at 1 L/min and transferred to the intensive care unit (ICU). The patient remained hemodynamically stable throughout the first 24 hours postoperatively without neurological complications. The patient was weaned from oxygen and the chest tube was removed before transferring to the cardiac step down unit on postoperative day (POD) 1. The chest tube totaled 67 mL of drainage from time of placement in the operating room to time of removal. The patient continued to do well and was discharged home on POD 3 without allogeneic blood product exposure.

COMMENT

A multidisciplinary approach is paramount for safe and successful team management of JW patients. JWs believe that God views blood as life, so they avoid blood administration in obedience to God, but also out of respect for

Him as the giver of life (5). The medical field must remember this is not only a medical decision, but also a religious one. They also refuse retransfusion of autologous blood that has been separated from their circulatory system. Most JW's feel that the nonblood-primed external tubing of a CPB circuit is to be viewed as an extension of their own circulatory system as long as a continuous, uninterrupted circuit is maintained (6). Bloodless cardiac surgery involving CPB is possible for this patient population in neonates, pediatrics, and adults. Since 2002 our institution has seen a steady increase in cardiothoracic cases for the JW population. As a result of this increase, our institution has put in place a specific consent process for all JW patients. This process consists of two different forms, the first being a general consent for surgery, sedation, and anesthesia. Second is a letter of understanding regarding blood transfusions. Within this consent it states that the hospital acknowledges the patient's or parents' request for no blood products. If during the surgical procedure, the surgeon or the anesthesiologist in attendance believes that an emergency has arisen, they may administer blood products. The staff will act in accordance with the law of the state of Ohio, which permits them to act responsibly, provide emergency surgical or medical care and treatment, which may include transfusion of blood or blood products. Our success in safely caring for the JW population has resulted in more emphasis on trying to achieve bloodless cardiac surgeries in all patient populations. It has been shown in adult and pediatric literature that there are

higher mortality rates, increased ventilator time, and increased ICU length of stay associated with blood product transfusions (7). Our goal is to demonstrate the possibility of safely achieving bloodless cardiac surgery in the JW pediatric and neonatal populations. We recognize that there is a need for blood products, in certain situations, but must determine this need based on the patient's condition, not a preconceived transfusion parameter.

REFERENCES

1. Redlin M, Huebler M, Boettcher W, Kukucka M, Schoenfeld H, Hetzer R, Habazettl H. Minimizing intraoperative hemodilution by use of a very low priming volume cardiopulmonary bypass in neonates with transposition of the great arteries. *J Thorac Cardiovasc Surg.* 2011;142:875–81.
2. Olshove VF, Preston T, Gomez D, Phillips A, Galantowicz M. Perfusion techniques toward bloodless pediatric open heart surgery. *J Extra Corpor Technol.* 2010;42:122–7.
3. Halpern NA, Alicea M, Seabrook B, Spungen AM, McElhinney AJ, Greenstein RJ. Cell saver autologous transfusion: Metabolic consequences of washing blood with normal saline. *J Trauma.* 1996;41:407–15.
4. Winch P, Naguib A, Bradshaw J, Galantowicz M, Tobias J. Decreasing the need for transfusion: Infant cardiac surgery using hemodilution and recombinant factor VIIa. *Pediatr Cardiol.* 2013;34:119–24.
5. Ridley DT. Jehovah's Witnesses' refusal of blood: Obedience to scripture and religious conscience. *J Med Ethics.* 1999;25:469–72.
6. Boettcher W, Merkle F, Huebler M, et al. Transfusion-free cardiopulmonary bypass in Jehovah's Witness patients weighing less than 5 kg. *J Extra Corpor Technol.* 2005;37:282–5.
7. Kneyber MCJ, Hersi MI, Twisk JWR, Markhorst DG, Plotz FB. Red blood cell transfusion in critically ill children is independently associated with increased mortality. *Intensive Care Med.* 2007;33:1414–22.