

Complex Cardiac Surgery on Patients with a Body Weight of Less Than 5 kg without Donor Blood Transfusion

Wolfgang Boettcher, ECCP;* Frank Dehmel, ECCP;* Mathias Redlin, MD;† Oliver Miera, MD;‡ Michele Musci, MD, PhD;* Mi-Young Cho, MD;* Joachim Photiadis, MD, PhD*

*Departments of Congenital Heart Surgery and Pediatric Heart Surgery, †Anesthesiology, and ‡Pediatric Cardiology, Deutsches Herzzentrum Berlin, Berlin, Germany

Abstract: Performing safe cardiac surgery in neonates or infants whose parents are Jehovah's Witnesses is only possible in a coordinated team approach. An unconditional prerequisite is a cardiopulmonary bypass (CPB) circuit with a very low priming volume to minimize hemodilution. In the past decade, we have developed a functional blood-sparing approach at our institution. The extracorporeal circuit was miniaturized. This had to be recently adapted, faced with a challenge associated with the switch to high-volume crystalloid cardioplegia. A filtration circuit was added. Here, we report an open heart surgery on three consecutive children of Jehovah's Witness parents with a body weight of 2.7, 4.5, and 4.8 kg, respectively. Procedures consisted of one arterial switch

operation and two repairs of complete atrioventricular septal defects. Our static priming volume of less than 90 mL resulted in a nadir hematocrit during CPB of 27.7% (Hb 8.9 g/dL) in a patient which happened to have the lowest body weight of 2.7 kg. The two other patients had their lowest hematocrit at 31.4% (Hb 10.2 g/dL). The three children could be treated without any kind of transfusion of blood which had left the circulation or its extensions, in accordance with the parents' wishes, and enjoy favorable outcomes without transfusion of blood products during their entire hospital stay. **Keywords:** cardiopulmonary bypass, blood transfusion, Jehovah's Witnesses, newborn, infant, transfusion free, bloodless. *J Extra Corpor Technol. 2017;49:93–97*

Performing cardiovascular surgery on children, infants, or even neonates with parents who are Jehovah's Witnesses remains a challenge to the whole team: the surgeons, who have to minimize blood loss, the anesthesiologist who must optimize volume management, and the perfusionist who must provide the lowest possible extracorporeal circuit prime volume. Most followers of the Jehovah's Witness faith refuse blood product transfusion when blood has left the cardiovascular system. In most cases, cardiopulmonary bypass (CPB) is accepted as an extension of the cardiovascular system, and the cell saver is also interpreted as an allowed extension. For more than a decade, the Deutsches Herzzentrum Berlin (German Heart Institute Berlin) has been working on a program to avoid or at least to reduce the amount of blood transfusions in congenital heart surgery patients, including neonates and infants. In this journal, over 10 years ago, we first presented a number of cases of patients with a body

weight (BW) of less than 5 kg on whom we performed transfusion-free corrective cardiovascular surgery (1). We have further modified our technique by shortening the extracorporeal circuit lines, reducing the internal diameters (IDs) and incorporating the lowest prime oxygenator available with an integrated arterial line filter, or in combination with the tiniest decentralized filters. Our modifications have decreased the nadir hematocrit seen in our perfusion practice. The results may be judged in terms of the resultant lowest hematocrit values especially during the period with extracorporeal circulation.

Due to a change in policies with a new surgical team, the perfusionist was faced with a challenge associated with the switch to high-volume crystalloid cardioplegia, which is re-infused every 20–40 minutes, in contrast to our previous strategy of using low-dose and mostly single-shot cardioplegia. An additional ultrafiltration circuit was required to handle this volume due to its impact on the hematocrit. This was in contrast to our previous strategy of eliminating any additional extensions of the extracorporeal circuit and all kinds of ultrafiltration. We report the results of our enhanced perfusion strategy in three patients weighing less than 5 kg in whom a transfusion-free approach was used.

Received for publication December 04, 2016; accepted February 27, 2017. Address correspondence to: Wolfgang Boettcher, ECCP, Deutsches Herzzentrum Berlin, Berlin, Augustenburger Platz 1, 13353 Berlin, Germany. E-mail: boettcher@dhzb.de

The senior author has stated that authors have reported no material, financial, or other relationship with any healthcare-related business or other entity whose products or services are discussed in this paper.

CASE REPORTS

Case 1

A newborn female with 2.7 kg BW and body length of 52 cm (body surface area [BSA]: 0.197 m²) with dextrotransposition of the great arteries had undergone a Rashkind maneuver on day of life (DOL) 1. A persistent ductus arteriosus (PDA) was kept open with Alprostadil (Minprog®; Pfizer Corp., New York, NY) treatment until corrective surgery took place on DOL 14. We ligated the PDA, performed an arterial switch operation, and closed the patent foramen ovale. Overall bypass time was 185 minutes.

The extracorporeal circuit used a Terumo CAPIOX FX05 (Terumo Cardiovascular Group, Inc., Ann Arbor, MI) oxygenator with integrated arterial line filter. The venous and boot lines consisted of 3/16 inch in inner diameter (ID) tubing. The arterial line consisted of 1/8-inch-ID tubing. All tubing could be shortened because of the use of mast-mounted roller pumps (Stöckert S5; LivaNova PLC, London, UK). The resultant static priming volume was 85 mL including 43 mL in the oxygenator bundle, 8 mL in the arterial limb, 20 mL in the venous limb, and 9 mL in the boot line. The venous reservoir was nearly empty when CPB was commenced. The dynamic priming volume was improved by using suction lines of 1/8-inch ID.

After direct aorta and bicaval cannulation, the bypass was started at full flow of 2.5–3 L/min/m². The PDA

was ligated immediately with the beginning of the pump run. The patient was cooled to 32°C with an alpha-stat blood gas strategy thereby keeping the PaO₂ at around 150 mmHg. A bubble detector was placed at the oxygenator outlet and a level sensor was placed on the venous at the level of 20 mL. Vacuum-assisted drainage was initiated upon commencement of bypass and stopped immediately before separation from bypass. Myocardial protection included Custodiol cardioplegia (Dr. Franz Köhler Chemie GmbH, Bensheim, Germany) dosed 30 mL/kg BW every 30 minutes via the aortic root (total volume: 220 mL). Ultrafiltration started immediately when infusion of the cardioplegic solution began. The whole amount of the cardioplegic solution returned to the cardiotomy reservoir. Ultrafiltration was done with the ME HFOS 0025 (Medos, Stolberg, Germany) between the arterial pump and the reservoir connected to a 10-cm line with 1/8-inch ID at the inlet and also on the outlet of the filter. After termination of every temporary filtration process, the blood from the ultrafilter was immediately emptied into the cardiotomy reservoir. The resultant hyponatremia and the acidosis caused by the cardioplegic solution were counteracted by timely infusion of sodium bicarbonate 8.4% and sodium chloride 10%. The course of hemoglobin concentration is depicted in Figure 1. The hematocrit prior to CPB was 44.9% (Hb 16.6 g/dL). With the onset of CPB, the resultant Hct due to hemodilution was 32% (Hb 10.4 g/dL). Lowest hematocrit due to cardioplegia was 27.7% (Hb 8.9 g/dL). The patient left

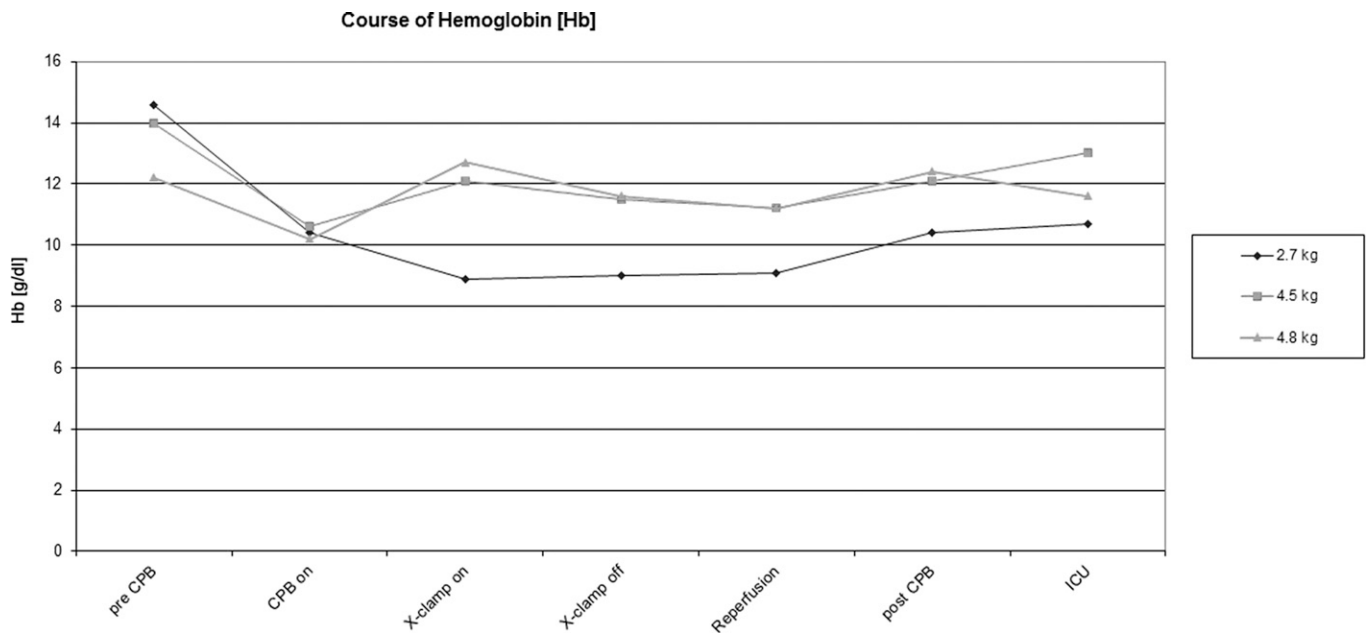


Figure 1. Course of hemoglobin.

the operating room with Hct of 32.0% (Hb 10.3 g/dL). The patient underwent tracheal extubation on POD 2. She left the intensive care unit (ICU) on POD 4.

Case 2

At 5 months old, an infant of 4.5 kg BW and 60 cm body length (BSA: 0.28 m²) with a complete atrioventricular septal defect was operated on with application of the double-patch technique. The extracorporeal circuit of the heart–lung machine had the same design as applied in case 1.

Surgery was performed during mild hypothermia of 32°C. Cardiac standstill was induced with initial 137 mL Custodiol repeated by reinfusing 90 mL twice after every half an hour (total volume: 327 mL). The amount of cardioplegic solution was eliminated by conventional ultrafiltration. The ultrafiltration circuit was only filled with blood when in temporary use. The hematocrit immediately before CPB was 43.1% (Hb 14.0 g/dL) (Figure 1). The priming volume of the CPB led to hemodilution to an Hct of 32.7% (Hb 10.6 g/dL), representing the lowest Hct during CPB. The highest Hct on bypass due to conventional ultrafiltration was 38.4% (Hb 12.5 g/dL). Overall bypass time was 153 minutes.

The child was extubated on POD 4 and left the ICU on POD 7.

Case 3

An 8-month-old girl weighing 4.8 kg with a body length of 58 cm (BSA: 0.29 m²) with a complete atrioventricular septal defect was operated on with the double-patch technique. Mild hypothermia of 34°C was induced. This patient required three venous cannulae, an additional one for the left superior cava. Overall bypass time was 182 minutes; aortic cross-clamping lasted 116 minutes. Initially, Custodiol 145 mL and further doses of 140 and 110 mL were used for myocardial protection and eliminated by ultrafiltration as described above.

This customized extracorporeal circuit consisted of the Dideco D100 oxygenator in combination with the arterial line filter D130 (LivaNova PLC) (Figure 2). The arterial line had 1/8-inch ID and the venous line 3/16-inch ID.

Hematocrit immediately before commencing bypass was 37.7% (Hb 12.2 g/dL) (Figure 1). The first value with bypass begin was the lowest at 31.4% (Hb 10.2 g/dL) and the highest was 39.1% (Hb 12.7 g/dL) on bypass run.

The patient underwent tracheal extubation on POD 2 and left the ICU 2 days later.

In all three patients, the priming solution consisted of only a crystalloid balanced electrolyte solution and heparin (5,000 IU). Heparin was administered before initiating CPB and was neutralized by a dose of protamine calculated with the Hepcon Hemostasis Management System HMS (Medtronic Inc., Minneapolis, MN).

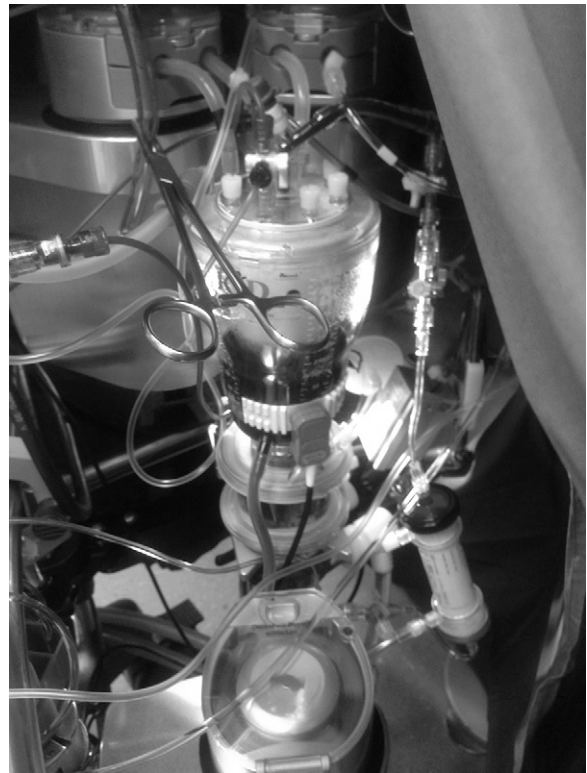


Figure 2. Extracorporeal circuit of case 3: Arterial pump in the front in proximity of the outlet of the venous reservoir and the oxygenator/heat-exchanger inlet. In height of the inlet of the cardiotomy reservoir two suction pumps with 1/8-inch-ID tubing. Venous reservoir inlet with 3/16-inch-ID venous line in the same height as the patient's right atrium. Vent port of the reservoir is connected to the tubing for vacuum-assisted venous drainage.

Modification of CPB Circuit

In contrast to the machine in use 10 years ago, the S5 consoles with their modified mast-mounted pumps allow more unrestricted positioning of the pumps at the location needed. The arterial pump is close to the venous reservoir outlet and the oxygenator inlet. The pumps responsible for cardiotomy suction are at the height of the operation table and in proximity to the inlets of the cardiotomy reservoir. The heart–lung machine itself is moved as close as possible to the operation table in such a way that only one surgical assistant has enough space. Because the venous reservoir inlet is at the height of the patient's right atrium, we are forced to adapt vacuum-assisted drainage in a range between –20 and –40 mmHg (Maquet, Stolberg, Germany).

The static priming volume is minimized by the incorporation of 1/8-inch-ID tubing in the arterial line, which is preassembled with 3/16-inch connectors on both sides by the manufacturer (LivaNova PLC).

The longest tubes in the extracorporeal circuit are those from the cardiotomy suction. To reduce this dynamic

priming volume essentially, those suction lines, including their pump raceways, were replaced by 1/8-inch-ID tubing. If these lines become filled with the patient's blood the volume missing in the reservoir has to be replaced by alternative fluid to prevent limitation of the flow by the low-level detector. We currently have three suction lines in use. We reduced the ID about 5 years ago to 1/8 inch. We since had no problems concerning an inadequate suction capacity in all those years. In our institution, 1/8-inch suction lines are used in patients up to 10 kg BW, but we switch the pump boot of the suckers to 3/16 for those patients with a BW of more than 7 kg.

We might choose as the oxygenator either a system with an integrated arterial filter whose priming volume alone is 43 mL, the Terumo CAPiox FX05 or the conventional solution with a separate arterial line filter with the LivaNova's combination of the D100 and the D130. Both options would have almost the same static priming volume: 43 vs. 31 mL + 16 mL, with the D100 needing somewhat more tubing length for connecting with the arterial pump.

DISCUSSION

While blood-sparing CPB approaches have been reported before by our institution (1), these cases illustrate new aspects. The basic extracorporeal circuit used in the first two cases consists of an oxygenator with an integrated arterial filter system with a priming volume of 43 mL. The pump boot and the venous line together represent 100 cm of 3/16-inch-ID tubing, adding 18-mL static priming volume. The arterial line is only of 1/8-inch ID, adding 8 mL/m. Allowing for some connectors, we calculate less than 90 mL of static priming volume. In the third case, we used a combination of the smallest priming volume oxygenator on the market today with a separated arterial line filter, resulting in approximately the same priming volume of 31 mL + 16 mL = 47 mL. However, with the use of this oxygenator, the tubing length is somewhat longer.

The introduction of a high-volume, repeatedly infused cardioplegic solution represents an additional challenge to the perfusionist. The volume of cardioplegic solution is more than twice the static priming volume of the extracorporeal circuit. An adequate ultrafiltration technique had to be developed. The necessary additional extension of the circuit had to be as small as possible, with short lines and small ID only. That filtration circuit was in use only when necessary; then it was emptied into the reservoir.

The patients presented here are children of parents who are of Jehovah's Witness faith. Their religious beliefs do not allow reinfusion of blood or blood products when

they have left the blood circulation or its extensions (2). Therefore, it was mandatory to leave all delivered cardioplegic solution in the circuit and to add an additional ultrafiltration circuit. The use of the cell saver is not an option, as the blood lost through that device has to be immediately replaced with a bloodless solution, thus leading to further hemodilution. Processed cell-saved blood consists of only red cells, all other constituents of patients' own whole blood would be lost. Besides, the time necessary for processing the suctioned blood would be too long. This would also result in reinfusion of a great volume which would further increase hemodilution, a vicious circle.

An additional problem with this technique is the resultant low sodium concentration and acidosis. This has to be counteracted by appropriate infusion of sodium bicarbonate and some additional sodium chloride 10%. Otherwise, neurological complications might be the consequence (3).

Our patients had undergone preoperative therapy with erythropoietin and iron supplementation, which was continued postoperatively. A hematocrit high enough to result in an adequate concentration of erythrocytes after the hemodilution due to the priming volume is a prerequisite. Ten years ago, we had to struggle with much lower hemoglobin values. Nowadays, with higher hematocrit prior to CPB and much smaller circuits, we no longer have the indication for blood transfusion because of hemodilution.

In the past decade, our efforts to provide a circuit for every patient that would not exceed a static priming volume of 33% of their calculated blood volume have led to a circuit design which allows us to eliminate blood priming in every patient, including pre-term infants. We were able to abandon modified ultrafiltration techniques because of our small residual volumes in the circuit after terminating CPB. The volume of the venous line and the blood from the venous reservoir were necessary to generate a preload for the patient's ejecting heart. Immediately after terminating CPB, antagonization of anticoagulation is mandatory to prevent unnecessary blood loss.

In the recent literature, other groups (4–7) have also reported cardiovascular surgery on Jehovah's Witness patients with this class of BW. Results in respect to hemodilution, however, showed lower values of hematocrit than those we are presenting here (6).

CONCLUSION

Ten years after our initial report of this topic in *JECT*, we conclude that we are now more confident of success when pediatric cardiovascular surgery without blood transfusion is requested by Jehovah's Witness parents. A decade of continuous progress with regard to

miniaturization of our extracorporeal circuit and its adaptation to cope with increased volume of crystalloid cardioplegia has culminated in more than 3 years without any blood priming, with less than half of our newborn patients receiving transfusions during CPB at our institution. This presentation of three patients shows that, with acceptable prerequisites, including at least normal hematocrit, we should in all probability be able to perform corrective cardiovascular surgery without transfusion of blood. However, the incalculability of bleeding disorders, for example due to coagulation defects, especially in long pump runs, or other problems which cannot be foreseen means that bloodless operations cannot be guaranteed.

ACKNOWLEDGMENT

We would like to thank Anne M. Gale, Editor in the Life Sciences, for editorial assistance.

REFERENCES

1. Boettcher W, Merkle F, Huebler M, et al. Transfusion-free cardiopulmonary bypass in Jehovah's Witness patients weighing less than 5 kg. *J Extra Corpor Technol.* 2005;37:282-5.
2. Dixon JL, Smalley MG. Jehovah's Witnesses. The surgical/ethical challenge. *JAMA.* 1981;246:2471-2.
3. Kim JT, Park YH, Chang YE, et al. The effect of cardioplegic solution-induced sodium concentration fluctuation on postoperative seizure in pediatric cardiac patients. *Ann Thorac Surg.* 2011;91:1943-8.
4. Wang H, Brewer MP, Lai WW, Krishnamurthy G, Chai PJ. Bloodless repair of isolated pulmonary artery in a neonate. *World J Pediatr Congenit Heart Surg.* 2016;7:112-5.
5. Ratliff TM, Hodge AB, Preston TJ, Galantowitz M, Naguib A, Gomez D. Bloodless pediatric cardiopulmonary bypass for a 3.2-kg patient whose parents are of Jehovah's Witness faith. *J Extra Corpor Technol.* 2014;46:173-6.
6. Schweiger M, Dave H, Kelly J, Huebler M. Strategic and operational aspects of a transfusion-free neonatal arterial switch operation. *Interact Cardiovasc Thorac Surg.* 2013;16:890-1.
7. Lee JM, Byon HJ, Kim JT, Kim HS, Kim CS. Transfusion-free anesthetic management for open heart surgery in a neonate: A case report. *Korean J Anesthesiol.* 2010;59(Suppl 1):41-5.