

Technique Articles

Left Ventricular Unloading during Peripheral Extracorporeal Membrane Oxygenator Support: A Bridge To Life In Profound Cardiogenic Shock

Paolo Centofanti, MD; Matteo Attisani, MD; Michele La Torre, MD; Davide Ricci, MD; Massimo Boffini, MD; Andrea Baronetto, MD; Erika Simonato, MD; Alberto Clerici, MD; Mauro Rinaldi, MD

Division of Cardiac Surgery, University of Turin, Turin, Italy

Abstract: A limit of peripheral veno-arterial Extracorporeal Membrane Oxygenator (VA-ECMO) is the inadequate unloading of the left ventricle. The increase of end-diastolic pressure reduces the possibility of a recovery and may cause severe pulmonary edema. In this study, we evaluate our results after implantation of VA-ECMO and Transapical Left Ventricular Vent (TLVV) as a bridge to recovery, heart transplantation or long-term left ventricular assist devices (LVAD). From 2011 to 2014, 24 consecutive patients with profound cardiogenic shock were supported by peripheral VA-ECMO as bridge to decision. In all cases, TLVV was implanted after a mean period of 12.2 ± 3.4 hours through a left mini-thoracotomy and connected to the venous inflow line of the VA-ECMO. Thirty-day mortality was 37.5% (9/24). In all patients, hemodynamics improved after TLVV implantation with an increased cardiac output, mixed venous saturation and a significant

reduced heart filling pressures ($p < .05$). Recovery of the cardiac function was observed in 11 patients (11/24; 45.8%). Three patients were transplanted (3/24; 12.5%) and three patients (3/24; 12.5%) underwent LVAD implantation as destination therapy, all these patients were discharged from the hospital in good clinical conditions. In these critical patients, systematic TLVV improved hemodynamic seemed to provide better in hospital survival and chance of recovery, compared to VA-ECMO results in the treatment of cardiogenic shock reported in the literature. TLVV is a viable alternative to standard VA-ECMO to identify the appropriate long-term strategy (heart transplantation or long-term VAD) reducing the risk of treatment failure. A larger and multi-center experience is mandatory to validate these hypothesis. **Keywords:** heart failure, cardiogenic shock, mechanical circulatory support. *J Extra Corpor Technol. 2017;49:201–205*

Veno-arterial extracorporeal membrane oxygenation (VA-ECMO) is the treatment of choice for severe acute cardiogenic shock. VA-ECMO allows blood drainage only from the right side of the heart and the inadequate left ventricle (LV) unloading is a well-recognized limitation of its application (1). The high LV end-diastolic pressure increases the risk of subendocardial ischemia and pulmonary edema, leading to a further impairment of left ventricular function and reducing significantly the possibility of a recovery or other definitive treatment (2,3).

In this study, we sought to evaluate our results after mini-invasive implantation of a Transapical Left Ventricular Vent (TLVV) to unload the LV.

During VA-ECMO, testing the function of the right ventricle and/or lung is a difficult challenge and can affect the outcome of subsequent therapeutic strategies (4). The proposed configuration allows to convert “step by step” the ECMO into a short-term left ventricular assist devices (LVADs) if right ventricle and lung functions are preserved. At our center, since 2011, this strategy is routinely used in the treatment of cardiogenic shock after peripheral VA-ECMO implantation.

Received for publication October 12, 2016; accepted March 22, 2017.
Address correspondence to: Matteo Attisani, MD, San Giovanni Battista Hospital–Cardiac Surgery Division University of Turin, Corso Bramante 88, 10126 Turin, Italy. E-mail: matteoatti@libero.it

The senior author has stated that the authors have reported no material, financial, or other relationship with any healthcare-related business or other entity whose products or services are discussed in this paper.

MATERIALS AND METHODS

From 2011 to 2014, 24 consecutive patients suffering from acute cardiogenic shock were supported by peripheral

VA-ECMO at our institution. All patients were treated initially with inotropes and intra aortic balloon pump (IABP) during ECMO to promote the opening of the aortic valve and to unload the LV. TLVV implantation was provided to relieve LV distention, pulmonary congestion, and to avoid LV thrombosis. A satisfactory left ventricular unloading was checked routinely by Wedge pressure evaluation at the Swan–Ganz catheter (less than 14 mmHg). Baseline characteristics of patients and causes of the low cardiac output are summarized in Table 1.

ECMO implantation-surgical technique

Cannulation for ECMO was undertaken through the femoral artery and femoral vein with a percutaneous approach. ECMO circuit was composed by Rotaflow centrifugal pump (Maquet[®], Rastatt, Germany) or Levitronix-Centrimag pump (Levitronix[®] LLC, Waltham, MA). In all cases, a poly-methyl pentene oxygenator (Quadrox D PLS, Maquet[®]) was used.

TLVV implantation-surgical technique

TLVV implantation was performed in intensive care unit after a mean period of 12.2 ± 3.4 hours from the beginning of VA-ECMO support. Following the protocol for trans-apical transcatheter aortic valve implantation, trans-thoracic echocardiogram was performed to precisely locate the LV apex on the chest surface and a mini-thoracotomy of nearly 4 cm was performed into the 5th or 4th intercostal space. After the pericardium was opened, two 2/0 prolene purse-string sutures reinforced with pledgets were placed on the LV apex (Figure 1). Cannulation was performed using Seldinger technique with an arterial high-flow 21–23 Fr cannula (EOPA[®] Arterial cannula, Medtronic[®], Minneapolis, MN). The TLVV size was chosen to achieve the best ventricle drainage. In our experience, optimal left ventricular unloading required maximizing ventricular drainage, so we decided to use this kind of high flow cannulas. The cannula was inserted over the wire for 5–8 cm, according to LV dimension and wall thickness and oriented toward the mitral valve plane with transesophageal echo



Figure 1. Left ventricular apex with purse-string sutures reinforced with pledgets from a left mini-thoracoscopic incision at 4th intercostal space.

guidance. After air purging, the cannula was connected to the venous inflow line of the ECMO support. Pericardium was left opened and after positioning of a single pleural chest tube, thoracotomy was then closed. At this stage, inotropes were withdrawn, IABP continued and diuretic infusion started to allow recovery of heart and lung function. A stable hemodynamic condition has always been achieved thanks to the excellent drainage of both ventricles. Low dose of noradrenaline was administered as required according to the vasoplegic status of the patient.

From VA-ECMO to short-term LVAD-surgical technique

The conversion was carried out following these three consecutive steps. Initial VA ECMO plus TLVV configuration is illustrated in Figure 2, step 1. We proceeded to gradual reduction of the drainage from the venous cannula. The ability of the right ventricle to function without mechanical support was monitored under echocardiographic guidance and evaluating hemodynamic parameters such as the central venous pressure (CVP) and wedge pressure or alternatively the ability of ECMO to maintain an adequate flow. Femoral vein cannula was removed and ECMO circuit was simplified to an apical–arterial (AA) ECMO between the femoral artery and the left ventricular apex

Table 1. Patient baseline characteristics.

Variable	Value
Male gender (%)	13 (54.2)
Mean age (years)	46.0 ± 14.41 (14–72)
BSA (m ²)	$1.8 \pm .2$ (1.5–2.2.2)
Etiology (%)	
Acute heart failure in chronic cardiomyopathy	4 (16.7)
AMI (left descending artery occlusion)	10 (41.7)
Post-cardiotomy heart failure	4 (16.7)
Myocarditis	6 (25.0)

SD, standard deviation; BSA, body surface area; AMI, acute myocardial infarction. Values are presented as mean \pm SD or as number and percentage.

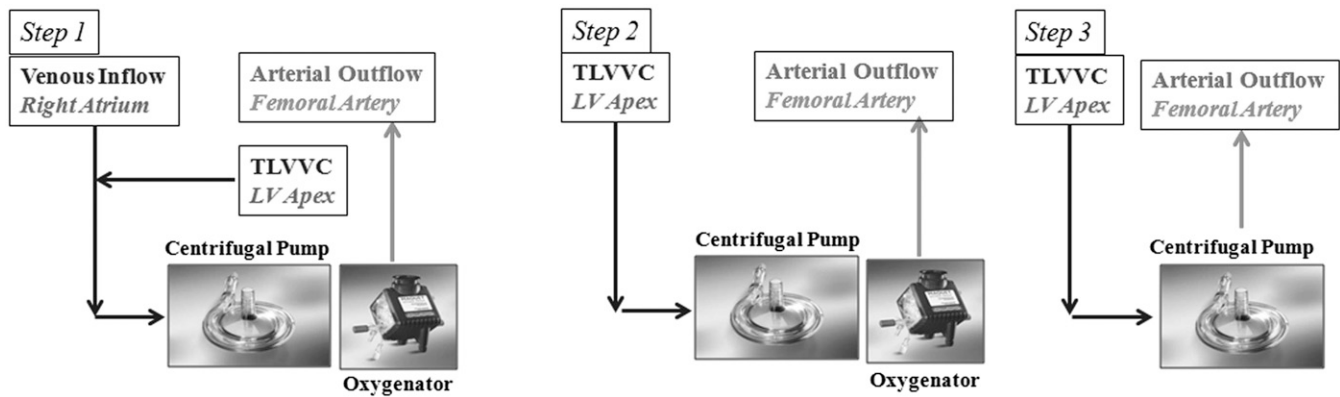


Figure 2. From VA-ECMO to short-term LVAD-surgical technique: a three consecutive steps approach.

(Figure 2, step 2) if the hemodynamic and echocardiographic parameters were satisfactory. During AA-ECMO support, gas exchange was evaluated by gradually decreasing the fractional inspired oxygen (FiO_2) of the ECMO. After removing the oxygenator, AA-ECMO was converted into a short-term LVAD as a bridge to decision (Figure 2, step 3), significantly reducing the anticoagulation therapy, passing from ACT of 200 seconds, required during ECMO, to 160 seconds for LVAD.

Data Collection and Statistical Analysis

Medical records were reviewed for clinical variables including preoperative status, intraoperative data, and postoperative complications. Results are expressed as mean (\pm SD). Paired *t* test were used as appropriate. A *p*-value less than .05 was considered significant. IBM SPSS Statistics for Windows, 22.0 (IBM Corp., Armonk, NY) was used. Ethics Committee had approved rescue therapy.

RESULTS

In these series, all patients underwent left ventricular unloading with an apical cannula. Thirty-day mortality was 37.5% (9/24 patients). Four patients (16.7%) died during mechanical circulatory support: two patients with post-cardiotomy cardiogenic shock died for sepsis, whereas two patients died for multiorgan failure. The duration of ECMO or LVAD support ranged from 5 to 29 days (mean 11.5 ± 6.7). All patients showed an immediate hemodynamic improvement after TLVV implantation. (Table 2). A recovery of the heart function was observed in 11 patients (11/24; 45.8%) after a mean period of 4.6 ± 1.1 days. Two patients required surgical revision for bleeding after apical cannula positioning. In both cases, the source of bleeding was not identified at the apex of the LV, but was at the level of the chest wall. One patient had a stroke after 11 days of short-term LVAD support. In two patients, echocardiographic examination revealed a thrombus in the ascending aorta, dissolved with

anticoagulant therapy without further complications. In 10 cases (10/24; 41.7%), the weaning of the right ventricle from the circulatory support was possible after a mean time of 3.8 ± 1.6 days and the VA-ECMO was converted into the AA-ECMO. In these patients, the pulmonary function significantly improved after TLVV implantation and it was possible to simplify the AA-ECMO to short-term LVAD. The oxygenator was settled at 21% of FiO_2 and removed when P/F (O_2 pressure/ FiO_2) was more than 200, in presence of a stable hemodynamic. Short-term LVAD allowed the successful bridge to long-term treatment in three patients. Three patients underwent heart transplantation on emergency setting. All patients who underwent long-term LVAD implantation or heart transplantation survived and they were discharged from the hospital. (Figure 3)

DISCUSSION

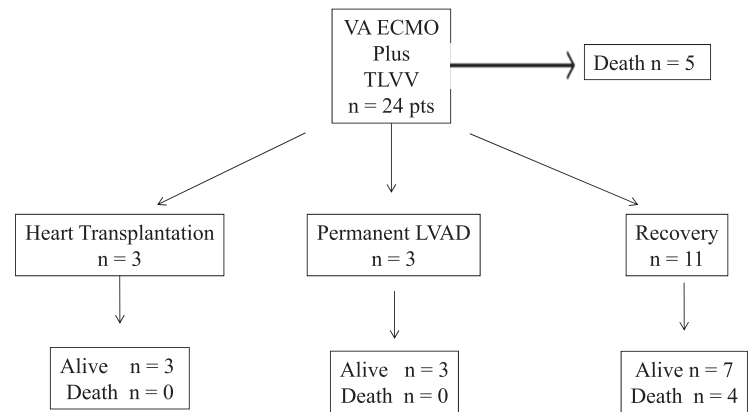
ECMO provides circulatory support with the ability to solve organ injury in case of cardiogenic shock (1,3). VA-ECMO provides adequate support of cardiac output and oxygenation. It is used as temporary support, usually

Table 2. Hemodynamic improvement after TLVV implantation.

	VA ECMO Support		
	Before TLVV implant	24–48 Hours after TLVV Implant	<i>p</i> Value
	Mean Value \pm SD	Mean Value \pm SD	
VA ECMO output expressed as CI	$2.1 \pm .6$ L/min/m ²	$2.9 \pm .5$ L/min/m ²	.03
CVP	8 ± 2 mmHg	5 ± 1 mmHg	.02
MAP	54 ± 12 mmHg	64 ± 4 mmHg	.15
SvO ₂	48 ± 16	63 ± 14	.02

VA-ECMO, veno-arterial extra-corporeal membrane oxygenator; TLVV, transapical left ventricular vent; CI, cardiac index; CVP, central venous pressure; MAP, mean arterial pressure; SvO₂, mixed oxygen venous saturation; SD, standard deviation. *p* is considered not statistically significant if $> .05$.

Figure 3. The overall series of patients undergoing left ventricular unloading with an apical cannula.



VA ECMO veno-arterial Extra Corporeal Membrane Oxygenator
TLVV Transapical Left Ventricular Vent
LVAD Left Ventricular Assist Device

awaiting recovery of organs, or it can be used as a bridge to a permanent device or cardiac transplantation.

Peripheral VA-ECMO offers several advantages: percutaneous insertion of the cannulas into the femoral vessels is simple and it can be performed even during cardio pulmonary resuscitation; it provides both cardiac and pulmonary support for hypoxic patients; it avoids a sternotomy; it provides time to assess potential long-term LVAD and transplant candidates; and it costs less than other forms of mechanical circulatory support (4-7).

Despite mechanical circulatory support has evolved markedly over recent years, the use of ECMO in cardiogenic shock still has 60% of hospital mortality. Although ECMO improves the right ventricle unloading, it does not provide an adequate unloading the LV if we consider all sources of left atrial inflow (bronchial arterial flow, aortic regurgitant flow, undrained right ventricular flow) (1). If LV contractility is poor, left atrial pressure rises considerably before aortic ejection can occur. This could cause pulmonary edema deteriorating lung function. The use of low dose of catecholamine is possible, but leads to an increase in oxygen consumption of the ventricle (8,9).

Different surgical techniques of LV unloading have been suggested. In the setting of a closed chest, decompression of the left heart can present a challenge (2). The use of a percutaneous micro-rotary blood pump through the femoral vessels or the insertion of a venous cannula through the internal jugular vein up to the pulmonary artery have been proposed to overcome the need of central cannulation but these solutions may be unreliable and laborious (9-11). A catheter-based transseptal approach to create a left-to-right shunt to decompress the left atrium have been also proposed especially in the pediatric population (12).

In our experience, a minimally invasive approach with a left minithoracotomy and TLVV implantation is safe and

effective to prevent the complications of LV overload. In our series, almost half of the patients experienced a recovery and most of these survived and were discharged from the hospital. A potential mechanism of action for this improvement in outcome, may be attributed to the reduction of wall tension, which reduce myocardial oxygen demand and increase in coronary blood flow.

In case of respiratory failure, aortic valve closure prevents the heart to pump poorly oxygenated blood into the ascending aorta and thus, to the coronary arteries and to the proximal arch vessels avoiding "harlequin syndrome" (1). Sometimes IABP could be left in place to allow wash out of the aortic valve.

LV unloading prevents also the intraventricular clot formation. On the other side, the stable closure of the aortic valve due to retrograde aortic flow provided from the femoral artery, could increase the risk of clot formation in the ascending aorta and the aortic root. In our report, it occurred in two cases but in both of them, the clots were dissolved by increasing the anticoagulant therapy.

Echocardiographic follow-up is mandatory in these patients. Anticoagulation target therapy was an activate clotting time (ACT) more than 180 seconds. In two cases of aortic root thrombosis, ACT was maintained more than 220 seconds for at least 4 days.

Because prolonged VA-ECMO support frequently leads to complications (13,14), (major bleeding oxygenator thrombosis and lung function impairment) in patients who do not show a recovery, it is advisable to convert it into short-term LVAD as bridge to heart transplantation or destination therapy.

The right ventricular function is the major determinant of LVAD early outcomes (4,15), no definite criteria exist to predict RV dysfunction before LVAD implantation in patient on VA-ECMO. In the setting of VA-ECMO, TLVV could be useful to unmask the presence of a right ventricular

and pulmonary dysfunction which could dramatically affect the outcomes after permanent LVAD implantation or heart transplantation. In patients with normal right ventricular and pulmonary function, TLVV gave the possibility to convert VA-ECMO support to short-term LVAD as a bridge to solution. In this experience, all patients bridged to permanent LVAD implantation or transplantation survived and they were discharged from the hospital.

The main limitation of our study is its retrospective and observational nature and the subsequent treatment bias that is inherent in such studies. A greater number of patients is necessary to confirm the efficacy of our procedure.

CONCLUSIONS

This experience demonstrates that systematic TLVV implantation gives a good chance of recovery of the native heart function in the treatment of advanced heart failure with temporary mechanical circulatory support. TLVV seems to be a viable alternative to standard peripheral VA-ECMO configuration to identify best candidates for long-term LVAD and heart transplantation. This ECMO configuration could decrease the risk of unsuccess, improving outcomes, and optimizing the access to these limited resources. A larger and multicenter experience is mandatory to confirm these hypothesis.

ACKNOWLEDGMENT

Thanks to the technical help of Gennaro Izzo (Chief Perfusionist, Cardiothoracic Department, University of Turin).

REFERENCES

1. Marasco SF, Lukas G, McDonald M, McMillan J, Ihle B. Review of ECMO (extra corporeal membrane oxygenation) support in critically ill adult patients. *Heart Lung Circ.* 2008;17:S41-7.
2. Soleimani B, Pae WE. Management of left ventricular distension during peripheral extracorporeal membrane oxygenation for cardiogenic shock. *Perfusion.* 2012;27:326-31.
3. Lauten A, Engström AE, Jung C, et al. Percutaneous left ventricular support with the Impella 2.5 assist device in acute cardiogenic shock: Results of the Impella-EUROSHOCKRegistry. *Circ Heart Fail.* 2012; 27:23.
4. Matthews JC, Koelling TM, Pagani FD, Aaronson KD. The right ventricular failure risk score: A preoperative tool for assessing the risk of right ventricular failure in left ventricular assist device candidates. *J Am Coll Cardiol.* 2008;51:2163-72.
5. Bowen FW, Koelling TM, Pagani FD, et al. Application of "double bridge mechanical" resuscitation for profound cardiogenic shock leading to cardiac transplantation. *Ann Thorac Surg.* 2001;72: 86-90.
6. Pagani FD, Lynch W, Swaniker F, et al. Extracorporeal life support to left ventricular assist device bridge to heart transplant. *Circulation.* 1999;100(Suppl 2):II206-10.
7. Wang SS, Ko WJ, Chen YS, Hsu RB, Chou NK, Chu SH. Mechanical bridge with extracorporeal membrane oxygenation and ventricular assist device to heart transplantation. *Artif Organs.* 2001;25:599-602.
8. Fuhrman BP, Hernan LJ, Rotta AT, Heard CM, Rosenkranz ER. Pathophysiology of cardiac extracorporeal membrane oxygenation. *Artif Organs.* 1999;23:966-9.
9. Chen Y-S, Ko WJ, Lin FY, et al. Preliminary result of an algorithm to select proper ventricular assist devices for high-risk patients with extracorporeal membrane oxygenation support. *J Heart Lung Transplant.* 2001;20:850-7.
10. Vlasselaers D, Desmet M, Desmet L, Meyns B, Dens J. Ventricular unloading with a miniature axial flow pump in combination with extracorporeal membrane oxygenation. *Intensive Care Med.* 2006;32: 329-33.
11. Avalli L, Maggioni E, Sangalli F, Favini G, Formica F, Fumagalli R. Percutaneous left-heart decompression during extracorporeal membrane oxygenation: An alternative to surgical and transeptal venting in adult patients. *ASAIO J.* 2011;57:38-40.
12. Aiyagari RM, Rocchini AP, Remenapp RT, Graziano JN. Decompression of the left atrium during extracorporeal membrane oxygenation using a transeptal cannula incorporated into the circuit. *Crit Care Med.* 2006;34:2603-6.
13. Muehrcke DD, McCarthy PM, Stewart RW, et al. Complications of extracorporeal life support systems using heparin-bound surfaces: The risk of intracardiac clot formation. *J Thorac Cardiovasc Surg.* 1995; 110:843-51.
14. Acker MA. Mechanical circulatory support for patients with acute-fulminant myocarditis. *Ann Thorac Surg.* 2001;71:S73-6.
15. Dang NC, Topkara VK, Mercado M, et al. Right heart failure after left ventricular assist device implantation in patients with chronic congestive heart failure. *J Heart Lung Transplant.* 2006;25:1-6.