

ECMO Support in Pre-B-Cell ALL for Disseminated Legionnaire's Disease

Hannah K. Bauer, MD;* Matthew P. Malone, MD†

*Louisiana State University Health Sciences Center, Children's Hospital New Orleans, New Orleans, Louisiana; and †The University of Arkansas for Medical Sciences, Arkansas Children's Hospital, Little Rock, Arkansas

Abstract: *Legionella pneumophila* is a common cause of community- and hospital-acquired pneumonia. Its increasing frequency and reemergence as a pathogen of interest in the intensive care unit is likely due to increased awareness, recognition, and diagnostic test availability (1). Extracorporeal Membrane Oxygenation (ECMO) is increasingly used in the pediatric intensive care unit (PICU) for refractory cardiopulmonary failure and acute respiratory distress syndrome (ARDS) in concert with conventional modalities or when these have failed to adequately support the patient. The breadth of applications for this technology are ever-expanding as our collective knowledge and experience grows.

With a particularly high mortality rate among immunocompromised patients, Legionnaires' disease should be considered early in the differential diagnosis and appropriate antimicrobials initiated (1). We present the case of an adolescent patient with pre-B-cell acute lymphoblastic leukemia (pre-B ALL) requiring ECMO support for septic shock and ARDS due to disseminated *Legionella*. To our knowledge, this is the first case describing an immunocompromised pediatric patient supported with ECMO for Legionnaires' disease. **Keywords:** extracorporeal membrane oxygenation, ECMO, pediatrics, critical care, Legionella, immunocompromised. *J Extra Corpor Technol. 2021;53:204–7*

In a retrospective review of 19 adult patients treated with venovenous (V-V) Extracorporeal Membrane Oxygenation (ECMO) for *Legionella* pneumonia, 84% of patients were successfully treated and weaned off of ECMO support with survival to discharge (2). A retrospective review of 15 patients supported on ECMO who all had underlying hematologic malignancy compared with 33 immunocompetent patients demonstrated lower overall survival (0 vs. 24, $p = .044$), with mortality associated with higher ECMO fraction of inspired oxygen (FiO_2), development of infection after ECMO, and the presence of hyperbilirubinemia (3). A query of the Extracorporeal Life Support Organization (ELSO) registry demonstrated survival to hospital discharge in pediatric patients with an immune

compromised condition (ICC) as half of those without an ICC (31% vs. 58%; $p < .001$) (4). ELSO registry data further show that 21% of pediatric patients who had received hematopoietic stem cell transplantation (HSCT) and who subsequently required ECMO support survived the ECMO course, with only one patient surviving to hospital discharge (5).

DESCRIPTION

A 13-year-old female with pre-B-cell acute lymphoblastic leukemia (pre-B ALL) undergoing delayed intensification oncologic therapy with steroids presented to the emergency department at our quaternary care children's hospital with lethargy and confusion. She was admitted to the hematology-oncology ward but required escalation to the pediatric intensive care unit (PICU) following a medical emergency team activation due to altered mental status and hypotension. She was empirically started on broad-spectrum antimicrobials for pneumonia.

Upon arrival to the PICU, she required stress-dosed hydrocortisone due to fluid-refractory septic shock

Received for publication March 12, 2021; accepted May 31, 2021.

Address correspondence to: Hannah K. Bauer, MD, Assistant Professor, Department of Pediatrics, Louisiana State University Health Sciences Center, Children's Hospital New Orleans, 200 Henry Clay Avenue, New Orleans, LA 70118. E-mail: hbauer@lsuhsc.edu

The senior author has stated that the authors have reported no material, financial, or other relationship with any healthcare-related business or other entity whose products or services are discussed in this paper.

due to her history of chronic steroid use, as well as a norepinephrine infusion. This required escalation and transition to epinephrine, calcium chloride, and milrinone infusions. Due to progressive hypoxemic respiratory failure with acute respiratory distress syndrome (ARDS) and altered mentation, she required intubation with increasing mechanical ventilatory support of high positive end-expiratory pressure (PEEP) in addition to inhaled nitric oxide and prone positioning. After a trial of high-frequency oscillatory ventilation (HFOV), she continued to have progressive lactic acidosis and hypoxemia despite high mean airway pressure (MAP), with maximum MAP of 30 cmH₂O and FiO₂ of 1. Anti-microbial therapy was further broadened. Serial echocardiograms demonstrated worsening left ventricular systolic function, with left-ventricular ejection fraction nadir of 29% by M-mode measurement, and moderately diminished right ventricular function. Six days later, she was electively cannulated to venoarterial (V-A) ECMO using a 20-French cannula in the right carotid artery via an 8 mm Gore-Tex[®] graft anastomosed in an end-to-side fashion to the artery, and a 24-French venous drainage cannula in her right internal jugular vein while still being ventilated on HFOV and inhaled nitric oxide. Initial ECMO flow of 2.55 L per minute (LPM), cardiac index 1.7–1.8, sweep gas flow rate of 2 LPM, and membrane FiO₂ 1. Following initial stabilization on V-A ECMO, she was transitioned from the HFOV to conventional mechanical ventilation with “lung-rest settings” of PEEP of 10 cmH₂O and pressure control above PEEP 10 cmH₂O, respiratory rate of 8 breaths per minute (bpm), and 0.4 FiO₂.

At our institution, we maintain and assemble our own ECMO circuit setup. We use the Maquet Rotaflow[®] RF-32 (Getinge, Sweden) and Sorin Revolution[®] (LivaNova, USA) centrifugal blood pumps, with either the adult or pediatric Maquet Quadrox iD[®] (Getinge, Sweden) or Sorin EOS (LivaNova, USA) oxygenators. Our tubing circuitry includes a stopcock bridge between the arterial and venous limbs, a sterile loop, a medication shunt with manifold, and shunting post-oxygenator to the venous limb. For continuous monitoring of patients' extracorporeal flow, mixed-venous oxygen saturation, hematocrit, and post-membrane oxygen saturation, we use the Spectrum M3 (Spectrum, USA) monitor with the Stockert SIII or Sorin SV (LivaNova, USA) base to provide continuous pressure monitoring and battery backup. Both bases are used in conjunction with the Stockert Centrifugal Pump Console and Electronic Remote Clamp to provide post-oxygenator air protection. For thermoregulation, we use the CardioQuip[™] (CardioQuip, USA) MCH-1000(m) Modular Cooler-Heater[®].

Due to progressive hypoxemia and hemodynamic instability despite V-A ECMO support, her mechanical

ventilator settings were increased to PEEP of 20 cmH₂O, pressure control above PEEP of 20 cmH₂O, rate of 15 bpm, and FiO₂ of 1. Her ECMO flow rate was further escalated to 3.5 LPM. She required blood product resuscitation for hemodynamic instability and coagulopathy with hemorrhage, as well as renal replacement therapy in tandem with the ECMO circuit of continuous venovenous hemodialysis due to anuric renal failure and massive fluid overload.

Her ECMO course was complicated by streaming of hyper-oxygenated arterial ECMO blood to the head, neck, and right arm with significant hyperemia in these regions, but systemic hypoxemia. Notably during this time, her cerebral near-infrared spectroscopy (NIRS) monitor was exceedingly high, in the mid-90s, with low systemic mixed-venous oxygen saturation and low renal NIRS. She continued to be pancytopenic despite frequent blood product transfusions and granulocyte-colony stimulating factor administration. Two days after cannulation, she suffered acute neurologic changes, including loss of pupillary and corneal reflexes. An emergent head computerized tomography was performed which showed a large right intraparenchymal hemorrhage with sulcal effacement and midline shift (see Figure 1). She was decannulated from ECMO and placed back on the HFOV, from which life-sustaining measures were subsequently withdrawn per her family's wishes.

Interestingly, her tracheal aspirate culture obtained by in-line endotracheal tube lavage and suction two days

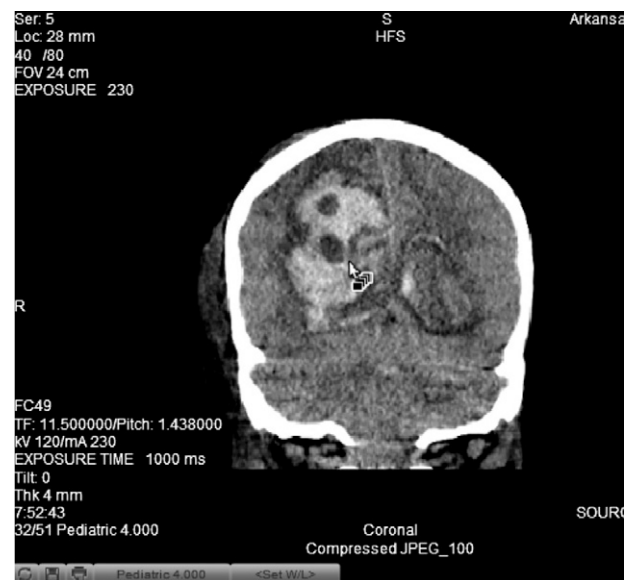


Figure 1. Stat head CT was performed, which showed large right parenchymal hematoma (5 cm) with intraventricular decompression and evolving acute hydrocephalus, effacement of sulcal spaces, sylvian fissure, basal cisterns, and crowding of posterior fossa structures with 3 cm leftward midline shift.

prior to ECMO cannulation finally grew $>100,000$ colony-forming units/mL of *Legionella pneumophila*, in addition to a positive urine antigen for serogroup-1 *Legionella pneumophila*.

COMMENT

Legionella is a gram-negative bacillus responsible for community- and hospital-acquired infection, although generally a rare cause of pneumonia in immunocompetent patients. This organism is generally acquired through inhalation of aerosolized water systems. The clinical course of *Legionella* pneumonia in children is not specific, with presentation ranging from mild symptoms to fulminant multi-organ dysfunction. Risk factors for severe Legionnaires' disease include malignancy, immunosuppression, and underlying lung disease. When clinically suspected, the diagnosis should be confirmed through deoxyribonucleic acid polymerase chain reaction from pleural fluid, culture of respiratory tract secretions, or urine antigen testing (1). Intravenous azithromycin is the antimicrobial treatment of choice.

While multiple case reports in immunocompetent adults describe successful use of ECMO for Legionnaires' disease complicated by ARDS (2), we found no prior cases describing the use of ECMO in immunosuppressed pediatric patients with this infection. In considering whether or not to offer extracorporeal support due to our patient's underlying malignancy, we worked closely with her primary oncologist who reported that the patient was entering maintenance phase of chemotherapy and had a good chance for oncologic cure.

Our patient's case was particularly challenging, and for several days V-V ECMO support was discussed, but postponed due to her profound thrombocytopenia and risk of significant bleeding with systemic anticoagulation required for ECMO support. Selection criteria for ECMO cannulation has fluctuated and expanded over time as knowledge and experience has grown. In considering the recent Pediatric ECMO Outcomes Registry (PEDECOR) experience, 18 patients with oncologic disease and/or HSCT supported with ECMO did not have significant difference in outcomes compared with matched ECMO controls. Survival to hospital discharge was also better than previously published at 61.1%. Patients with oncologic disease or HSCT supported with ECMO had lower mean platelet volumes, required greater number of platelet transfusions during ECMO, with new neurological disorders (defined as ischemic stroke, intracranial hemorrhage, seizure, or other) reported in 5 of 11 (45.5%) of survivors (6).

While our institution traditionally uses femoral cannulation in this age and size of patient, cervical cannulation for V-A ECMO using a Gore-Tex[®] carotid artery graft was placed at the discretion of the cannulating surgeon. This is one of a small number of ECMO cannulations performed at our institution using this method of cannulation. Data on outcomes and complications from this series of patients are currently being reviewed.

Multiple novel techniques have emerged, including subclavian and axillary artery cannulation for V-A ECMO support using a graft anastomosed in an end-to-side fashion (see Figure 2) to avoid complications associated with traditional cannulation techniques and to aid in early mobility of ECMO patients (7). In a single center experience of 81 adult patients cannulated with a

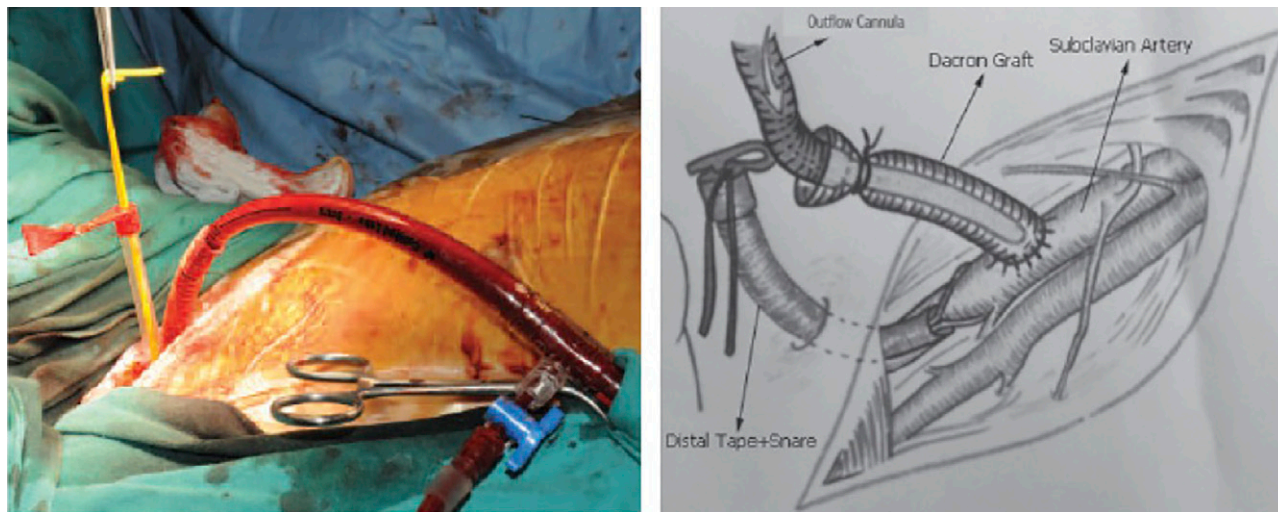


Figure 2. (left) Outflow graft and arterial cannula on subclavian artery and (right) schematic diagram of subclavian artery cannulation as an outflow of extracorporeal membrane oxygenation circuit. Used with permission from Kervan U, Kocabayoglu S, Sert DE, et al. *Exp Clin Transplant*. 2017;15:658–63.

graft anastomosed to the axillary artery, hyperperfusion syndrome to the ipsilateral upper extremity was the most common complication ($n = 20$) (8). A retrospective analysis of data from the ELSO registry found pediatric patients ≤ 18 years of age had increased odds of neurologic injury with carotid artery cannulation for V-A ECMO (9).

In reflecting on our patient with complications of streaming and hyperemia to the head, neck, and right arm following the use of a carotid artery graft, along with subsequent catastrophic neurologic sequelae after intracranial hemorrhage, one must consider the risk of placing such a graft with the potential increased risk of neurologic complications with preferential high blood flow rates directed toward the unprotected cerebral arterial circulation.

The clinical demise of this patient can be attributed to her severe immunosuppression due to her underlying malignancy and chemotherapy, worsened by disseminated *Legionella* leading to septic shock and ARDS necessitating V-A ECMO support. Her course was complicated by devastating cerebral hemorrhage from preferential flow and hyper-perfusion to the head and neck. Individualized ECMO care of immunosuppressed patients requires the expertise of a multidisciplinary critical care team as well as appropriate management of expectations in such a high-risk population, including those patients with Legionnaires' disease.

REFERENCES

1. Herwaldt LA. Legionella: A reemerging pathogen. *Curr Opin Infect Dis.* 2018;31:325–33.
2. Noah MA, Ramachandra G, Hickey MM, et al. Extracorporeal membrane oxygenation and severe acute respiratory distress secondary to Legionella: 10 year experience. *ASAIO J.* 2013;59:328–30.
3. Kang HS, Rhee CK, Lee HY, et al. Clinical outcomes of extracorporeal membrane oxygenation support in patients with hematologic malignancies. *Korean J Intern Med (Korean Assoc Intern Med).* 2015;30:478–88.
4. Gupta M, Shanley TP, Moler FW. Extracorporeal life support for severe respiratory failure in children with immune compromised conditions. *Pediatr Crit Care Med.* 2008;9:380–5.
5. Gow KW, Wulkan ML, Heiss KF, et al. Extracorporeal membrane oxygenation for support of children after hematopoietic stem cell transplantation: The Extracorporeal Life Support Organization experience. *J Pediatr Surg.* 2006;41:662–7.
6. Stepan DA, Coleman RD, Viamonte HK, et al. Outcomes of pediatric patients with oncologic disease or following hematopoietic stem cell transplant supported on extracorporeal membrane oxygenation: The PEDECOR experience. For the Pediatric ECMO (PediECMO) subgroup for the Pediatric Acute Lung Injury and Sepsis Investigators (PALISI) Network and the Extracorporeal Life Support Organization (ELSO). *Pediatr Blood Cancer.* 2020;67:1–8.
7. Kervan U, Kocabeyoglu S, Sert DE, et al. A novel technique of subclavian artery cannulation for venoarterial extracorporeal membrane oxygenation. *Exp Clin Transplant.* 2017;15:658–63.
8. Chamogeorgakis T, Lima B, Shafii A, et al. Outcomes of axillary artery side graft cannulation for extracorporeal membrane oxygenation. *J Thorac Cardiovasc Surg.* 2013;145:1088–92.
9. Teele SA, Salvin JW, Barrett CS, et al. The association of carotid artery cannulation and neurologic injury in pediatric patients supported with venoarterial extracorporeal membrane oxygenation. *Pediatr Crit Care Med.* 2014;15:355–61.